

Management of Ingested Magnets in Children

*Sunny Z. Hussain, †Athos Bousvaros, ‡Mark Gilger, §Petar Mamula, ||Sandeep Gupta, ¶Robert Kramer, and #R. Adam Noel

ABSTRACT

We describe a comprehensive algorithm for the management of ingested rare-earth magnets in children. These newer and smaller neodymium magnets sold as adult toys are much stronger than the traditional magnets, and can attract each other with formidable forces. If >1 magnet is swallowed at the same time, or a magnet is co-ingested with another metallic object, the loops of intestine can be squeezed between them resulting in bowel damage including perforations. An algorithm that uses the number of magnets ingested, location of magnets, and the timing of ingestion before intervention helps to delineate the roles of the pediatric gastroenterologists and surgeons in the management of these cases.

Key Words: bowel perforation, children, neodymium, rare-earth magnets

(*JPGN* 2012;55: 239–242)

Ingested neodymium magnets are a serious health hazard for children, with an extremely high risk of intestinal obstruction and perforation as loops of bowel may be trapped between multiple magnets. Neodymium or rare-earth magnets are not our grandfather's magnets. Composed of iron, boron, and neodymium, they are at least 5 to 10 times more powerful than traditional magnets. Invented by General Motors and Sumitomo Special Metals in 1982, these special magnets are used in many toys, modern household products including cordless tools, hard drives, magnetic resonance imaging, and hybrid electric engines.

The earliest report of bowel perforation with the ingestion of a traditional magnet was from Japan in 1995 (1). In 2002, McCormick et al (2) at Sheffield Children's Hospital reported 24 cases of injury from $7 \times 4 \times 1$ mm neodymium magnets. In the present report, nasal, aural, penile, and gastrointestinal tract injuries were noted in children of age 7 to 15 years. In 2005, an article from The Cleveland Clinic Foundation warned against the serious implications of multiple magnet ingestion in pediatric patients, including development of fistulae (eg, gastroenteric, enteroenteric), obstruction, and perforation (3). From 2003 to 2006, 20 cases of magnet ingestion and injury in children ages from 10 months to 11 years were reported

in *Morbidity & Mortality Weekly Report* published by the Centers for Disease Control and Prevention; 75% of those cases had bowel perforations, 20% contracted peritonitis and their mean hospital stay was 8.7 days (4). The magnets ingested during this time period originated from Mattel and other children construction games, and were usually larger disc magnets. In 2006, the US Consumer Product Safety Commission (CPSC) raised the recommended age for magnetic children's toys from 3 years to 6 years to ensure children's safety (5,6).

Increasing reports of swallowing rare-earth neodymium magnets began to surface in the late 2000s. Initially starting as case reports, the numbers increased alarmingly. Many of the reported ingestions since 2008 involve small neodymium magnets sold as part of a cube of magnets marketed as desk toys and stress relievers for adults. The CPSC has received reports of toddlers finding loose magnets left within their reach. Adolescents and teenagers are now using these high-powered magnets to mimic body piercings by placing ≥ 2 on their ear lobes, tongue, or nose, which has resulted in magnets being unintentionally inhaled and swallowed.

In 2007, the CPSC issued the first warning, noting the possibility of high-powered magnets detaching from children's toys causing injury and even death if swallowed (5,6). At that time, the CPSC was aware of the death of a 20-month-old child after swallowing such magnets, as well as 33 other cases of magnet ingestion of which at least 18 required emergency surgery for removal (5–7). By 2008, the CPSC had documented >200 reports, many of which required emergency surgery to remove the magnets. Between 2005 and 2008, the US patent rights for neodymium expired and several manufacturers began mass production of these new toys. In 2008, the first magnet ball cube toy, the NeoCube, was developed followed by the buckyball in 2009. These adult desk toys became extremely popular and increased the exposure to neodymium magnets to children. Each unit of the neodymium magnet has approximately 125 to >1000 magnetic balls (Fig. 1), and can be purchased on the Internet and in other retail outlets. The CPSC in 2009 issued a ban on the sale of rare-earth magnets to children

Received June 22, 2012; accepted July 6, 2012.

From *WK Pediatric Gastroenterology & Research, Shreveport, LA, †Children's Hospital, Boston, MA, ‡Texas Children's Hospital, Houston, TX, §Children's Hospital of Philadelphia, Philadelphia, PA, ||Riley Hospital for Children, Indianapolis, IN, ¶The Children's Hospital, Aurora, CO, and #Louisiana State University Health Science Center, Children's Hospital, New Orleans, LA.

Address correspondence and reprint requests to R. Adam Noel, MD, Department of Pediatrics, Section of Pediatric Gastroenterology, Louisiana State University Health Science Center, Children's Hospital of New Orleans, 200 Henry Clay Ave, Suite 2312, New Orleans, LA 70118 (e-mail: rnoell@lsuhsc.edu).

The authors report no conflicts of interest.

Copyright © 2012 by European Society for Pediatric Gastroenterology, Hepatology, and Nutrition and North American Society for Pediatric Gastroenterology, Hepatology, and Nutrition

DOI: 10.1097/MPG.0b013e3182687be0




FIGURE 1. High-powered ball bearing neodymium magnets in adult toys sold on the Internet as "New Magnetic Magnet Balls Beads Sphere Puzzle Cube." (From www.cps.gov, November 10, 2011, press release.)

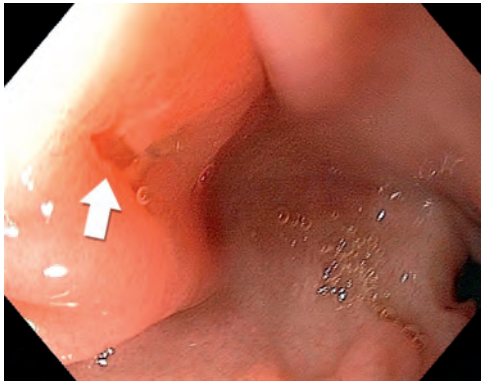


FIGURE 2. Deep gastric ulceration caused by opposition of 2 magnets in a 3-year-old child who swallowed 39 small neodymium magnets, despite removal from the stomach within 8 hours of ingestion.

younger than 14 years (7). One manufacturer failed to comply and a recall was ordered by the CPSC on 175,000 packages of buckyballs high-powered magnets sets labeled “Ages 13+” in May 2010 (8). Within months, however, the manufacturers had relabeled some of these products as “Not for Children” or “For Adults Only,” and these products continue to be widely available.

The attractive force of these neodymium magnets is formidable. After swallowing >1 magnet or a magnet with another

piece of metal, the attractive force allows the objects in the intestine to find each other despite being in different regions of the bowel (9–11). The magnets can therefore cause 2 pieces of bowel to stick together with great strength and do not separate. The resulting ischemia and pressure injuries can cause bowel perforation, volvulus, fistula, and severe infection that may result in serious, lifelong, and costly consequences, including intestinal resection (12,13). Even if these magnets are quickly removed from the gastric lumen with prompt endoscopy, our experience demonstrates that ulceration and indentations of the mucosa may occur in <8 hours (Fig. 2).

Surprisingly, the magnitude and the seriousness of this “magnet problem” remained under the radar among the vast majority of pediatricians, pediatric gastroenterologists, pediatric surgeons, as well as the emergency department physicians in the United States until a recent email communication in the Pediatric Gastroenterology LISTSERV brought this issue into the spotlight. An informal survey of North American Society of Pediatric Gastroenterology, Hepatology, and Nutrition (NASPGHAN) members in Spring 2012 identified significant morbidity in >80 magnet ingestions, which resulted in 39 endoscopies, 26 surgeries, 26 bowel perforations, and 3 bowel resections.

ALGORITHM FOR MANAGEMENT

The 2012 informal survey of NASPGHAN members indicated a more prevalent problem with significant morbidity than initially appreciated, and that magnet ingestions are a clear and

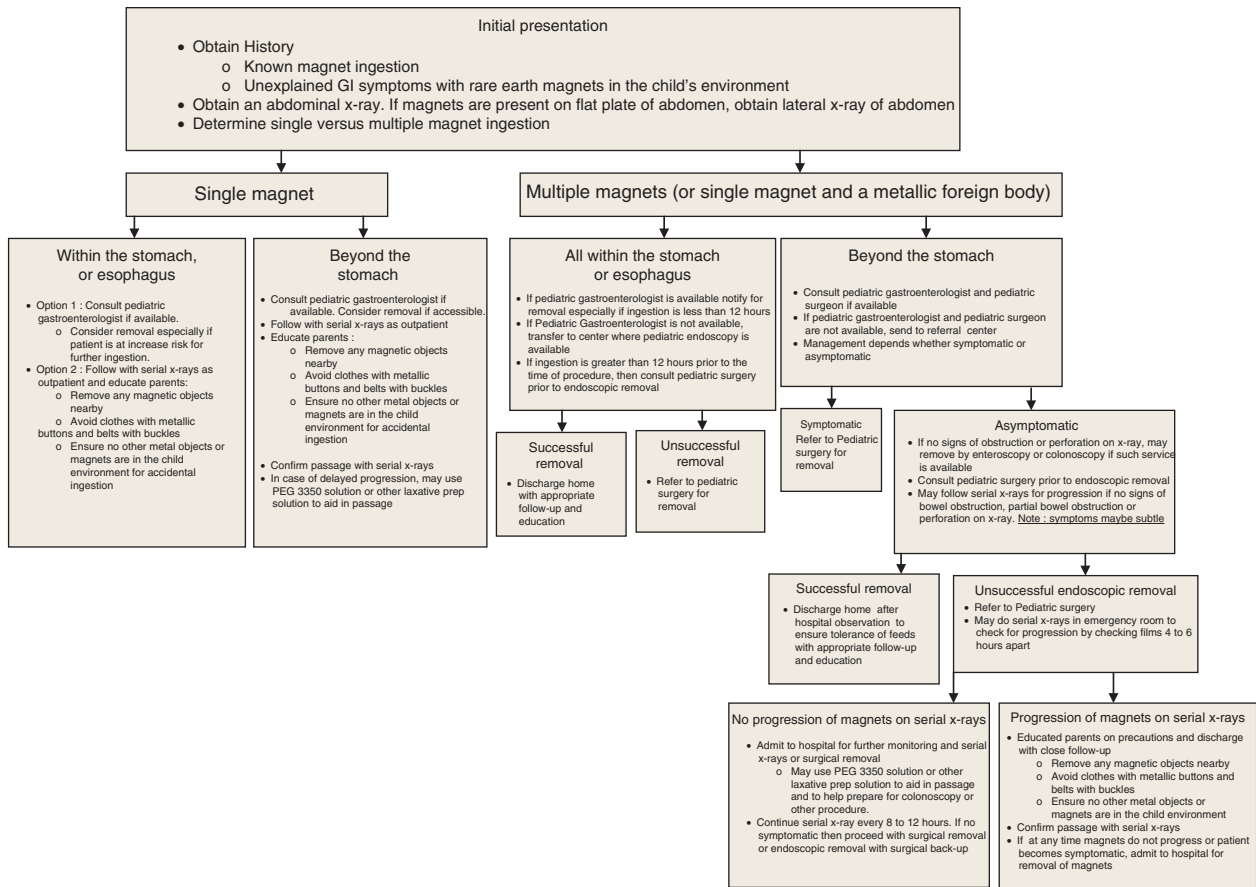


FIGURE 3. Rare-earth magnet ingestion algorithm. GI = gastrointestinal.

present danger for children. Existing algorithms (14,15) appeared inadequate especially when defining the role of the pediatric gastroenterologist and endoscopy in rare-earth magnet ingestions. In May 2012, a task force consisting of NASPGHAN members (including members of the endoscopy committee, professional education committee, and patient education committee) agreed that there is need for additional education of physicians and patients on this potential health hazard. The algorithm below was developed with the inputs of the senior leadership of NASPGHAN along with comments from members of the endoscopy committee (Fig. 3).

This algorithm is detailed and self-explanatory. The initial step in the evaluation is to ascertain the diagnosis of magnet ingestion in a child presenting with gastrointestinal symptoms such as vomiting and abdominal pain, in an environment wherein small magnets are present. The children may complain of gagging, choking, or drooling at the time of the initial ingestion, but with these small magnets they are not likely to have any initial symptoms unless a large number of magnets have been ingested. Most of the children remain asymptomatic thereafter, unless there is a complication. Cases that present with abdominal pain, discomfort or cramps, vomiting, or abdominal distension are of concern as these may suggest an impending intestinal obstruction. Other patients may have minimal complaints that may mimic a viral gastroenteritis.

Once magnet ingestion is confirmed on the x-ray, the next step is to determine whether only a single magnet was ingested versus multiple magnet ingestion, or a single magnet with a coingestion of another metallic object. To determine whether only a single magnet was ingested, multiple radiologic views are necessary because it is possible for magnets to stick together, overlap on a single view, and be misdiagnosed as a single magnet. A single swallowed magnet can be managed conservatively with appropriate education of the parents and child (Fig. 4). Butterworth and Feltis (16) have pointed out that misdiagnosis of multiple magnets as solitary magnet ingestion can lead to a delay in diagnosis and severe subsequent complications, which can be prevented by timely intervention. Our algorithm makes specific recommendations to rule out multiple magnet ingestion and allows for the early endoscopic intervention in some cases of single magnet ingestions.

Multiple magnet ingestions or coingestion of a single magnet with another metal object should be treated with increased urgency because of high risk of perforation(s) (Fig. 5). The time interval between ingestion and presentation, along with the location of the

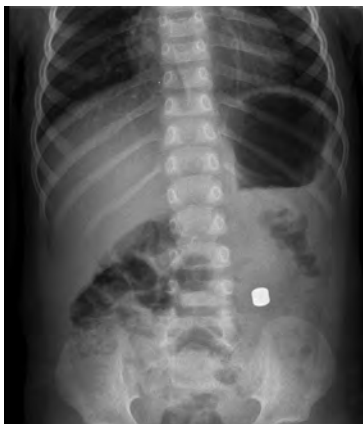

FIGURE 4. A single disc-shaped magnet swallowed by a 3-year-old girl was managed conservatively and the magnet passed without any serious complications.

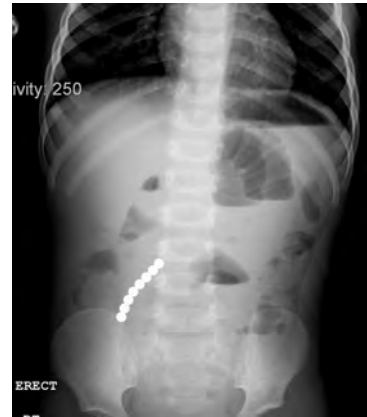

FIGURE 5. Multiple magnets swallowed by a 22-month-old child resulted in multiple intestinal perforations and eventually short gut syndrome. This child is now a candidate for small intestinal transplantation.

magnets, determines the next step in the algorithm. Both time since ingestion and location of magnets have not been incorporated into earlier magnet ingestion algorithms (14,15). Children with delayed presentation, >12 hours after ingestion, seemed to sustain more complications such as perforations and fistulae. Significant pressure injury (Fig. 2) has been noted as early as 8 hours in the informal NASPGHAN survey, although perforations or fistulae have been reported in cases wherein the magnets were removed before 12 hours from ingestion. Overall, it is prudent to remove the magnet(s) endoscopically if possible, especially if multiple magnets are in a location that is accessible by endoscopy.

One area of debate is whether the use of laxative agents to expedite the progression of a magnetic object through the intestine is indicated. Although no published data support this approach, many clinicians use it in practice. In addition to potentially speeding the passage of magnets through the intestine, polyethylene glycol colonoscopy preparation solutions may have the advantage of preparing a child for a colonoscopy if the magnets become lodged in the distal bowel.

Endoscopic removal should be performed under general anesthesia with a protected airway. A net retrieval device (Roth net) is often used, but it may not be the best choice while removing multiple magnets (usually ≥ 10) as the magnets can get stuck on both sides of the net, making it extremely difficult to pull the net through the lower esophageal junction. Snares, basket retrieval devices, or multiprong forceps can be used if the location and number of magnets do not allow the use of a net retrieval device. Hinged types of forceps (ie, alligator forceps) are probably not the best choice because the ball shape of the magnets tends to cause the magnets to be pushed out the sides or pushed forward away from the forceps during closure.

Pediatric surgeons should be involved early in complicated cases, especially those with multiple magnet ingestion located distal to the stomach or those who have had a significant period elapsed between magnet ingestion and medical intervention.

CONCLUSIONS

We recommend that the health care professionals involved in the care of children should be educated about the serious risks posed by magnetic toys. If magnet ingestion has occurred in a child,

this new NASPGHAN algorithm should aid in the evaluation and treatment of the affected pediatric patient.

REFERENCES

- Honzumi M, Shigemori C, Ito H, et al. An intestinal fistula in a 3-year-old child cause by ingestion of magnets: report of a case. *Surg Today* 1995;25:552–3.
- McCormick S, Brennan P, Yassa J, et al. Children and mini-magnets: an almost fatal attraction. *Emerg Med J* 2002;19:71–3.
- Kay M, Wyllie R. Pediatric foreign bodies and their management. *Curr Gastroenterol Rep* 2005;7:212–8.
- Centers for Disease Control and Prevention. Gastrointestinal injuries from magnet ingestion in children—United States, 2003–2006. *MMWR Morb Mortal Wkly Rep* 2006;55:1296–300.
- Child's Death Prompts Replacement Program of Magnetic Building Sets*. Release 06-127. <http://www.cpsc.gov/cpsc/pub/prereel/prhtml06/06127.html>. Published March 31, 2006. Accessed June 21, 2012.
- Serious Injuries Prompt Recall of Mattel's Polly Pocket Magnetic Play Sets*. Release 07-039. <http://www.cpsc.gov/cpsc/pub/prereel/prhtml07/07039.html>. Published November 21, 2006. Accessed June 21, 2012.
- CPSC Warns High-Powered Magnets and Children Make a Deadly Mix*. Release #12-037. <http://www.cpsc.gov/cpsc/pub/prereel/prhtml12/12037.html>. Published November 2011. Accessed June 21, 2012.
- Buckyballs High Powered Magnets Sets Recalled by Maxfield and Ober-ton Due to Violation of Federal Toy Standard*. Release #10-251. <http://www.cpsc.gov/cpsc/pub/prereel/prhtml10/10251.html>. Published May 27, 2010. Accessed June 21, 2012.
- Oestreich AE. Danger of multiple magnets beyond the stomach in children. *J Natl Med Assoc* 2006;98:277–9.
- Alzahem AM, Soundappan SS, Jefferies H, et al. Ingested magnets and gastrointestinal complications. *J Pediatr Child Health* 2007;43:497–8.
- Wong HHL, Phillips BA. Opposites attract: a case on magnet ingestion. *CJEM* 2009;11:493–7.
- Tay ET, Weinberg G, Levin TL. Ingested magnets: the force within. *Pediatr Emerg Care* 2004;20:466–7.
- Hernandez AE, Gutierrez SRC, Barrios JE, et al. Intestinal perforation caused by magnetic toys. *J Pediatr Surg* 2007;42:E13–6.
- Vijaysadan V, Perez M, Kuo D. Revisiting swallowed troubles: complications caused by two magnets—a case report, review and proposed revision to the algorithm for the management of foreign body ingestion. *J Am Board Fam Med* 2006;19:511–5.
- Wong HH, Phillips BA. Opposites attract: a case of magnet ingestion. *CJEM* 2009;11:493–5.
- Butterworth J, Feltis B. Toy magnet ingestion in children: revising the algorithm. *J Pediatr Surg* 2007;42:e3–5.