

## CHAIR

### **Rohit Kohli, MBBS, MS**

Associate Professor of Pediatrics  
Medical Director, Complex Surgery and  
Transplant Inpatient Unit  
Co-Director, Steatohepatitis Center  
Cincinnati Children's Hospital Medical Center  
Cincinnati, OH

## FACULTY

### **Ruba K. Azzam, MD**

Associate Professor of Pediatrics  
Medical Director, Pediatric Liver Transplant Program  
University of Chicago  
Comer Children's Hospital  
Chicago, IL

### **Regino P. Gonzalez-Peralta, MD**

Professor of Pediatrics  
Assistant Dean, Office of Diversity and Health Equity  
University of Florida College of Medicine  
Gainesville, FL

### **Maureen Jonas, MD**

Clinical Director, Hepatology  
Medical Director, Liver Transplant Program  
Boston Children's Hospital  
Professor of Pediatrics  
Harvard Medical School  
Boston, MA

## CME CONTENT REVIEWER

### **Henry Lin, MD**

Attending Physician  
The Children's Hospital of Philadelphia  
Philadelphia, PA

## MEDICAL WRITER

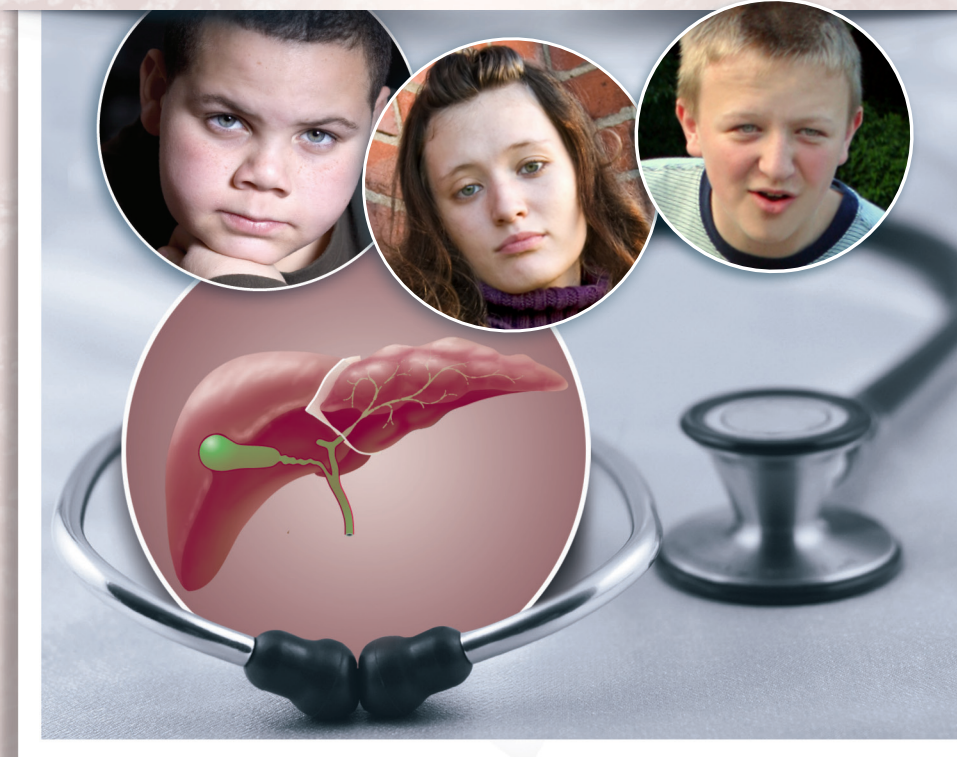### **Matt Kilby**

Science Writer



# MASQUERADERS OF NONALCOHOLIC FATTY LIVER DISEASE

## *A CME Case-Based Newsletter*



Jointly sponsored by NASPGHAN and The NASPGHAN  
Foundation for Children's Digestive Health and Nutrition.  
Release Date: June 1, 2014, Expiration Date: May 31, 2017

2.0 AMA PRA Category 1 CME Credits™

## INTRODUCTION

Nonalcoholic fatty liver disease (NAFLD) is the most common liver disease in the United States, affecting an estimated 10%–46% of the US population and somewhere between 3% and 25% of children. Obesity is the most common cause of NAFLD; however, 3%–10% of pediatric patients with NAFLD are nonobese. It is important to understand potential causes of NAFLD that are not obesity related to avoid misdiagnosis in pediatric patients. These include but are not limited to mitochondrial hepatopathies, kwashiorkor/anorexia nervosa, Wilson's disease, cholesteryl ester storage disease (CESD)/lysosomal acid lipase (LAL) deficiency, hepatitis C, uncontrolled type 1 diabetes, and mitochondrial disorders.

Physicians must recognize clues that fatty liver might not be the typical obesity-associated NAFLD. The real-life cases presented here illustrate these clinical clues and help providers decide which patients should have additional testing, as well as which tests should be considered. Once proper diagnoses are made, the cases also consider appropriate treatment approaches for patients with these “masqueraders of NAFLD.”

## TARGET AUDIENCE

This activity is designed for pediatricians, pediatric gastroenterologists and hepatologists, primary care physicians, physician assistants, nurse practitioners, and other health care professionals who treat patients at risk for NAFLD.

## LEARNING OBJECTIVES

Participants completing this activity should be better able to:

- Recognize disease types of NAFLD in nonobese pediatric patients, such as Wilson's disease, lysosomal acid lipase deficiency, and Alpers syndrome
- Describe the pathophysiology of NAFLD disease types in nonobese pediatric patients, including disease definitions and causes
- Describe recommended strategies for diagnosing different types of NAFLD in nonobese pediatric patients
- Describe appropriate and evidence-based treatments for NAFLD in nonobese pediatric patients

## PHYSICIANS

This activity has been planned and implemented in accordance with the Essential Areas and policies of the Accreditation Council for Continuing Medical Education (ACCME) through the joint sponsorship of the North American Society for Pediatric Gastroenterology, Hepatology and Nutrition (NASPGHAN) and The NASPGHAN Foundation for Children's Digestive Health and Nutrition. NASPGHAN is accredited by the ACCME to provide continuing medical education for physicians.

## AMA PRA STATEMENT

NASPGHAN designates this enduring activity for a maximum of 2.0 AMA PRA Category 1 Credits™. Physicians should claim only the credit commensurate with the extent of their participation in the activity.

## STATEMENT OF DISCLOSURE

All faculty/speakers, planners, abstract reviewers, moderators, authors, coauthors, and administrative staff participating in the continuing medical education programs sponsored by NASPGHAN are expected to disclose to the program audience any/all relevant financial relationships related to the content of their presentation(s). Accordingly, the NASPGHAN staff have reported no financial relationships with any commercial interests related to the content of this educational activity.

**Rohit Kohli, MBBS, MS** was on Synageva's speakers bureau and relationship has ended.

**Ruba K. Azzam, MD** has nothing to disclose.

**Regino P. Gonzalez-Peralta, MD** has received honoraria from Synageva.

**Maureen Jonas, MD** has nothing to disclose

**Henry Lin, MD** has nothing to disclose

**Matt Kilby** has nothing to disclose.

In accordance with ACCME Standards for Commercial Support of CME, NASPGHAN and The NASPGHAN Foundation for Children's Digestive Health and Nutrition implemented mechanisms to identify and resolve conflicts of interest for all individuals in a position to control content of this CME activity. To resolve

identified conflicts of interest, the educational content was peer-reviewed by a physician member of the NASPGHAN Review Committee who has nothing to disclose. The resulting certified activity was found to provide educational content that is current, evidence-based, and commercially balanced.

## DISCLOSURE OF UNLABELED OR INVESTIGATIONAL DRUGS

This educational activity may contain discussion of published and/or investigational uses of agents that are not indicated by the US Food and Drug Administration. The opinions expressed in the educational activity are those of the faculty. Please refer to the official prescribing information for each product for discussion of approved indications, contraindications, and warnings. Further, attendees/participants should appraise the information presented critically and are encouraged to consult appropriate resources for any product or device mentioned in this program.

## MEDIUM OR COMBINATION OF MEDIA USED

This activity will consist of a mailed or Web-based monograph and a posttest. This activity requires Adobe Acrobat to view a pdf of the monograph.

## HOW TO RECEIVE CME CREDIT:

To receive CME credit for reviewing this activity, participants must review the CME information (learning objectives, disclosures, etc.), review the entire activity, and complete the activity posttest and evaluation questions.

To complete the activity posttest and evaluation, please visit <http://www.gotomylist.com/esystems/quiz/quiz.cfm?QuizNum=106>

Certificates will be provided immediately after completion of both the posttest and evaluation. For any questions about receiving credit, please e-mail [Certificate@AmedoEmail.com](mailto:Certificate@AmedoEmail.com).

## PROVIDER CONTACT INFORMATION

Jointly sponsored by NASPGHAN and The NASPGHAN Foundation for Children's Digestive Health and Nutrition.

For questions, please contact:

**NASPGHAN**, PO Box 6, Flourtown, PA 19031

Phone: (215) 233-0808 • Fax: (215) 233-3918

## DISCLAIMER

The content and views presented in this educational activity are those of the authors and do not necessarily reflect those of NASPGHAN, The NASPGHAN Foundation for Children's Digestive Health and Nutrition, or Synageva. This material is prepared based upon a review of multiple sources of information, but it is not exhaustive of the subject matter. Therefore, health care professionals and other individuals should review and consider other publications and materials on the subject matter before relying solely upon the information contained within this educational activity.

## POLICY ON PRIVACY AND CONFIDENTIALITY

NASPGHAN and The NASPGHAN Foundation for Children's Digestive Health and Nutrition will make every effort to protect the privacy of every individual participant of this activity and will use information gathered only to maintain records as required by the American Medical Association (AMA) and ACCME.

This activity does not require readers to “register” to review the material, with the exception of physicians and other health care providers who desire to receive CME credit for this accredited activity. If an individual completes a CME for this accredited activity, we are required by the AMA and ACCME to collect personal information on the individual, such as their name, address, and phone number, that will allow us to issue a CME certificate to them and to keep this information on file for up to 6 years.

Personal information gathered will not be released to any other company or organization for any purpose. This information remains totally confidential.

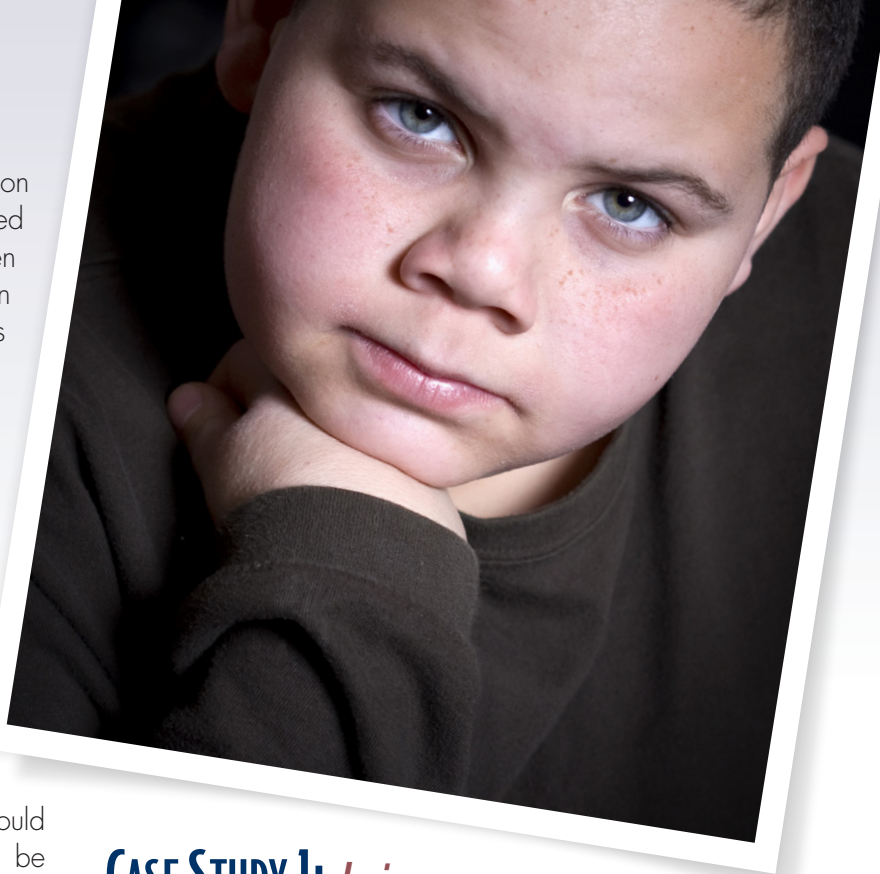
© Copyright 2014 NASPGHAN and The NASPGHAN Foundation for Children's Digestive Health and Nutrition.



## INTRODUCTION

Nonalcoholic fatty liver disease (NAFLD) is the most common liver disease in the United States, affecting an estimated 10%–46% of the US population<sup>1–3</sup> and somewhere between 3% and 25% of children.<sup>3–5</sup> Obesity is the most common cause of NAFLD; however, 3%–10% of pediatric patients with NAFLD are nonobese.<sup>6–9</sup> It is important to understand potential causes of NAFLD that are not obesity related to avoid misdiagnosis in pediatric patients. These include but are not limited to mitochondrial hepatopathies, kwashiorkor/anorexia nervosa, Wilson's disease, cholesteryl ester storage disease (CESD)/lysosomal acid lipase (LAL) deficiency, hepatitis C, uncontrolled type 1 diabetes, and mitochondrial disorders.

Physicians must recognize clues that fatty liver might not be the typical obesity-associated NAFLD. The real-life cases presented here illustrate these clinical clues and help providers decide which patients should have additional testing, as well as which tests should be considered. Once proper diagnoses are made, the cases also consider appropriate treatment approaches for patients with these “masqueraders of NAFLD.”



### CASE STUDY I: *Javier*

Javier is a 13-year-old Hispanic boy referred for evaluation of liver test abnormalities. He was diagnosed with hypothyroidism (and started on levothyroxine) approximately 1 year ago, when laboratory testing for fatigue showed elevated thyroid-stimulating hormone (TSH). At the time, he also had elevated aspartate aminotransferase (AST) and alanine aminotransferase (ALT) levels (greater than twice the upper limit of normal), which persisted on several subsequent determinations. Other than experiencing mild, vague, and intermittent right upper quadrant abdominal pain over the preceding 3 days, he is completely asymptomatic. There are no lung, liver, or neurological complaints. His mother has hypothyroidism; no relatives have liver, lung, neurological, or psychiatric disease.

The weight is 69 kg (>95%), the height is 162 cm (60%), and the body mass index (BMI) is 26 kg/m<sup>2</sup> (>95%). He has abdominal striae. Neither the liver nor spleen is enlarged, and there are no stigmata of chronic liver disease. Results of complete blood count (CBC), prothrombin time, TSH, and liver tests are normal except for elevated AST and ALT (132 and 120 IU/L, respectively). Liver-specific tests, including antinuclear, smooth muscle, and liver-kidney microsomal antibodies; hepatitis A and C serology; hepatitis B surface antigen; creatinine kinase; and alpha 1 antitrypsin level and Pi phenotype are normal; the ceruloplasmin concentration is low (8 mg/dL [normal > 20 mg/dL]); and there is borderline hepatomegaly on abdominal sonogram with increased echogenicity consistent with fatty infiltration of the liver.



# WILSON'S DISEASE

## Pathophysiology

Wilson's disease is an autosomal recessive disease that affects 3–30 in every 1 million individuals.<sup>10–12</sup> It is caused by mutation in the *ATP7B* gene, which encodes a metal-transporting adenosine triphosphatase that aids in the transmembrane transport of copper.<sup>10,13–16</sup> Alterations in *ATP7B* protein function leads to copper accumulation in the liver and results in injury as excess copper is released into the blood and deposited in various organs, including the brain, cornea, heart, kidneys, and pancreas.

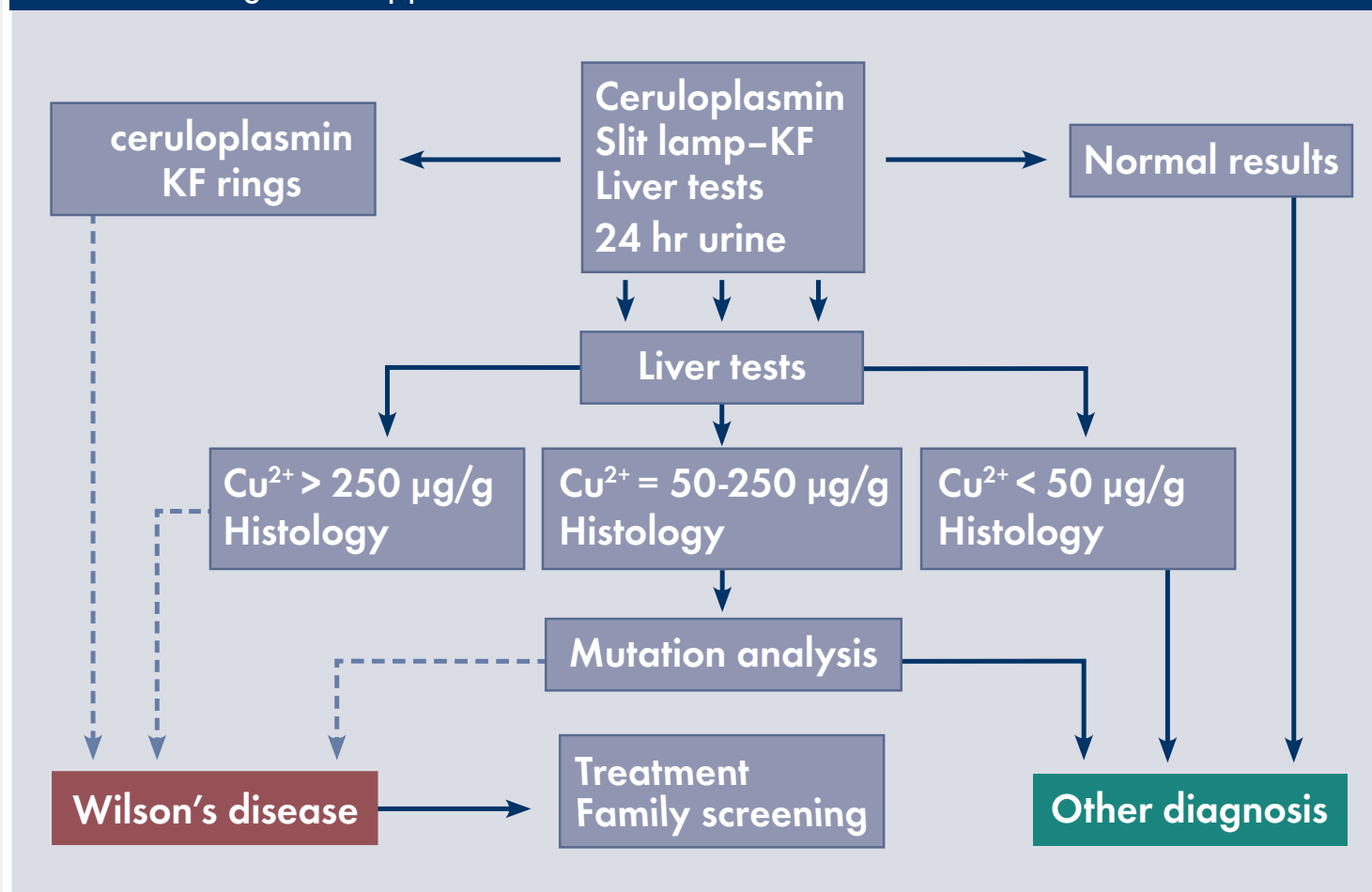
The original clinical description of Wilson's disease was in a group of patients between ages 5 and 40 years with necrotic damage in lenticular nuclei and liver cirrhosis.<sup>17</sup> Later descriptions included neurologic manifestations and Kayser-Fleischer (KF) rings—copper deposition in the cornea that appears as a ring of golden brownish pigment near the limbus.<sup>10,18</sup> An important biochemical feature of Wilson's disease is decreased serum ceruloplasmin concentration.<sup>10,19</sup>

In most cases, Wilson's disease presents clinically as either a liver, neurological, or psychiatric disorder.<sup>10,12</sup> In children, liver dysfunction is the most common initial presenting scenario, occurring in 50% of affected pediatric patients under age 18 years and 75% under age 10 years. Copper toxicity is rarely evident before ages 3–5 years, and manifestations include asymptomatic elevations of transaminases, acute or chronic hepatitis, cirrhosis, and acute liver failure. Neurological or psychiatric signs are the first indication of illness in 40%–45% of patients with Wilson's disease and have been recorded in children as young as age 6 years. Neurological symptoms include tremors, drooling, poor coordination, ataxia, writing difficulties, dementia, anxiety or depression, psychosis, and schizophrenia.

## Diagnosis

Patients with Wilson's disease may present with vague, mild, and varied symptoms that can make diagnosis challenging.<sup>10,20</sup> Because no single conclusive test exists to detect or exclude Wilson's disease, clinical findings and biochemical testing need to be incorporated to establish a firm diagnosis (**Figure 1**).

**FIGURE 1.** Diagnostic Approach to Wilson's Disease<sup>10,21</sup>







with  $>250 \mu\text{g/g}$  dry liver tissue weight providing the strongest biochemical evidence for Wilson's disease and normal values ( $<40\text{--}50 \mu\text{g/g}$  dry liver tissue) excluding this diagnosis.<sup>10</sup> Typical histologic abnormalities seen in Wilson's disease include micro- and macrovesicular steatosis, glycogenated nuclei in hepatocytes, and focal hepatocellular necrosis.<sup>10,28,29</sup> With confirmed diagnosis of Wilson's disease, any first-degree relatives of the patient should also be screened by either biochemical or genetic testing.<sup>10</sup> Assessment should include history and physical examination as well as the diagnosis recommendations outlined above.

## Treatment

Chelating agents are typically recommended as the initial treatment in patients with active or symptomatic Wilson's disease.<sup>10</sup> Penicillamine is used most often, but trientine is becoming increasingly popular as the primary therapy. While using either chelating agent, care should be taken to slowly increase the dose to reach the initial target (**Table 1**). Combination therapy of zinc used with a chelating agent (separated temporally) could theoretically block copper uptake and eliminate excess copper; however, this has only been studied

A diagnosis of Wilson's disease should be considered in any child over the age of 3 years who presents with unexplained liver test abnormalities.<sup>10,22</sup> Patients with suspected Wilson's disease should undergo careful slit lamp examination by an experienced examiner to assess for the presence of KF rings, although the absence of these rings does not exclude diagnosis, even in patients with predominantly neurological symptoms.<sup>10,20,23</sup> Routine measurement of serum ceruloplasmin is also recommended during evaluation of unexplained hepatic, neurologic, or psychiatric symptoms, with an extreme low ( $<50 \text{ mg/L}$  or  $5 \text{ mg/dL}$ ) indicative of Wilson's disease.<sup>10</sup> However, normal ceruloplasmin levels do not necessarily exclude Wilson's disease.

In patients without both KF rings and normal serum ceruloplasmin concentration, additional testing is necessary to assess for Wilson's disease. Basal 24-hour urinary excretion of copper aids in the diagnosis of the disease. Copper levels in an appropriately collected urine sample  $>100 \mu\text{g}/24 \text{ hours}$  in symptomatic patients indicate Wilson's disease, whereas those  $>40 \mu\text{g}/24 \text{ hours}$  require further investigation.<sup>10,24-26</sup> Urine copper levels  $>1600 \mu\text{g}/24 \text{ hours}$  with the administration of D-penicillamine (500 mg at the start of the collection and 12 hours into it) may provide additional evidence for the presence of Wilson's disease.<sup>10,27</sup>

In addition to serological and urinary testing, hepatic copper content and histology provide important information,



in preliminary reports and efficacy over treatment with a chelator alone has not yet been determined. Additionally, ongoing studies are investigating the use of tetrathiomolybdate as an alternative chelator for initial treatment in patients with neurologic symptoms. Vitamin E can also be considered for use as an antioxidant. These treatments are further detailed in **Table 1**.

Once symptoms or biochemical abnormalities stabilize (typically 2–6 months after therapy initiation), maintenance doses of chelators or zinc can be used, and treatment is lifelong. Zinc monotherapy can be considered in presymptomatic patients who are identified by family screening. Poor treatment

adherence can result in recurrent symptoms and liver failure, which requires liver transplantation. Therefore, it is important for the physician to monitor patients for compliance as well as potential adverse effects of treatment.

### CASE STUDY I: *Follow-Up*

Javier’s initial low ceruloplasmin concentration suggests Wilson’s disease. He has no KF rings by slit lamp examination. Results of a 24-hour urine copper (140 µg) and hepatic copper content (846 µg/g dry liver tissue) are markedly elevated and confirm diagnosis of Wilson’s disease. Javier is started on trientine monotherapy.

**TABLE 1.** Treatment Approach for Wilson’s Disease<sup>10,30-34</sup>

DRUG	ACTION	DOSE	ADVERSE EFFECTS
Penicillamine	Chelator	Initial 20 mg/kg/day (1.5–2 g/day) given in 2 or 3 divided doses Maintenance 10–20 mg/kg/day (0.75–1.5 g/day) given in 2 or 3 divided doses	Generalized pruritus Early and late rashes Anorexia Gastronintestinal pain Nausea Vomiting Diarrhea Blunting, diminution, or total loss of taste perception Leukopenia Thrombocytopenia Proteinuria Hematuria Tinnitus Optic neuritis Dystonia
Trientine	Chelator	Initial 20 mg/kg/day (1.5–2 g/day) given in 2 or 3 divided doses Maintenance 10–20 mg/kg/day (0.75–1.5 g/day) given in 2 or 3 divided doses	Iron deficiency Systemic lupus erythematosus Dystonia Muscular spasm Myasthenia gravis
Zinc	Blocks absorption	75–150 mg/day (in 3 divided doses)	Gastric irritation
Tetrathiomolybdate	Chelator Blocks absorption	150–200 mg/day	Anemia Neutropenia Leukopenia Transaminase elevations
Vitamin E	Antioxidant	400–1200 IU/day	N/A





# LYSOSOMAL ACID LIPASE DEFICIENCY

## Pathophysiology

LAL deficiency presents clinically in 2 phenotypes: the infantile-onset Wolman disease (WD) and later-onset CESD. WD occurs in 1 in 500,000 infants, usually between the ages of 2–4 months.<sup>35-37</sup> In these infants, LAL activity is absent or decreased to <1% of normal values, causing massive lysosomal accumulation of cholesteryl esters (CEs) and TGs, predominantly in the liver, spleen, adrenals, bone marrow, lymph nodes, and in macrophages throughout the body, particularly in the intestinal villi.<sup>36,38-41</sup> Infants present with vomiting, diarrhea, massive hepatosplenomegaly (HSM), severe liver disease, adrenal calcifications in 50% of cases, feeding difficulties, malabsorption, malnutrition, and growth retardation. It often leads to patient death by age 12 months.<sup>35,36</sup>

CESD is an autosomal recessive lysosomal storage disorder that occurs in 1 in 40,000 people and results from mutation in the LAL gene (*LIPA*) that cause marked reduction in LAL activity.<sup>42-44</sup> As a result, CEs accumulate throughout the body. The degree of accumulation usually correlates with the tissues' relative participation in receptor-mediated endocytosis and lysosomal degradation of lipoproteins.<sup>35,42,43</sup> Organs that are predominantly affected are the liver, spleen, adrenals, bone marrow, lymph nodes, and intestinal villi. Defective LAL activity reduces hydrolysis of CEs and TGs and causes massive sequestration, particularly in Kupffer cell and hepatocyte lysosomes as well as other cells of the macrophage/monocyte system. Lack of free cholesterol due to lysosomal trapping of CEs leads to reduced feedback inhibition of 3-hydroxy-3-methylglutaryl-coenzyme A reductase, which in turn leads to increased synthesis of cholesterol and upregulation of apolipoprotein B synthesis and LDL receptors on cell membranes. The dysregulated expression of the LDL cholesterol-dependent adenosine triphosphate-binding cassette transporter 1 gene contributes to HDL cholesterol reduction.

CESD may present in infancy, childhood, or adulthood, depending on the residual in vitro LAL activity (1%–12% of normal) and is underrecognized, especially in patients of European ancestry and Persian Jews. It is commonly misdiagnosed as NAFLD, nonalcoholic steatohepatitis, or cryptogenic liver disease.<sup>42,44</sup> It presents as hepatomegaly and liver dysfunction and/or type IIb dyslipoproteinemia (increase in total cholesterol [Tchol], LDL, and TG and decrease in HDL).<sup>42,43</sup> Liver tissue in patients with CESD is grossly bright yellow-orange in color, and histology reveals massive lysosomal accumulation of CEs and TGs in hepatocytes,

## CASE STUDY 2: Alina

Alina is a 13-year-old girl of Polish American descent who is referred by her primary physician for abnormal liver enzymes, hepatomegaly, and fatty liver observed by ultrasound. She has been previously healthy but, over the past 6 months, has constantly felt tired. Thyroid function test results are normal. She does not have symptoms of abdominal pain, fever, jaundice, itching, bleeding, cold intolerance, or irregular defecation. She has not lost or gained weight but is smaller in size than her peers. She does not currently take any medicine or herbal therapies and eats a typical American diet, though she does not exercise much on a regular basis. On physical examination, her BMI is 22 kg/m<sup>2</sup> and she has hepatomegaly but no signs of chronic liver disease. Her most recent laboratory workup includes an AST level of 56 IU/L (increased from 55 IU/L 3 months earlier), ALT level of 67 IU/L (decreased from 77 IU/L), high-density lipoprotein (HDL) of 35 mg/dL (decreased from 40 mg/dL), low-density lipoprotein (LDL) of 292 mg/dL (increased from 262 mg/dL), and triglyceride (TG) of 122 mg/dL (decreased from 135 mg/dL). Computed tomography of her abdomen reveals diffuse low attenuation of liver parenchyma compatible with fatty infiltration, and the maximum craniocaudal length of her liver is 20 cm.

Kupffer cells, and macrophages, giving the microvesicular steatosis picture. Progressive lipid deposition leads to fibrosis, micronodular cirrhosis, and ultimately liver failure.

### Diagnosis

The rarity of LAL deficiency makes it easy to miss or misdiagnose, but various diagnostic and screening tools are available for appropriate diagnosis. Typical diagnosis is based on laboratory evaluation demonstrating transaminitis and/or dyslipidemia.<sup>44</sup> Hepatomegaly or HSM is a common finding on physical examination. Fatty infiltration is seen on radiological or histological evaluation. Symptoms can be nonspecific and include diarrhea, abdominal pain, malabsorption, or those related to cholestasis or cardiovascular disease or early stroke. Clinical suspicion for CESD is confirmed via genetic testing. Over 40 loss-of-function *LIPA* mutations have been identified in patients with LAL deficiency,<sup>45-54</sup> with E8SJM being the most common mutation. Traditional enzyme assays for LAL activity in peripheral leukocytes, cultured fibroblasts, or liver tissue have been used. More recently, dried blood spot (DBS) analysis for LAL activity has become available as a simple and more-specific assay for LAL enzyme activity, with a good separation of the activities of normal controls and CESD homozygotes and heterozygotes.<sup>55</sup> It uses 4-methylumbelliferyl-palmitate as the enzyme substrate and the LAL-specific inhibitor, Lalistat 2.

Available laboratories in the United States for DBS and *LIPA* sequencing analysis are provided in **Table 2**.

### Treatment

There is currently no approved treatment for LAL deficiency, although liver transplantation has been effective in preventing

liver failure and subsequent death.<sup>57,58</sup> Extrahepatic organ involvement, even in transplanted patients, can result in significant disease burden and premature death.

Sebelipase alfa is currently under investigation as a potential enzyme-replacement therapy for patients with LAL deficiency. In preclinical trials, this recombinant human LAL enzyme effectively reversed lipid storage in the liver, decreased lipid concentration in key tissues, normalized liver function, and corrected clinically relevant abnormalities, including liver size and growth failure.<sup>43,59-61</sup> In the first human study, 9 patients received 4 weekly infusions of sebelipase alfa at doses of 0.35, 1, or 3 mg/kg<sup>-1</sup>.<sup>43</sup> Patients who completed the first treatment arm were given an additional round of treatment before switching to long-term, every-other-week infusions of 1 or 3 mg/kg. In 7 of the 9 patients (78%), mean ALT and AST decreased by 52% and 36%, respectively, at week 12 compared to baseline. At week 12, the same 7 patients also had mean decreases in Tchol (22%), LDL cholesterol (27%), and TGs (28%) and increases in HDL cholesterol (15%). Further clinical trials for sebelipase alfa are ongoing, and enrollment in one of these studies may be a viable option for therapy.

### CASE STUDY 2: Follow-Up

Alina’s elevated ALT, dyslipidemia, and fatty liver on radiology evaluation in the absence of being overweight or obese leads to further evaluation, including a liver biopsy and LAL assay through DBS testing. Liver biopsy shows enlarged hepatocytes with high lipid content, and LAL enzyme activity is <0.02 pmol/punch/hour (normal limit 24–134 pmol/punch/hour). Alina is diagnosed with CESD. Although there is currently no approved therapy, ongoing trials should be monitored for a potential avenue for treatment.

**TABLE 2.** US Laboratories for DBS Testing and *LIPA* Gene Sequencing<sup>56</sup>

LABORATORY	CONTACT INFORMATION	AVAILABLE TEST
Laboratory Corporation of America (Research Triangle Park, NC)	Phone: (800) 345-4363 Web site: <a href="http://www.labcorp.com/wps/portal/provider/testmenu">www.labcorp.com/wps/portal/provider/testmenu</a> LAL deficiency test code: 402300	DBS
Massachusetts General Hospital, Neurogenetics DNA/Biochemical Diagnostics Lab (Boston, MA)	Phone: (617) 726-5721 Web site: <a href="http://www.massgeneral.org/research/resourcelab.aspx?id=43">www.massgeneral.org/research/resourcelab.aspx?id=43</a>	DBS <i>LIPA</i>
Seattle Children’s Hospital, Biochemical Genetics Laboratory	Phone: (206) 987-2216 Web site: <a href="http://www.seattlechildrens.org/labman">www.seattlechildrens.org/labman</a>	DBS





## ALPERS SYNDROME

### *Pathophysiology*

Alpers-Huttenlocher syndrome (Alpers syndrome) is an inherited, monogenic, autosomal recessive disorder that occurs in approximately 1 in 100,000 patients. It is caused by mutation of the *POLG* gene,<sup>62,65</sup> which is the sole polymerase replicating mitochondrial DNA (mtDNA).<sup>66,67</sup> *POLG* mutations can result in a reduced number of mtDNA copies in the muscle, brain, and liver cells, causing a decrease in cellular energy that manifests in typical Alpers syndrome signs and symptoms and eventually leads to fatal brain and liver disease in children and young adults.<sup>62,63</sup> Onset of Alpers syndrome usually occurs in early childhood (age 2–4 years), although it can occur later.<sup>62,64,66</sup> The typical presentation includes 3 factors: refractory seizures including a focal aspect, psychomotor regression (often episodic), and liver disease.<sup>63</sup> Additional symptoms may include ataxia and neuropathy that can lead to areflexia.<sup>62,65,66</sup> Affected patients may also develop hypotonia that worsens until they can no longer control their muscles and movement, myoclonus, choreoathetosis, or parkinsonism. Migraines with visual sensations or auras are common, and patients may also have fatigue, inability to concentrate, irritability, memory loss, loss of language skills, and eyesight or hearing loss.

Patients with Alpers syndrome are at an increased risk for fatal hepatopathy if treated with the anticonvulsant VPA, a successful and popular first-line therapy for seizures that is also used to treat headaches and bipolar disorder.<sup>65,68-70</sup> This hepatopathy does not improve with discontinuation of the drug. More than 1 in every 37,000 patients exposed to VPA can develop liver toxicity, with the risk increasing to approximately 1 in every 500 pediatric patients on polytherapy.<sup>70,71</sup> The National Institutes of Health-funded Drug Induced Liver Injury Network studied 17 patients across 5 centers from 2004 to 2008 and found that a heterozygous defect in *POLG* was strongly associated with VPA toxicity (odds ratio 23.6).<sup>70</sup>

### *Diagnosis*

A diagnosis of mitochondrial disease should be considered in patients with hepatic steatosis with normal BMI; lactic acidosis and hypoglycemia; and when associated extrahepatic manifestations, such as neurological signs, myopathy, and developmental delay, are present. In patients with the standard presentation of Alpers syndrome (refractory seizures, psychomotor regression, and liver disease with or without failure), diagnosis can be confirmed by genotyping

### CASE STUDY 3: *Jacob*

Jacob is a 13-year-old Caucasian boy who presented to the emergency department 3 months ago with uncontrolled seizures and respiratory distress. The BMI is 20 kg/m<sup>2</sup>, and his height, weight, and head circumference were all in the 10th–50th percentile for his age. No dysmorphism was noted. Jacob's medical history showed delayed developmental milestones, as he did not learn to walk until age 24 months. Brain magnetic resonance imaging (MRI) at age 4 years was normal, and an intelligence quotient (IQ) test at age 10 years gave his IQ as 65 (verbal: 75; performance: 58). He has attention deficit hyperactivity disorder (ADHD) including motor and verbal tics. He is the second child of nonconsanguineous parents, and there is no family history of gastrointestinal or liver disease. His initial workup included an abdominal ultrasound that showed hepatomegaly with increased echogenicity. Electroencephalography showed generalized spikes and slow waves with focal sharp waves in the frontal regions. A brain MRI showed bilateral signal changes affecting the thalamus and caudate atrophy of the frontal, cerebellar, and temporal lobes. Routine laboratory workup including a CBC, electrolyte profile, liver enzymes, and renal function was ordered. Sodium valproate (VPA) was prescribed to control seizures (blood level maintained at 650–900 µmol/L). Three months later, the patient returns with increasing fatigue and vomiting.

for characteristic *POLG* mutations.<sup>63</sup> A467T is the most common mutation in *POLG*, followed by W748S and G848S.<sup>63,66</sup> Unless synthetic liver failure exists, liver biopsy should be considered to exclude Wilson’s disease and detect the presence of the histological criteria provided in **Table 3**. Muscle biopsy may also show depletion of mtDNA in Alpers patients but often provides normal results.<sup>66,72</sup> Additional criteria are provided in **Table 4**.

### Treatment

Treatment of Alpers syndrome is based on symptoms and patient support.<sup>73</sup> There is no cure or means to slow progression.

Toxic medications, such as VPA, should be eliminated and/or avoided in treatment regimens to avoid potential liver failure; alternatively, one may consider performing a *POLG* mutation screen prior to initiating VPA if other medications are contraindicated. In a review of clinical trials, there is no evidence supporting the use of any treatment intervention in primary mitochondrial disorders.<sup>74</sup> However, antioxidant therapies may provide symptom relief. Supplementation with coenzyme Q has shown beneficial effects on electron transport chain function, though its specific effectiveness and recommended dosing have not been defined.<sup>74,75</sup> In clinical practice, some patients with mitochondrial diseases report

**TABLE 3.** Major Liver Histological Criteria for Diagnosis of Alpers Syndrome<sup>63</sup>

3 OF THE FOLLOWING:	Microvesicular steatosis
	Proliferation of the bile ducts
	Hepatocytes dropout or focal necrosis with/without portal inflammation
	Ductal plate collapse
	Parenchymal disorganization or disarray of normal lobular structure
	Bridging fibrosis or cirrhosis
	Regenerative nodules
	Oncocytic change in scattered hepatocytes not affected by steatosis

**TABLE 4.** Minor Criteria for Diagnosis of Alpers Syndrome<sup>63</sup>

2 OF THE FOLLOWING:	Elevated cerebrospinal fluid (CSF) protein (>60 mg/dL)
	Brain proton magnetic resonance spectroscopy showing reduction of N-acetyl aspartate, normal total creatine, and elevated lactate in affected portions of the cerebral cortex, basal ganglia, and thalamus
	Cerebral volume loss
	At least 1 electroencephalogram with asymmetric or posterior high-amplitude slow waves (200–1000 µV, 0.73–3 Hz) mixed with lower-amplitude polyspike discharges (10–100 µV, 12–25 Hz)
	Optic atrophy or cortical blindness
	Abnormal visual-evoked potentials and normal electroretinogram
	Quantitative mtDNA depletion in skeletal muscle or liver
	Liver or skeletal muscle polymerase γ enzyme activity ≤10%
	Elevated blood or CSF lactate (≥3 mM) on at least 1 occasion with absent acute liver failure
	Isolated complex IV or combined I, III, and IV electron transport complex ≤20% of normal on liver respiratory chain testing
	Sibling with confirmed Alpers syndrome

improvement in muscle cramping and discomfort. Idebenone can be an effective option for treatment of ataxia, especially in patients with discordant visual acuities, and has been shown to be efficacious and safe in both pediatric and adult patients.<sup>76-78</sup> In addition to coenzyme Q, supplementation of various vitamins, including L-carnitine, folic acid, and creatine monohydrate, is often used in patients with mitochondrial disease. These natural compounds are generally considered harmless at currently prescribed doses, but there is no specific evidence for their efficacy outside of anecdotal reports and recommended treatment protocols do not exist.<sup>75</sup> In general, systemic manifestations of Alpers syndrome preclude the option of liver transplantation as treatment. Liver transplantation has been attempted in VPA-induced liver failure with successful engraftment in most cases, but these patients still died soon after as a result of progressive neurological deterioration.<sup>65,79,80</sup> Conversely, patients who have disease with deoxyguanosine kinase deficiency and no central nervous system involvement may benefit from liver transplantation.<sup>81</sup>

### CASE STUDY 3: *Follow-Up*

Increased fatigue and vomiting indicate a need to evaluate Jacob further. Additional laboratory workup is ordered, and relevant results include an ALT of 306 IU/L, total bilirubin of 7.7 mg/dL, international normalized ratio of 2.2, ammonia level of 123 mg/L, and lactate level of 3.9 mmol/L. The international normalized ratio did not improve with vitamin K repletion. These symptoms and results are indicative of acute

liver failure. The patient also shows many warning signs of Alpers syndrome, including delayed development, uncontrolled seizures, and inability to concentrate (previous diagnosis of ADHD). The VPA regimen is stopped immediately to avoid any further contribution to liver disease or hepatopathy, and a liver biopsy is ordered. Biopsy shows microvesicular steatosis, bile duct proliferation, and bridging cirrhosis, confirming the diagnosis. Although there is no approved treatment for Alpers syndrome, he is put on a trial of supplements that include coenzyme Q and L-carnitine and monitored for symptom improvement.

## SUMMARY

Obesity causes most fatty liver disease; however, it is not the cause of all fatty liver disease. Other causes of NAFLD include cystic fibrosis, Wilson's disease, total parenteral nutrition, diabetes mellitus, lipodystrophies, fatty acid oxidation defects, mitochondrial hepatopathies (such as Alpers syndrome), LAL deficiency, drug toxicity, and rapid weight loss. Clues to NAFLD not caused by obesity include absence of obesity, microvesicular steatosis predominance, medication and herb exposure, clinical features other than obesity, and significant hypercholesterolemia. It is also important to note that, whereas these diseases are examples of nonobese causes of fatty liver disease, it is still possible for them to occur in obese patients, and therefore, care providers should continue to entertain them in their differential diagnosis of NAFLD in both obese and nonobese individuals.

## REFERENCES

1. Williams CD, Stengel J, Asike MI, et al. Prevalence of nonalcoholic fatty liver disease and nonalcoholic steatohepatitis among a largely middle-aged population utilizing ultrasound and liver biopsy: a prospective study. *Gastroenterology* 2011;140:124.
2. Vernon G, Baranova A, Younossi ZM. Systematic review: the epidemiology and natural history of non-alcoholic fatty liver disease and non-alcoholic steatohepatitis in adults. *Aliment Pharmacol Ther*. 2011;34:274-285.
3. Lazo M, Hernaez R, Eberhardt MS, et al. Prevalence of nonalcoholic fatty liver disease in the United States: the Third National Health and Nutrition Examination Survey, 1988-1994. *Am J Epidemiol*. 2013;178:38-45.
4. Strauss RS, Barlow SE, Dietz WH. Prevalence of abnormal serum aminotransferase values in overweight and obese adolescents. *J Pediatr*. 2000;136:727-733.
5. Quirós-Tejeira RE, Rivera CA, Ziba TT, et al. Risk for nonalcoholic fatty liver disease in Hispanic youth with BMI > or =95th percentile. *J Pediatr Gastroenterol Nutr*. 2007;44:228-236.
6. Fabbrini E, Sullivan S, Klein S. Obesity and nonalcoholic fatty liver disease: biochemical, metabolic and clinical implications. *Hepatology* 2010;51:679-689.
7. Alisi A, Carpino G, Nobili V. Paediatric nonalcoholic fatty liver disease. *Curr Opin Gastroenterol*. 2013;29:279-284.



8. Nobili V, Svegliati-Baroni G, Alisi A, et al. A 360-degree overview of paediatric NAFLD: recent insights. *J Hepatol*. 2013;58:1218–1229.
9. Yüksel F, Türkkan D, Yüksel I, et al. Fatty liver disease in an autopsy series of children and adolescents. *Hippokratia* 2012;16:61–65.
10. Roberts EA and Schilsky ML. A practice guideline on Wilson disease. *Hepatology* 2003;37:1475–1492.
11. Frydman M. Genetic aspects of Wilson's disease. *J Gastroenterol Hepatol*. 1990;5:483–490.
12. O'Connor JA and Sokol RJ. In: *Liver Disease in Children*. Cambridge, England: Cambridge University Press; 2007; 626–659.
13. Bull PC, Thomas GR, Rommens JM, et al. The Wilson disease gene is a putative copper transporting P-type ATPase similar to the Menkes gene. *Nat Genet*. 1993;5:327–337.
14. Tanzi RE, Petrukhin K, Chernov I, et al. The Wilson disease gene is a copper transporting ATPase with homology to the Menkes disease gene. *Nat Genet*. 1993;5:344–350.
15. Petrukhin K, Fischer SG, Pirastu M, et al. Mapping, cloning and genetic characterization of the region containing the Wilson disease gene. *Nat Genet*. 1993;5:338–343.
16. Yamaguchi Y, Heiny ME, Gitlin JD. Isolation and characterization of a human liver cDNA as a candidate gene for Wilson disease. *Biochem Biophys Res Commun*. 1993;197:271–277.
17. Wilson SAK. Progressive lenticular degeneration: a familial nervous disease associated with cirrhosis of the liver. *Brain* 1912;34:295–509.
18. Fleischer B. Ueber einer der "Pseudosclerose" nahestehende bisher unbekannte Krankheit (gekennzeichnet durch Tremor, psychische Störungen, braeunliche Pigmentierung bestimmter Gewebe, insbesondere Such der Hornhauptperipherie, Lebercirrhose). *Deutsch Z Nerven Heilk* 1912;44:179–201.
19. Sternlieb I. Perspectives on Wilson's disease. *Hepatology* 1990;12:1234–1239.
20. Steindl P, Ferenci P, Dienes HP, et al. Wilson's disease in patients presenting with liver disease: a diagnostic challenge. *Gastroenterology* 1997;113:212–218.
21. Roberts EA and Schilsky ML. Diagnosis and treatment of Wilson disease: an update. *Hepatology* 2008;47:2089–2111.
22. Wilson DC, Phillips MJ, Cox DW, et al. Severe hepatic Wilson's disease in preschool-aged children. *J Pediatr*. 2000;137:719–722.
23. Demirkiran M, Jankovic J, Lewis RA, et al. Neurologic presentation of Wilson disease without Kayser-Fleischer rings. *Neurology* 1996;46:1040–1043.
24. Gow PJ, Smallwood RA, Angus PW, et al. Diagnosis of Wilson's disease: an experience over three decades. *Gut* 2000;46:415–419.
25. Tu JB and Blackwell RQ. Studies on levels of penicillamine-induced cupriuresis in heterozygotes of Wilson's disease. *Metabolism* 1967;16:507–513.
26. Garcia-Villarreal L, Daniels S, Shaw SH, et al. High prevalence of the very rare Wilson disease gene mutation Leu708Pro in the island of Gran Canaria (Canary Islands, Spain): a genetic and clinical study. *Hepatology* 2000;32:1329–1336.
27. Martins da Costa C, Baldwin D, Portmann B, et al. Value of urinary copper excretion after penicillamine challenge in the diagnosis of Wilson's disease. *Hepatology* 1992;15:609–615.
28. Alt ER, Sternlieb I, Goldfischer S. The cytopathology of metal overload. *Int Rev Exp Pathol*. 1990;31:165–188.
29. Ludwig J, Moyer TP, Rakela J. The liver biopsy diagnosis of Wilson's disease. Methods in pathology. *Am J Clin Pathol*. 1994;102:443–446.
30. Drugs at FDA. US Food and Drug Administration Web site. <http://www.accessdata.fda.gov/Scripts/cder/drugsatfda/index.cfm>. Accessed April 7, 2014.
31. Daily Med Web site. <http://dailymed.nlm.nih.gov/dailymed/lookup.cfm?setid=0ed52ecf-cda9-4a06-bacc-2c2827cc8967>. Updated December 1, 2013. Accessed April 7, 2014.
32. Brewer GJ. Zinc acetate for the treatment of Wilson's disease. *Expert Opin Pharmacother*. 2001;2:1473–1477.
33. Medici V and Sturniolo GC. Tetrathiomolybdate, a copper chelator for the treatment of Wilson disease, pulmonary fibrosis and other indications. *IDrugs* 2008;11:592–606.
34. Vitamin E. National Institutes of Health Office of Dietary Supplements Web site. <http://ods.od.nih.gov/factsheets/VitaminE-HealthProfessional/>. Published June 5, 2013. Accessed April 7, 2014.
35. Gabrowski G, Charnas L, Du H. In: *The Metabolic and Molecular Basis of Inherited Metabolic Disease*. 8th ed. New York: McGraw-Hill; 2012.

36. Du H, Cameron TL, Garger SJ, et al. Wolman disease/cholesteryl ester storage disease: efficacy of plant-produced human lysosomal acid lipase in mice. *J Lipid Res.* 2008;49:1646–1657.
37. Meikle PJ, Hopwood JJ, Clague AE, et al. Prevalence of lysosomal storage disorders. *J Am Med Assoc.* 1999;281:249–254.
38. Assmann G and Seedorf U. In: *Metabolic and Molecular Bases of Inherited Diseases*. New York: McGraw-Hill; 2001; 3551–3572.
39. Boldrini R, Devito R, Biselli R, et al. Wolman disease and cholesteryl ester storage disease diagnosed by histological and ultrastructural examination of intestinal and liver biopsy. *Pathol Res Pract.* 2004;200:231–240.
40. Krivit W, Peters C, Dusenbery K, et al. Wolman disease successfully treated by bone marrow transplantation. *Bone Marrow Transplant.* 2000;26:567–570.
41. Stein J, Garty BZ, Dror Y, et al. Successful treatment of Wolman disease by unrelated umbilical cord blood transplantation. *Eur J Pediatr.* 2006;166:663–666.
42. Bernstein DL, Hülkova H, Bialer MG, et al. Cholesteryl ester storage disease: review of the findings in 135 reported patients with an underdiagnosed disease. *J Hepatol.* 2013;58:1230–1243.
43. Balwani M, Breen C, Enns GM, et al. Clinical effect and safety profile of recombinant human lysosomal acid lipase in patients with cholesteryl ester storage disease. *Hepatology* 2013;58:950–957.
44. Zhang B and Porto AF. Cholesteryl ester storage disease: protean presentations of lysosomal acid lipase deficiency. *J Pediatr Gastroenterol Nutr.* 2013;56:682–685.
45. Muntoni S, Wiebusch H, Jansen-Rust M, et al. Prevalence of cholesteryl ester storage disease. *Arterioscler Thromb Vasc Biol.* 2007;27:1866–1868.
46. Seedorf U, Wiebusch H, Muntoni S, et al. A novel variant of lysosomal acid lipase (Leu336>Pro) associated with acid lipase deficiency and cholesterol ester storage disease. *Arterioscler Thromb Vasc Biol.* 1995;15:773–778.
47. Muntoni S, Wiebusch H, Funke H, et al. Homozygosity for a splice junction mutation in exon 8 of the gene encoding lysosomal acid lipase in a Spanish kindred with cholesteryl ester storage disease (CESD). *Hum Genet.* 1995;95:491–494.
48. Pagani F, Garcia R, Pariyarath R, et al. Expression of lysosomal acid lipase mutants detected in three patients with cholesteryl ester storage disease. *Hum Mol Genet.* 1996;5:1611–1617.
49. Klima H, Ullrich K, Aslanidis C, et al. A splice junction mutation causes deletion of a 72-base exon from the mRNA for lysosomal acid lipase in a patient with cholesteryl ester storage disease. *J Clin Invest.* 1993;92:2713–2718.
50. Gasche C, Aslanidis C, Kain R, et al. A novel variant of lysosomal acid lipase in cholesteryl ester storage disease associated with mild phenotype and improvement on lovastatin. *J Hepatol.* 1997;27:744–750.
51. Redonnet-Vernhet I, Chatelut M, Salvayre R, et al. A novel lysosomal acid lipase gene mutation in a patient with cholesteryl ester storage disease. *Hum Mutat.* 1998;11:335–336.
52. Redonnet-Vernhet I, Chatelut M, Basile JP, et al. Cholesteryl ester storage disease: relationship between molecular defects and in situ activity of lysosomal acid lipase. *Biochem Mol Med.* 1997;62:42–49.
53. Ameis D, Brockmann G, Knoblich R, et al. A 5' splice-region mutation and a dinucleotide deletion in the lysosomal acid lipase gene in two patients with cholesteryl ester storage disease. *J Lipid Res.* 1995;36:241–250.
54. Rust S, Funke H, Assmann G. Mutagenically separated PCR (MS-PCR): a highly specific one step procedure for easy mutation detection. *Nucleic Acids Res.* 1993;21:3623–3629.
55. Hamilton J, Jones I, Srivastava R, et al. A new method for the measurement of lysosomal acid lipase in dried blood spots using the inhibitor Lalistat 2. *Clin Chim Acta.* 2012;413:1207–1210.
56. LAL Deficiency Source Web site. <http://www.laldeficiencysource.com/diagnostic-testing/>. Accessed April 7, 2014.
57. Ferry GD, Whisnand HH, Finegold MJ, et al. Liver transplantation for cholesteryl ester storage disease. *J Ped Gastroenterol Nutr.* 1991;12:376–378.
58. Leone L, Ippoliti PF, Antonicelli R, et al. Treatment and liver transplantation for cholesterol ester storage disease. *J Ped.* 1995;127:509–510.
59. Yoshida H and Kuriyama M. Genetic lipid storage disease with lysosomal acid lipase deficiency in rats. *Lab Anim Sci.* 1990;40:486–489.
60. Kuriwaki K and Yoshida H. Morphological characteristics of lipid accumulation in liver-constituting cells of acid lipase deficiency rats (Wolman's disease model rats). *Pathol Int.* 1999;49:291–297.
61. Leavitt M, Burt AD, Hu W, et al. Recombinant lysosomal

- acid lipase normalized liver weight, transaminases and histopathological abnormalities in an in vivo model of cholesterol storage ester disease. *J Hepatol*. 2011;54(Suppl 1):S358.
62. Alpers-Huttenlocher syndrome. Genetics Home Reference Website. <http://ghr.nlm.nih.gov/condition/alters-huttenlochersyndrome>. Published January 27, 2014. Accessed April 7, 2014.
  63. Nguyen KV, Sharief FS, Chan SSL, et al. Molecular diagnosis of Alpers syndrome. *J Hepatol*. 2006;45:108–116.
  64. Uusimaa J, Hinttala R, Rantala H, et al. Homozygous W748S mutation in the POLG1 gene in patients with juvenile-onset Alpers syndrome and status epilepticus. *Epilepsia* 2008;49:1038–1045.
  65. McFarland R, Hudson G, Taylor RW, et al. Reversible valproate hepatotoxicity due to mutations in mitochondrial RNA polymerase (POLG1). *Arch Dis Child*. 2008;93:151–153.
  66. Naess K, Barbaro M, Bruhn H, et al. Complete deletion of a POLG1 allele in a patient with Alpers syndrome. *JIMD Rep*. 2012;4:67–73.
  67. Clayton DA. Replication of animal mitochondrial DNA. *Cell* 1982;28:693–705.
  68. Koenig SA, Buesing D, Longh E, et al. Valproic acid-induced hepatopathy: nine new fatalities in Germany from 1994 to 2003. *Epilepsia* 2006;47:2027–2031.
  69. Schwabe MJ, Dobyns WB, Burke B, et al. Valproate-induced liver failure in one of two siblings with Alpers disease. *Pediatr Neurol*. 1997;16:337–343.
  70. Stewart JD, Horvath R, Baruffini E, et al. Polymerase  $\gamma$  gene POLG determines the risk of sodium valproate-induced liver toxicity. *Hepatology* 2010;52:1791–1796.
  71. Dreifuss FE, Langer DH, Moline KA, et al. Valproic acid hepatic fatalities. II. US experience since 1984. *Neurology* 1989;39:201–207.
  72. Naviaux RK, Nyhan WL, Barshop BA, et al. Mitochondrial DNA polymerase  $\gamma$  deficiency and mtDNA depletion in a child with Alpers syndrome. *Ann Neurol*. 1999;45:54–58.
  73. NINDS Alpers' disease information page. National Institute of Neurological Disorders and Stroke Web site. [http://www.ninds.nih.gov/disorders/altersdisease/altersdisease.htm#ls\\_there\\_any\\_treatment](http://www.ninds.nih.gov/disorders/altersdisease/altersdisease.htm#ls_there_any_treatment). Modified September 16, 2011. Accessed April 7, 2014.
  74. Chinnery P, Majamaa K, Turnbull D, et al. Treatment for mitochondrial disorders. *Cochrane Database Syst Rev*. 2006;1:CD004426.
  75. Horvath R, Gorman G, Chinnery PF. How can we treat mitochondrial encephalomyopathies? Approaches to therapy. *Neurotherapeutics* 2008;5:558–568.
  76. Bénit P, El-Khoury R, Schiff M, et al. Genetic background influences mitochondrial function: modeling mitochondrial disease for therapeutic development. *Trends Mol Med*. 2010;16:210–217.
  77. Klopstock T, Yu-Wai-Man P, Dimitriadis K, et al. A randomized placebo-controlled trial of idebenone in Leber's hereditary optic neuropathy. *Brain* 2011;134:2677–2686.
  78. Di Prospero NA, Baker A, Jeffries N, et al. Neurological effects of high-dose idebenone in patients with Friedreich's ataxia: a randomized, placebo-controlled trial. *Lancet Neurol*. 2007;6:878–886.
  79. Kayihan N, Nennesmo I, Erizon BG, et al. Fatal deterioration of neurological disease after orthotopic liver transplantation for valproic acid-induced liver damage. *Pediatr Transplant*. 2000;4:211–214.
  80. Delarue A, Paut O, Guys JM, et al. Inappropriate liver transplantation in a child with Alpers-Huttenlocher syndrome misdiagnosed as valproate-induced acute liver failure. *Pediatr Transplant*. 2000;4:67–71.
  81. Scaglia F, Dimmock D, Wong LG. DGOUK-related mitochondrial DNA depletion syndrome, hepatocerebral form. National Center for Biotechnology Information Web site. <http://www.ncbi.nlm.nih.gov/books/NBK7040>. Published June 18, 2009. Accessed April 7, 2014.

