

Guideline for the Evaluation of Cholestatic Jaundice in Infants: Joint Recommendations of the North American Society for Pediatric Gastroenterology, Hepatology, and Nutrition and the European Society for Pediatric Gastroenterology, Hepatology, and Nutrition

*Rima Fawaz, †Ulrich Baumann, ‡Udeme Ekong, §Björn Fischler, ||Nedim Hadzic, ¶Cara L. Mack, #Valérie A. McLin, **Jean P. Molleston, ††Ezequiel Neimark, ‡‡Vicky L. Ng, and §§Saul J. Karpen

ABSTRACT

Cholestatic jaundice in infancy affects approximately 1 in every 2500 term infants and is infrequently recognized by primary providers in the setting of physiologic jaundice. Cholestatic jaundice is always pathologic and indicates hepatobiliary dysfunction. Early detection by the primary care physician and timely referrals to the pediatric gastroenterologist/hepatologist are important contributors to optimal treatment and prognosis. The most common causes of cholestatic jaundice in the first months of life are biliary atresia (25%–40%) followed by an expanding list of monogenic disorders (25%), along with many unknown or multifactorial (eg, parenteral nutrition-related) causes, each of which may have time-sensitive and distinct treatment plans. Thus, these guidelines can have an essential role for the evaluation of neonatal cholestasis to optimize care. The recommendations from this clinical practice guideline are based upon review and analysis of published literature and the combined experience of the authors. The committee recommends that any infant noted to be jaundiced after 2 weeks of age be evaluated for cholestasis with measurement of total and direct serum bilirubin, and that an elevated serum direct bilirubin level (direct bilirubin levels >1.0 mg/dL or >17 μ mol/L) warrants timely consideration for evaluation and referral to a pediatric gastroenterologist or hepatologist. Of note, current differential diagnostic plans now incorporate consideration of modern broad-based next-generation DNA sequencing technologies in the proper clinical context. These recommendations are a general guideline and are not intended as a substitute for clinical judgment or as a protocol for the care of all infants with cholestasis. Broad implementation of these recommendations is expected to reduce the time to the diagnosis of pediatric liver diseases, including biliary atresia, leading to improved outcomes.

Key Words: biliary atresia, hepatoportocenterostomy, Kasai, liver biopsy, neonatal cholestasis, neonatal jaundice, radionuclide scan

(*JPGN* 2017;64: 154–168)

PREAMBLE

Cholestatic jaundice in infancy is an uncommon but potentially serious problem that indicates hepatobiliary dysfunction. Early detection of cholestatic jaundice by the primary care physician and timely, accurate diagnosis by the pediatric gastroenterologist are important for successful treatment and an optimal prognosis. The Cholestasis Guideline Committee consisted of 11 members of 2 professional societies: the North American Society for Gastroenterology, Hepatology and Nutrition, and the European Society for Gastroenterology, Hepatology and Nutrition. This committee has responded to a need in pediatrics and developed an updated clinical practice guideline for the diagnostic evaluation of cholestatic jaundice in the infant. There is an obligate focus upon identifying infants with cholestasis due to biliary atresia (BA), but also incorporating the recognition that most forms of cholestasis in this age group are due to non-BA causes. Thus, a structured and broad-based diagnostic approach is required. The recommendations presented in this clinical practice guideline are based on review and analysis of published literature as well as the experience of the authors and colleagues. The quality of evidence supporting the recommendations is based on the Grading of Recommendation, Assessment, Development, and Evaluation workgroup. Each recommendation is assigned a class (reflecting benefit vs risk) and level (assessing strength or certainty). Using these approaches, the recommendations presented herein provide an approach to diagnose infants with cholestasis. These guidelines are intended to be flexible and tailored to the individual patient and local practice and are not meant to determine standards of care for all infants. This guideline has been approved both by the North American Society

Received April 20, 2016; accepted July 6, 2016.

From the *Division of Gastroenterology, Hepatology and Nutrition, Boston Children's Hospital, Harvard Medical School, Boston, MA, the †Division Paediatric Gastroenterology and Hepatology, Department of Paediatric Kidney, Liver and Metabolic Diseases, Hannover Medical School, Hannover, Germany, the ‡Yale New Haven Hospital Transplantation Center, Yale University School of Medicine, New Haven, CT, the §Department of Pediatrics, Karolinska University Hospital, CLINTEC, Karolinska Institute, Stockholm, Sweden, the ||Paediatric Centre for Hepatology, Gastroenterology and Nutrition King's College Hospital, London, UK, the ¶Section of Pediatric Gastroenterology, Hepatology and Nutrition, Children's Hospital Colorado, University of Colorado School of

Medicine, Aurora, CO, the #Swiss Center for Liver Disease in Children, University Hospitals Geneva, Geneva, Switzerland, the **Indiana University School of Medicine/Riley Hospital for Children, Indianapolis, IN, the ††Division of Pediatric Gastroenterology, Hepatology and Nutrition, Hasbro Children's Hospital, The Warren Alpert School of Medicine at Brown University, Providence, RI, the ‡‡Division of Pediatric Gastroenterology, Hepatology and Nutrition, The Hospital for Sick Children, University of Toronto, Toronto, Canada, and the §§Department of Pediatrics, Emory University School of Medicine/Children's Healthcare of Atlanta, Atlanta, GA.

for Gastroenterology, Hepatology and Nutrition and the European Society for Gastroenterology, Hepatology and Nutrition after an extensive review.

LITERATURE SEARCH

A systematic literature search was performed using accessible databases of relevance: PubMed, MEDLINE from 2002 until 2015 for targeted topics and keywords (see Supplementary Digital Content 1, Table, <http://links.lww.com/MPG/A733>). The search involved only articles published in English and involving human subjects.

GRADES OF EVIDENCE

Grades of evidence for each statement were based on the grading of the literature and were assigned using the American Association for the Study of Liver Diseases Practice Guidelines method: Grading of Recommendation Assessment, Development, and Evaluation workgroup with minor modifications (1). The strength of recommendations in the Grading of Recommendation Assessment, Development, and Evaluation system was classified as outlined in Supplementary Digital Content 2, Table, <http://links.lww.com/MPG/A734>.

BACKGROUND

Cholestasis is defined as reduced bile formation or flow resulting in the retention of biliary substances within the liver normally excreted into bile and destined for elimination into the intestinal lumen. Cholestasis is generally recognized by evaluation of serum studies, with elevation of serum conjugated (or direct) bilirubin and bile acids as central readily identified features of hepatobiliary dysfunction. Although cholestasis and hyperbilirubinemia are not synonymous, during cholestasis normal bile acid flux and conjugated bilirubin excretion into bile are both impaired and frequently linked. Hence, a central feature of conjugated (or direct) hyperbilirubinemia is a practical clinical marker and surrogate of cholestasis. Distinguishing jaundice caused by cholestasis from noncholestatic conditions (such as physiologic jaundice of the newborn) is critical because cholestatic jaundice is likely pathologic, and therefore patients with cholestatic jaundice will benefit from prompt diagnosis and institution of specific therapy. Cholestasis can be classified into biliary (obstructive, large extrahepatic, or small intrahepatic bile ducts) or hepatocellular (defect in membrane transport, embryogenesis, or metabolic dysfunction) in origin.

Cholestatic jaundice affects approximately 1 in every 2500 term infants and is thus infrequently seen by most providers taking care of infants (2). The most common causes of cholestatic jaundice in the first months of life are BA (25%–40%) and an array of individually uncommon genetic disorders (25%). Often, however, the etiology is unknown. It may be associated with prematurity or intravenous soy lipid infusions (see following sections) (3). The rate of patients designated by the descriptive term, “idiopathic neonatal hepatitis” as the cause of neonatal cholestasis, continues to decline with advancements in diagnostic evaluation and discovery of new

etiologies, now clinically discoverable with the use of available next-generation DNA sequencing technologies (see following sections). Other causes of neonatal cholestasis include extrahepatic obstruction from common duct gallstones or choledochal cyst; metabolic disorders such as tyrosinemia type I, galactosemia, and inborn errors of bile acid metabolism; panhypopituitarism; Alagille syndrome (ALGS); infection; parenteral nutrition (PN)-associated liver disease and a broad array of generally rare disorders (Table 1) (4–42). The common clinical feature of impaired bile flow resulting from either biliary obstruction or hepatocellular metabolic derangements requires a broad-minded approach to the individual cholestatic infant—without which opportunities for providing effective therapeutic interventions may be overlooked.

The incidence of neonatal cholestasis is increased in premature infants, more so in those born at the limits of viability than those born closer to term. PN-related cholestasis is present in up to one-fifth of neonates receiving PN for >2 weeks (43). Longer duration of PN and intestinal failure are independent risk factors for the development of PN cholestasis in infants and has led to the consideration for reducing exposure to soy lipids wherever appropriate (43,44). In addition, small for gestational age is a strong independent risk factor for neonatal cholestasis (45). This clinical guideline is not meant to address cholestasis in the preterm infant on PN, but close follow-up and serial measurements of fractionated bilirubin levels early in life are important, alongside monitoring growth and tolerance of enteral feedings. Persistent cholestasis in any infant should, however, be considered pathologic and identifiable causes of cholestasis, including BA should be ruled out in a timely fashion, because another cholestatic condition can certainly be present in an infant who requires PN. It should be noted that the incidence of BA or genetic forms of cholestasis is the same in premature as in term infants; thus, premature infants warrant consideration for the same evaluation of neonatal cholestasis as do full-term infants. Several studies demonstrate a higher incidence of BA in preterm infants compared with term infants, and delayed diagnosis results in poorer outcome (46,47).

Biliary Atresia

BA is the most frequent identifiable cause of obstructive jaundice in the first 3 months of life. The prevalence of BA varies according to location around the globe: ~1 in 6000 live births in Taiwan, 1 in 12,000 in the United States, 1 in 19,000 in Canada, and 1 in 18,000 in Europe (48–50). There are 3 classifications of BA: the nonsyndromic form (84%), which is the most common; BA with at least 1 malformation but without laterality (eg, situs inversus) defects (6%); and the syndromic BA with laterality defects (10%). The latter 2 groups have other associated anomalies predominantly in the cardiovascular (16%) and gastrointestinal (14%) systems, but the group without laterality defects has more frequent genitourinary anomalies. Patients with BA with laterality defects more commonly have splenic anomalies (51). The etiology of BA is unknown and theories of pathogenesis include genetic contributions to bile duct dysmorphogenesis, viral infection, toxins, chronic inflammatory or

Address correspondence and reprint requests to Saul J. Karpen, MD, PhD, Department of Pediatrics, Emory University School of Medicine/Children’s Healthcare of Atlanta, 1760 Haygood Dr, HSRB E204, Atlanta, GA 30322 (e-mail: skarpen@emory.edu).

Supplemental digital content is available for this article. Direct URL citations appear in the printed text, and links to the digital files are provided in the HTML text of this article on the journal’s Web site (www.jpgn.org).

C.L.M., J.P.M., V.L.N., and S.J.K. are members of the NIH-supported ChiLDReN network, which focuses upon pediatric cholestatic diseases;

N.H. is a consultant for Alynam Pharmaceuticals and Alexion UK; E.N. is currently employed by Vertex Pharmaceuticals; S.J.K. is an unpaid consultant from Intercept Pharmaceuticals.

The authors report no conflicts of interests.

Copyright © 2016 by European Society for Pediatric Gastroenterology, Hepatology, and Nutrition and North American Society for Pediatric Gastroenterology, Hepatology, and Nutrition

DOI: 10.1097/MPG.0000000000001334

TABLE 1. Anatomic and monogenic disorders of neonatal cholestasis

Disease	Presentation	Radiology	Gene (s)	Gene function	References
Multisystem disease Alagille syndrome	GGTP, cholesterol often elevated, eye, and cardiac findings, LB not always clearly diagnostic when performed early in life	Vertebral anomalies	<i>JAG1</i> ; <i>NOTCH2</i>	Signaling ligand; receptor for Jagged 1	(5,6)
ARC syndrome	Lax skin, limb contractures, renal tubular acidosis		<i>VPS33B</i> ; <i>VIPAR</i>	Membrane protein recycling; basolateral sorting of canalicular proteins involved in bile secretion	(7–9)
Congenital disorders of glycosylation	Multisystemic		Numerous genes coding for glycosylation enzymes	N- and O- protein glycosylation leading to impaired function	(10,11)
Cystic fibrosis	Elevated sweat chloride; possible ductular proliferation on LB		Cystic fibrosis trans-membrane receptor (<i>CFTR</i>)	Chloride channel	(12,13)
Mitochondrial disorders	Multisystemic		Nuclear genes; mitochondrial genes	May impact mtDNA replication, protein translation, electron transport	(14–16)
Neonatal ichthyosis sclerosing cholangitis syndrome	Hypotrichosis, alopecia, cholestasis		<i>CLDN1</i>	Claudin-1: tight junctions	(17)
Panhypopituitarism	LB: duct paucity, low pituitary hormones on stimulation, adrenal insufficiency Typical stigmata	MRI may reveal microadenoma or absent sella	Unknown	Unknown	(18)
Trisomy 21 Extrahepatic bile duct abnormalities Biliary atresia	LB diagnostic of obstruction with bile duct proliferation and bile duct plugs; acholic stools	Situs or vascular anomalies in 5% to 10%; possible absence of gallbladder Cyst seen by US	Unknown	Unknown	(19)
Choledochal cyst	Abdominal mass along with features that overlap with BA (see below)	US and IOC diagnostic	<i>ABCB4</i>	Multidrug resistance P-glycoprotein, MDR3	(19)
Choledocholithiasis	Acholic stools	Echogenic ascites			
Congenital perforation of the common bile duct	Ascites without liver disease	IOC shows pruning of small bile ducts	<i>SERPINA1</i>	Anti-protease	(20–23)
Neonatal sclerosing cholangitis	GGTP often >800 IU/L; LB shows small duct destruction		<i>CYP7B1</i> ; <i>AKR1D1</i> (<i>SRD5B1</i>); <i>HSD3B7</i>	Oxysterol 7 α -hydroxylase Δ 4–3-oxosteroid-5 β -reductase deficiency 3 β -hydroxy- Δ 5-C27-steroid dehydrogenase deficiency	(24–26)
Hepatocellular diseases Alpha-1-antitrypsin deficiency	GGTP often high, α -1-antitrypsin level low (often falsely low in neonates), Pi type ZZ or SZ GGTP normal, FABMS of urinary bile acids, may present with cirrhosis, fat-soluble vitamin deficiencies		<i>BAAT</i> ; <i>BAL</i>	Absence of conjugation	(27,28)
Bile acid synthesis defects	FABMS of urinary bile acids				
Bile acid conjugation defects					

TABLE 1. (Continued)

Disease	Presentation	Radiology	Gene (s)	Gene function	References
PFIC1	GGTP low or normal; diarrhea and FTT; LB/EM helpful		<i>ATP8B1</i>	FIC1 translocates phospholipids from outer to inner canalicular membrane (floppase)—also expressed in intestine; considered multisystem disease	(29)
PFIC2	Low or normal GGTP; LB/EM helpful		<i>ABCB11</i>	Bile salt export pump	(30)
PFIC3	Elevated GGTP		<i>ABCB4</i>	Phospholipid flippase responsible for phosphatidylcholine transport into bile	(31)
Tight junction protein 2 mutations	Severe cholestasis		<i>TJP2</i>	Failure of tight junctions and protein localization	(32)
Transient neonatal cholestasis (neonatal hepatitis)	GGTP and AP 200 to 400 IU/L, ALT and AST 80 to 200 IU/L, LB negative for obstruction		<i>ATP8B1; ABCB11; ABCB4</i>	FIC1 polymorphisms; MDR3 polymorphisms	(19,33)
Inborn errors of metabolism					
Urea cycle defects					
Citrin deficiency	Normal liver enzymes or slightly elevated		<i>SLC25A13</i>	Mitochondrial aspartate-glutamate carrier	(34,35)
Ornithine trans-carbamylase deficiency	Neonatal hyperammonemia with/without cholestasis and with/without liver failure		<i>OTC</i>	Mitochondrial enzyme of urea cycle	(36)
Carbohydrate metabolism					
Galactosemia	Cholestasis and liver dysfunction		<i>GALT</i>	Galactose-1-phosphate uridylyltransferase	(37–39)
Amino acid metabolism					
Tyrosinemia type 1	May present with liver failure, Fanconi-related nephropathy, or seizures		<i>FAH</i>	Fumarylacetoacetate hydrolase	(40)
Lipid metabolism					
Niemann-Pick type C	Splenomegaly		<i>NPC1</i>	acid sphingomyelinase	(41)
Lysosomal acid lipase deficiency (Wolman disease)	Hepatomegaly, features suggesting NAFLD (neonatal liver failure)	Hyperechoic liver	<i>LIPA</i>	Lysosomal acid lipase	(42)

When multiple mutations have been identified, the original paper is referenced. This list is not exhaustive; rather it is an overview of the most characterized genetic diseases and congenital conditions which may present as neonatal cholestasis.
 ALT = alanine aminotransferase; AP = alkaline phosphatase; ARC = arthrogryposis-renal dysfunction-cholestasis syndrome; AST = aspartate aminotransferase; CT = computed tomography; EM = electron microscopy; FABMS = fast atom bombardment mass spectroscopy; FTT = failure to thrive; GGTP = gamma-glutamyl transferase; IOC = intraoperative cholangiogram; LB = liver biopsy; MDR3 = multidrug resistance 3 gene; MRI = magnetic resonance imaging; mtDNA = mitochondrial DNA; NAFLD = nonalcoholic fatty liver disease; PFIC = progressive familial intrahepatic cholestasis; US = ultrasound.

autoimmune-mediated bile duct injury (52–55). Direct hyperbilirubinemia is identified sooner after birth in patients with BA compared with normal (control, noncholestatic) infants, suggesting that the initiation of the biliary injury occurs before, or soon after birth (ie, perhaps due to intrauterine insult or genetic etiology), thus minimizing the likelihood of biliary tract disease acquired after birth (56). Timely diagnosis is important to optimize the response to a Kasai hepatic portoenterostomy (HPE) aimed at reestablishing bile flow (57). If the HPE is performed within the first 60 days of life, ~70% of patients will establish bile flow; after 90 days of life <25% of patients will have bile flow (3). Late diagnosis of BA however remains a problem worldwide for a variety of reasons including the obligate visual overlap with normal physiologic jaundice and the lack of a readily applicable newborn screening. The average age at HPE in the United States is 61 days and 44% of patients still undergo HPE after 60 days of life (58). In Europe, late diagnosis is also a challenge and average age at HPE has been reported between 57 and 68 days (59–61). In the largest outcome series from Canada, medium age at HPE was 55 days but late referral was still problematic (49). Although not systematically evaluated, surgical outcome has been associated with the expertise in performing HPE in Europe, with improved outcome seen with centralized care models (49,62,63). In the United States this may be more challenging, but referral to a specialized center with expertise in performing HPE remains crucial.

The optimal management of infants with delayed presentation of BA remains controversial. Some series report successful HPE drainage beyond 90 days of life reaching 13% to 35% (49,58,64). In a large series that examined outcomes in 743 infants with BA, 2-, 5-, 10-, and 15-year survival rates with native liver were 57.1%, 37.9%, 32.4%, and 28.5%, respectively (57). Moreover, survival rates with native liver decreased as the age at surgery increased from <45 to 90 days. The investigators in this study estimated that if every patient with BA underwent the Kasai operation before 46 days of age, 5.7% of all liver transplantations performed annually in France in patients younger than 16 years could be avoided. These studies highlight the importance of early detection of cholestasis by providers that can improve outcomes (57). These also indicate a need for unbiased screening for cholestasis and BA, perhaps via yet-to-be discovered newborn screening or the application of stool color cards as successfully used in Taiwan (65).

Non-BA Etiologies of Neonatal Cholestasis

Treatable conditions that can present with cholestatic jaundice include bacterial sepsis, galactosemia, tyrosinemia, panhypopituitarism, bile acid synthetic defects, or obstructive gallstones. These infants often appear acutely ill and early diagnosis will enable timely initiation of directed treatment. Conversely, infants with BA usually appear otherwise healthy and grow normally which may deceive the parent or physician into believing that the jaundice is physiologic or caused by breast-feeding (4). It is important to note that medical management and optimization of nutrition to prevent complications of neonatal cholestasis is beneficial even when specific treatment is not available or curative. The differential diagnoses include a variety of anatomic, infectious, autoimmune, genetic, metabolic, and congenital conditions. This list is not meant to be exhaustive but rather an overview to help orient the reader (see Table 1).

EVALUATION OF THE JAUNDICED INFANT

Jaundice or icterus is clinically evident when the total serum bilirubin level exceeds 2.5 to 3.0 mg/dL (42–51 μ mol/L). Visual determinations of bilirubin levels are inherently problematic.

Several studies confirm the inability of even experienced caregivers to accurately estimate an infant's total serum bilirubin level (66) and this visual assessment cannot determine if the jaundice is due to indirect or direct hyperbilirubinemia. The most important initial step in evaluating a jaundiced infant is measuring serum total and direct (or conjugated) bilirubin. Jaundice at 2 weeks of age is a relatively common finding, observed in 2.4% to 15% of newborns (67,68); however, it should alert the provider of the possibility of cholestasis, although testing of all jaundiced newborns at the 2-week visit will detect cholestasis in relatively few (4). Providers have several options: the most direct is to test serum for total and direct bilirubin at the 2-week visit (or if concerned at any age), but in the absence of any significant "red flags," the infants can follow one of several paths. These "Flags" are detailed in Tables 2 and 3 (69).

If the 2-week-old infant is breast-fed and has a normal physical examination, no history of dark urine or acholic stool, another option is to see the infant back for follow-up in 1 week according to local practice and caregiver/parental comfort with the plan. If this course is taken, and the jaundice persists at 3 weeks of age, laboratory evaluation is recommended (4). If a 2-week-old icteric infant is bottle-fed then fractionation of bilirubin is recommended. If the infant's first visit is at 4 weeks of age as is common practice in many European countries, then any jaundiced infant should be investigated promptly by measurement of total and direct bilirubin. The actual age of the infant when measurement of a fractionated bilirubin is performed is dependent upon several factors and not meant to be proscribed—but practically the measurement should coincide with the clinical status of the infant in the context of accepted local practice. The earlier measurements of fractionated bilirubin are performed, the earlier a diagnosis of cholestasis can be made or excluded and thus help direct optimal and timely clinical care plans.

The most commonly used laboratory determination, the diazo or van den Bergh method, does not specifically measure conjugated bilirubin but reports direct bilirubin, which includes both conjugated bilirubin and delta bilirubin (conjugated bilirubin covalently bound to albumin). For methodological reasons, the higher the total bilirubin (TB) (even if nearly all unconjugated bilirubin) the higher the reported direct bilirubin; hence, specific measurements of conjugated bilirubin are optimal if available (70,71). Because canalicular excretion of bilirubin can be rate-limiting to overall clearance, infants with elevated unconjugated bilirubin may retain some conjugated bilirubin, but this is variable because of the distinct canalicular transporters for conjugated bilirubin (Abcc2) and bile acids (Abcb11), and their differential expression in the setting of cholestasis and age. Therefore, in the presence of elevated TB, direct/conjugated bilirubin levels are considered abnormal when values are >1.0 mg/dL (17 μ mol/L) regardless of the TB (72). Thus, for this guideline, an abnormal direct/conjugated bilirubin is defined as a serum value >1.0 mg/dL (17 μ mol/L), because it is physiologically and clinically complex to consider incorporating consideration of whether or not the direct fraction exceeds 20% of the TB level as mentioned in some publications (4,73).

In a healthy newborn baby with indirect/unconjugated hyperbilirubinemia, the most common causes of jaundice are physiologic jaundice and breast milk jaundice. Both are self-limited maturational disorders characterized by an elevation of serum indirect/unconjugated bilirubin. Infants who are breast-fed are more susceptible to neonatal jaundice because maternal milk contains β -glucuronidase that breaks down conjugated bilirubin to form unconjugated bilirubin and hence increases the enterohepatic circulation of bilirubin (4,74,75). Expressed breast milk also contains factors that may inhibit the conjugating enzyme in hepatocytes (76).

TABLE 2. Parameters of clinical interest in the history of the cholestatic infant

Family history	
Consanguinity	Increased risk of autosomal recessive disorders
Neonatal cholestasis in the parents or siblings	Cystic fibrosis, α -1-antitrypsin deficiency, progressive familial intrahepatic cholestasis, Alagille syndrome are all genetic conditions causing neonatal cholestasis
History of repeated fetal loss or early demise	Gestational alloimmune liver disease
Spherocytosis and other hemolytic diseases	Known to aggravate conjugated hyperbilirubinemia
Prenatal history	
Prenatal ultrasonography findings	Presence of choledochal cyst, cholelithiasis, bowel anomalies or concern for syndrome
Cholestasis of pregnancy	May be seen in heterozygotes for <i>PFIC</i> gene mutations; mitochondrial disorder
Acute fatty liver of pregnancy	Neonatal long-chain 3-hydroxyacyl-coenzyme A dehydrogenase (LCHAD) deficiency
Maternal infections	TORCH infections
Infant history	
Gestational age	Prematurity as a risk factor for neonatal hepatitis
SGA	Increased risk of neonatal cholestasis, congenital infections
Alloimmune hemolysis; glucose-6-P-dehydrogenase deficiency; hydrops fetalis	Increased risk of neonatal cholestasis
Neonatal infection	Urinary tract infection, sepsis related cholestasis, CMV, HIV, syphilis, etc
Newborn screen	Panhypopituitarism galactosemia, fatty acid oxidation defects, cystic fibrosis
Source of nutrition: breast milk, formula, PN	Galactosemia, hereditary fructose intolerance, PN-associated liver disease
Growth	Genetic and metabolic disease
Vision	Septo-optic dysplasia
Hearing	PFIC1, TJP2
Vomiting	Metabolic disease, bowel obstruction, and pyloric stenosis
Stooling	Delayed stooling: CF, panhypopituitarism; diarrhea: infection, metabolic disease
Stool color	Acholic stools: cholestasis, biliary obstruction
Urine characteristics: smell and color	Dark urine (conjugated hyperbilirubinemia), metabolic disease
Excessive bleeding	May indicate coagulopathy, vitamin K deficiency
Disposition: irritability, lethargy	Metabolic disease or sepsis, panhypopituitarism
Abdominal surgery	Necrotizing enterocolitis, intestinal atresia

CF = cystic fibrosis; CMV = cytomegalovirus; HIV = human immunodeficiency virus; PFIC = progressive familial intrahepatic cholestasis; PN = parenteral nutrition; TJP = tight-junction protein; TORCH = Toxoplasma gondii, other viruses, rubella, cytomegalovirus, and herpes simplex virus.

Please refer to the American Academy of Pediatrics guidelines for the management of unconjugated hyperbilirubinemia in the newborn infant 35 or more weeks of gestation (77).

Recommendations:

1. Any formula-fed infant noted to be jaundiced after 2 weeks of age should be evaluated for cholestasis with measurement of total and conjugated (direct) serum bilirubin (1A). Depending upon local practice, breast-fed babies that appear otherwise

well may be followed clinically until 3 weeks of age, at which time if they appear icteric should then undergo serum evaluation of total and conjugated (direct) serum bilirubin.

2. Measurements of serum bilirubin should always be fractionated into unconjugated (indirect) or conjugated (direct) hyperbilirubinemia (1A).
3. Conjugated (direct) hyperbilirubinemia (>1.0 mg/dL, 17 μ mol/L) is considered pathological and warrants diagnostic evaluation (1A).

TABLE 3. Physical findings in children with neonatal cholestasis

Assessment of general health	Ill appearance may indicate infection or metabolic disease, infants with biliary atresia typically appear well
General appearance	Dysmorphic features: Alagille syndrome in the neonate rarely exhibits characteristic facial appearance with a broad nasal bridge, triangular facies, and deep-set eyes. Typical facial features may appear at around 6 months of age, but are often nonspecific (69)
Vision/slit lamp examination	
Hearing	Congenital infection, storage disease, septo-optic dysplasia, posterior embryotoxon, cataracts
Congenital infections, PFIC1, TJP2, mitochondrial	
Cardiac examination: murmur, signs of heart failure	Congenital heart disease: Alagille syndrome, biliary atresia splenic malformation syndrome
Abdominal examination	Presence of ascites; abdominal wall veins, liver size and consistency, spleen size and consistency (or absence thereof), abdominal masses, umbilical hernia
Stool examination (crucial—the primary physician should make every effort to view stool pigment)	Acholic or hypopigmented stools suggest cholestasis or biliary obstruction
Neurologic	Note overall vigor and tone

PFIC = progressive familial intrahepatic cholestasis; TJP = tight-junction protein.

HISTORY

Obtaining a detailed prenatal and infant history is fundamental and should include details of the neonatal screening and any medication including vitamin K supplementation. Details of feeding history should be noted as well as the timing of the first bowel movement, because delayed passage of meconium can be seen in patients with cystic fibrosis (CF). The history should systematically collect information about the onset of jaundice, changes in stool pigmentation, and urine color. It is important to identify history of pale or acholic stools and it is highly recommended to observe the stool pigment (see below). It is well recognized that parents and health care professionals assess stool pigmentation subjectively and abnormally pale stools are frequently misinterpreted as normal. Acholic stools were correctly identified only by 63% of health care providers (78). Stool color charts may be helpful in review of history and ascertaining lack of pigmentation of stools in children with suspected liver disease. In Taiwan, use of a stool color card proved to be effective with 95.2% sensitivity for pale stools (79). A large prospective cohort study using home-based screening for BA with a stool card proved cost effective in Canada (80). Use of the stool card has been piloted in some European countries, such as Switzerland (81) but has not been systematically implemented across the United States or Europe. Many efforts are being investigated to increase awareness and recognition of acholic stool.

In addition, the common intersection of prematurity, inability to advance enteral feedings, and use of prolonged soy lipid-based PN leads to cholestasis, commonly known as parenteral nutrition-associated cholestasis (PNAC) (82). This is a major confounder in the evaluation of the cholestatic infant, and it is often worthwhile for caregivers to note the timing and initiation of PN in relation to serial measurements of fractionated bilirubin levels, especially if direct hyperbilirubinemia precedes the initiation of PN.

Details in the family history including previous and current pregnancy such as miscarriages, pruritus, or overt liver dysfunction in maternal history should be noted; history of maternal fever, rash, adenopathy, or medication intake can be helpful. The family history should not only focus on known liver conditions but also on hemolysis and/or cardiac and vascular anomalies. A detailed overview of noteworthy features is given in Tables 2 and 3.

PHYSICAL EXAMINATION

The clinician performing a physical examination should not only focus on the abdomen but should also consider extrahepatic signs, such as: dysmorphic features, poor growth, dermatologic, neurologic, or pulmonary symptoms (Table 3). Palpation of the abdomen may reveal firm hepatomegaly suspicious for the diagnosis of BA, often with a prominent middle or left lobe. Splenomegaly in BA appears after the newborn period, and if present at a young age of 2 to 4 weeks should point toward other diseases such as storage or hematologic disorders. Cardiac examination is the key, as discovery of a murmur may suggest ALGS or cardiac anomalies associated with BA (eg, septal defects). For a variety of causes, right heart failure may lead to impaired hepatic venous outflow, hepatomegaly, and cholestasis. Hypoplastic (male) genitalia may be a feature of panhypopituitarism, but normal genitalia does not exclude this condition. Confirming whether the infant can visually fix and follow is helpful to rule out septo-optic dysplasia, but often cross-sectional brain imaging is required for this diagnosis (83,84). Direct observation of urine color, and most importantly stool color, is a necessary component of the assessment of the jaundiced infant, as acholic stools and dark urine often indicates the presence of cholestasis and conjugated hyperbilirubinemia. It is important to

note that there are no findings obtained by a careful history or a detailed physical examination that are unique to BA patients.

Recommendations:

4. *A thorough physical examination is crucial to the proper evaluation of the jaundiced infant. Attention to hepatomegaly, splenomegaly, and ill appearance warrants special considerations (1A).*
5. *Direct visualization of stool pigment is a key aspect of a complete evaluation of the jaundiced infant (1A).*

DIAGNOSTIC EVALUATION

This section is devoted to the diagnostic approach to the infant with cholestasis. In addition to laboratory studies, imaging and liver histopathology are important to evaluate for bile duct patency because cholestatic infants must be evaluated promptly to exclude treatable surgical conditions. As noted above, performance of the Kasai HPE for BA is much less likely to benefit infants if performed after 3 months of age (85), hence the importance of an expedient and efficient evaluation.

LABORATORY EVALUATION

During the evaluation of the infant with cholestasis, laboratory investigations will help define the etiology, the severity of the liver disease and detect treatable conditions.

A critical and important initial blood test is the measurement of serum conjugated (direct) bilirubin (DB), which, if elevated, is a reliable laboratory indicator of cholestasis at this age. Accompanying evaluation of DB levels are standard biochemical and synthetic liver tests to assess the severity of the liver disease to include TB, alanine aminotransferase (ALT), aspartate aminotransferase (AST), alkaline phosphatase (AP), gamma glutamyl transpeptidase (GGTP), prothrombin time (PT) with the international normalized ratio (INR), glucose, and albumin. An elevated serum AST without substantial increase in ALT, TB, or DB may point to a hematologic or muscular process, because AST is an enzyme present in red blood cells and myocytes. GGTP value is typically higher in neonates than older children (86) and is generally elevated during cholestasis (87). Some cholestatic diseases, however, present with normal or low GGTP, including progressive familial intrahepatic cholestasis (PFIC) type 1 (ATP8B1 deficiency) and 2 (ABCB11 deficiency), bile acid synthesis disorders (BASDs) and tight-junction protein (TJP) type 2 deficiency (32,88). Other conditions including ALGS, PFIC3 (due to ABCB4 deficiency), and often, but not always, BA frequently present with a high GGTP. Serum AP levels are generally less helpful than serum GGTP in the evaluation of cholestatic infants since the normal range of serum AP levels varies greatly in growing infants. Bacterial cultures of blood, urine, and other fluids should be obtained as dictated by the clinical assessment. Severe coagulopathy unresponsive to parenteral vitamin K administration and out of proportion to the liver injury may indicate gestational alloimmune liver disease, metabolic disease, or sepsis. When evaluating a patient with cholestasis, it is crucial to review the standard local newborn screening as many diseases that cause cholestasis are tested such as hypothyroidism, galactosemia, tyrosinemia, and CF. Some countries have extended newborn screens that can be performed upon request.

The minimum evaluation for any health care professional encountering an infant with jaundice present after the age of 14 days should include a full history including family history and gestational history of the mother, physical examination, inspection of stool color, and obtaining a fractionated bilirubin measurement. When cholestasis is suspected, expedited focused

TABLE 4. Targeted investigations of the persistently cholestatic infant

<p>Tier 1: Aim to evaluate after cholestasis has been established in order to both identify treatable disorder as well as to define the severity of the liver involvement</p> <p>Blood—CBC + differential, INR, AST, ALT, AP, GGTP, TB, DB (or conjugated bilirubin), albumin and glucose. Check α-1-antitrypsin phenotype (Pi typing) and level, TSH, T4 if newborn screen results not readily available</p> <p>Urine—urinalysis, culture, reducing substances (rule out galactosemia)</p> <p>Consider bacterial cultures of blood, urine and other fluids especially if infant is clinically ill.</p> <p>Verify results of treatable disorders (such as galactosemia and hypothyroidism) from newborn screen</p> <p>Obtain fasting ultrasound</p> <p>Tier 2: Aim to complete a targeted evaluation in concert with pediatric gastroenterologist/hepatologist</p> <p>General—TSH and T4 values, serum bile acids, cortisol</p> <p>Consideration of specific etiologies</p> <p>Metabolic—serum ammonia, lactate level, cholesterol, red blood cell galactose-1-phosphate uridylyltransferase, urine for succinylacetone and organic acids. Consider urine for bile salt species profiling</p> <p>ID—direct nucleic acid testing via PCR for CMV, HSV, listeria</p> <p>Genetics—in discussion with pediatric gastroenterologist/hepatologist, with a low threshold for gene panels or exome sequencing</p> <p>Sweat chloride analysis (serum immunoreactive trypsinogen level or CFTR genetic testing) as appropriate</p> <p>Imaging</p> <p>CXR—lung and heart disease</p> <p>Spine—spinal abnormalities (such as butterfly vertebrae)</p> <p>Echocardiogram—evaluating for cardiac anomalies seen in Alagille syndrome</p> <p>Cholangiogram</p> <p>Liver biopsy (timing and approach will vary according to institution and expertise)</p> <p>Consideration for consultations</p> <p>Ophthalmology</p> <p>Metabolic/Genetic (consider when to involve, especially when there is consideration for gene panels or whole exome sequencing)</p> <p>Cardiology/ECHO (if murmur present or has hypoxia, poor cardiac function)</p> <p>General pediatric surgery</p> <p>Nutrition/dietician</p>

ALT = alanine aminotransferase; AP = alkaline phosphatase; AST = aspartate aminotransferase; CBC = complete blood count; CFTR = cystic fibrosis trans-membrane receptor; DB = conjugated (direct) bilirubin; ECHO = echocardiogram; GGTP = gamma-glutamyl transferase; HSV = herpes simplex virus; ID = infectious diseases; INR = international normalized ratio; PCR = polymerase chain reaction; TB = total bilirubin; TSH = thyroid-stimulating hormone.

investigations (Table 4, Tier 1) are recommended. A disciplined and stepwise approach to the infant with confirmed cholestasis in concert with a pediatric gastroenterologist/hepatologist can then follow in the ordering of laboratory tests appropriate in each situation, and enabling a targeted workup (Table 4, Tier 2). Some local variation is unavoidable because of available expertise (Table 4). “Red flags,” which mandate evaluation for BA include acholic stools, high GGT cholestasis without alternative etiology, and abnormal or absence of gallbladder on ultrasound. Conditions that mimic BA such as α -1-antitrypsin deficiency, CF, ALGS, and others should be excluded early on in the evaluation process.

DIAGNOSTIC IMAGING

A fasting abdominal ultrasound is an easy and noninvasive first diagnostic imaging investigation to assess for visible obstructing lesions of the biliary tree or identification of choledochal cyst, and to assess for signs of advanced liver disease or vascular and/or splenic abnormalities (89). Several hepatic sonographic parameters such as the triangular cord sign, abnormal gall bladder morphology, lack of gall bladder contraction after oral feeding, nonvisualization of the common bile duct, hepatic artery diameter, and hepatic artery diameter to portal vein diameter ratio, subcapsular blood flow have been suggested to aid in the diagnosis of BA (90–94), although none can singularly confirm a diagnosis of BA. It is useful, however, to know that many, but not all, infants with BA have a small or undetectable gall bladder (95). In addition, findings such as abdominal heterotaxy, midline liver, polysplenia, asplenia, and preduodenal portal vein increase the concern for BA with malformations. It is imperative to remember that a normal ultrasonography (US), however, does not rule out nonsyndromic BA.

Hepatobiliary scintigraphy (HBS) has been used to confirm biliary tract patency, but can be limited by its low specificity (range 68.5%–72.2%), and a nondiagnostic result when bile flow is limited as a result of a wide variety of etiologies (96). Patients with interlobular bile duct paucity, idiopathic neonatal hepatitis, low birth weight, and those on PN may have nonexcreting scans (97). This limited accuracy of HBS in differentiating idiopathic neonatal hepatitis from BA was demonstrated in a study by Yang et al (98) in which magnetic resonance cholangiopancreatography (MRCP), US, technetium 99m-iminodiacetic acid HBS, HBS single photon emission computed tomography (HBS SPECT), and liver biopsy were compared. The goal of this study of 69 infants with cholestatic jaundice and a final diagnosis of idiopathic neonatal hepatitis, and BA was to determine which modality may help distinguish between these 2 diagnoses. All of the 69 infants underwent MRCP, US, HBS, SPECT, and liver biopsy. HBS had sensitivity and a specificity of 88.2% and 45.7% for detecting BA, respectively, with an accuracy of 66.7%. Scintigraphy adds little to the routine evaluation of the cholestatic infant, but may be of value in determining patency of the biliary tract, thereby excluding BA. In this study, liver biopsy had the highest sensitivity in detecting BA at 100%, a specificity of 94.3% and an accuracy rate of 96.9%.

A recent meta-analysis addressing the utility of HBS yielded a pooled sensitivity of 98.7% (98.1–99.2%) and a specificity of 70.4% (range 68.5%–72.2%) of a nondraining HBS for excluding BA. This shows that false negative results (excretion of the tracer into the bowel despite BA) are extremely rare (96). Limited reports describe infants with apparently initially excreting HBS and a subsequent diagnosis of BA, although the technical limitations of the study may have been a factor in its utility (100,101).

Many clinicians and radiologists administer phenobarbital for 5 days before the study, in an attempt to enhance biliary excretion of the isotope and increase its discriminatory value (99), which often unnecessarily delays the diagnosis of BA and the necessary HPE (57,89). Further work is necessary to assess the utility of premedication for HBS (100,101).

Despite the use of the diagnostic tests described above, it is still not easy to discriminate between BA and other causes of neonatal cholestasis. As detection of patency of the extrahepatic biliary tree is the primary goal of diagnostic evaluations in infants with cholestasis, the role of endoscopic retrograde cholangiopancreatography (ERCP) in the diagnosis of BA has been studied by various groups (102,103). Although ERCP has proved effective with high positive and negative predictive values for BA (sensitivity 86%–100%, specificity 87%–94%, positive predictive value 88%–96%, negative predictive value 100%) (102,104), ERCP requires an

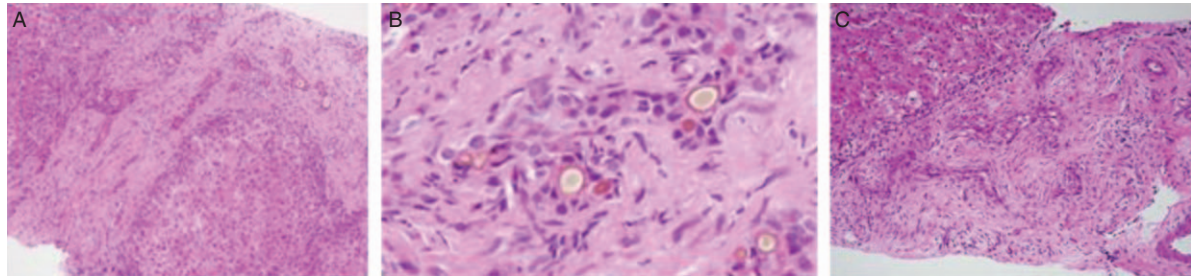


FIGURE 1. Liver biopsies from 2 individuals with biliary atresia (BA). A, H&E stain of a 3-month-old infant with BA, highlighting peribiliary fibrosis, ductular proliferation, bile duct plugs. B, High-power view of (A), emphasizing bile duct plugs and damaged cholangioles. C, Liver biopsy from a 6-week-old infant with BA, highlighting peribiliary fibrosis, disordered cholangiocyte profiles and scattered inflammatory infiltrate.

experienced endoscopist, specific infant endoscopy equipment not readily available at many centers, and a general anesthetic. The superiority of ERCP compared with other types of cholangiograms has not been demonstrated (105).

A few reports have suggested that MRCP is a well-established noninvasive modality for visualizing the biliary system, including the first-order branches of the intrahepatic bile ducts, extrahepatic bile ducts, and gallbladder (106). The diagnostic value of 3-dimensional MRCP for BA in a large cohort of cholestatic infants and neonates was therefore recently evaluated, with a reported specificity of 36% and sensitivity of 99% (107).

Recent case series have documented the technique and feasibility of percutaneous transhepatic cholecysto-cholangiography (PTCC) to exclude BA (108,109). In the largest series reported (109), PTCC was performed in combination with simultaneous liver biopsy. Although this was reported to effectively exclude BA with a lower negative laparotomy rate, there is a genuine concern that PTCC may be used unnecessarily in infants in whom a liver biopsy alone would have excluded biliary obstruction. Moreover, a PTCC may not be able to demonstrate retrograde patency of the biliary tree into the liver and may miss proximal obstruction, thereby obviating a surgical cholangiogram in a patient who may have BA. Importantly, the specificity of liver biopsy in diagnosing biliary obstruction in this case series was much lower than frequently reported values (89). Taken together, the use of MRCP, ERCP, and PTCC has a limited role in the general guidance to caregivers toward diagnosing BA in the present era.

HISTOPATHOLOGY

Liver biopsy often remains the cornerstone of the diagnostic workup of infants with cholestatic jaundice as interpretation by an experienced pathologist will provide the correct diagnosis in 90% to 95% of cases and avoid unnecessary surgery in patients with intrahepatic disease (89,110,111). Pathologists participating in the National Institutes of Health–supported Biliary Atresia Research Consortium (BARC, currently the ChiLDReN consortium [childrennetwork.org]) have developed and evaluated a standardized system for reporting of liver biopsies from infants with cholestasis. Overall, the pathologists diagnosis of obstruction in clinically proven cases of BA ranged from 79% to 98%, with a positive predictive value of 90.7%. The group diagnosed BA with a high level of sensitivity and identified infants with biliary obstruction with reasonable interobserver agreement (110). Of note, a diagnosis of BA or obstruction other than BA was made in 14 of 15 cases of PN-associated liver disease and all 3 cases of α -1-antitrypsin deficiency. Conversely, a majority of the pathologists favored a nonobstructive diagnosis in the 3 cases of progressive familial intrahepatic cholestasis and 1 case of bile acid synthetic disorder. In cases of idiopathic neonatal hepatitis, the percentage of

cases read by each pathologist as nonobstructive ranged from 57% to 93%. The classic histologic features of biliary obstruction are bile duct proliferation, bile plugs, portal or perilobular fibrosis, and edema, with preservation of the basic hepatic lobular architecture (Fig. 1). In idiopathic neonatal hepatitis, lobular disarray and inflammatory cells are seen within the portal areas, and the bile ductules show little or no alteration (Fig. 2). Giant cell transformation can be seen in 20% to 50% of patients with BA (112,113); however, it is not as prominent as that seen in idiopathic neonatal hepatitis (111). Some disorders that can mimic BA histologically are PN-associated cholestasis, CF and α -1-antitrypsin deficiency. They may show variable ductular reaction and may be impossible to distinguish from BA without clinical data (110,111). It is however important to recognize that the earliest histologic changes of BA may be relatively nonspecific, and biopsies performed too early in the course of the disease may result in a falsely negative diagnosis (110,111,114).

The proper use of liver biopsy therefore remains a central component of the diagnostic evaluation of infants with cholestatic jaundice as the differential diagnosis is perhaps the broadest of any age group and encompasses obstructive as well as, more commonly, nonobstructive disorders. In addition to its role in diagnosis, the liver biopsy may also reveal histologic features of significant prognostic value, such as the degree of fibrosis, which may help predict outcome following HPE and the decision to proceed with HPE (115,116). Although sonography-guided percutaneous core liver biopsy is considered to be a safe and effective procedure in children with a low complication rate of 1.7% (117), the overall

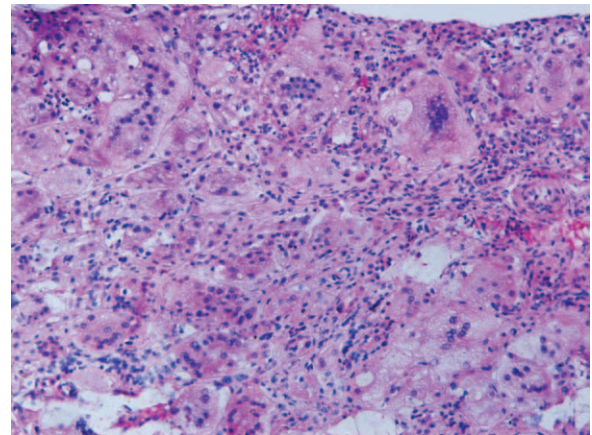


FIGURE 2. Idiopathic neonatal hepatitis: lobular disarray with giant cell transformation.

complication rate in infants, even in the hands of an experienced physician, was reported in 1 small series to be 4.6% (3/65 infants had a bleeding event that required an intervention) (118).

Recommendations:

6. *The abdominal ultrasound is useful in excluding choledochal cyst or gallstone disease causing extrahepatic bile duct obstruction. It may demonstrate an absent or abnormal gallbladder, or other features suggestive, but not diagnostic, of BA (1A).*
7. *Limited specificity precludes the use of the HBS scan as a stand-alone test in making a definitive diagnosis of BA (1B). Definitively demonstrated bile flow by selective use of HBS may be of value in excluding BA (1B).*
8. *Limited specificity of MRCP, ERCP, PTCC provides a limited role in the general guidance to caregivers toward diagnosing BA in the present era.*
9. *In the hands of an experienced pediatric pathologist, histopathological findings of bile duct proliferation, bile plugs, and fibrosis in an appropriately timed liver biopsy is the most supportive test in the evaluation of the infant with protracted conjugated hyperbilirubinemia (1B). Diseases other than BA that cause cholestasis can be determined via histologic examination of the liver.*

INTRAOPERATIVE CHOLANGIOGRAM

The intraoperative cholangiogram and histologic examination of the duct remnant is considered the criterion standard to diagnose BA (89,119,120). Interestingly, in up to 20% of cases, even a cholangiogram can suggest an incorrect diagnosis—cases with a hypoplastic biliary tree, ALGS and CF being confounding diagnostic conditions (121). Hence, preoperative testing for CF and ALGS is helpful in assisting in the interpretation of the cholangiogram and decreasing false-positive results. Intraoperative cholangiogram is typically performed after biliary obstruction is suggested in a liver biopsy or if sufficient clinical indications suggest direct referral to the surgeon for the procedure. If BA is confirmed (ie, nonvisualization of a patent extrahepatic biliary tree), a (Kasai) HPE is usually performed immediately, unless there are considerations made by the team that it would be in the best interest of the infant to proceed to transplant evaluation and not undergo the HPE. No effective diagnostic tools currently determine whether a patient should proceed to HPE, and it is up to the team of specialists to determine whether the patient would be better served without the HPE.

It is important to note that diagnostic evaluation to rule out BA should be expedited especially when the infant is above 6 weeks of age. The younger the age at diagnosis of BA, the more likely that the HPE will be successful (at least in the short term, see above).

Recommendation:

10. *Evaluation by intraoperative cholangiogram and histological examination of the duct remnant is considered the gold standard to diagnose biliary atresia (1A).*

OTHER CAUSES OF NEONATAL CHOLESTASIS

Structural Abnormalities Choledochal Cyst

Patients with choledochal cysts present with laboratory findings suggestive of cholestasis. Sometimes patients have cholangitis and present with fever, elevation of the GGTP, and direct hyperbilirubinemia. Ultrasonography can often differentiate

between choledochal cyst and BA as the bile ducts are typically dilated or cystic and the gallbladder is not atretic (122). A diagnosis of choledochal cyst in a cholestatic neonate should, however, always prompt careful evaluation for BA (atresia of the distal common bile duct accompanied by cystic dilation: type 1 BA). In a few studies, cyst size appeared to decrease between prenatal diagnosis and birth in patients with BA but did not change in patients with choledochal cyst (123,124). Moreover, choledochal cysts can coincide with BA.

Select Genetic/Metabolic Disorders

Alagille Syndrome

ALGS is an autosomal dominant multisystem disorder characterized by paucity of interlobular ducts. It is the most common form of familial intrahepatic cholestasis occurring in 1 in 30,000 live births. Diagnosis is usually made by the clinical findings, laboratory, and diagnostic evaluation, and confirmed by sequencing of *JAG1* and *NOTCH2* genes, with mutations found in 95% and 5% of patients with ALGS, respectively (125). Clinical criteria for the diagnosis of ALGS includes ductopenia on liver biopsy and a characteristic Alagille facies (broad forehead, small pointy chin, but is often difficult to recognize in the neonatal period), posterior embryotoxon, butterfly vertebrae, renal disease, and a variety of developmental cardiac defects (most commonly peripheral pulmonic stenosis) (126) or tetralogy of Fallot. Direct hyperbilirubinemia and occasional acholic stool that may improve with age can be present (126). Serum ALT and bile acids are usually elevated. The GGTP is an important test in orienting the practitioner toward this disorder because it is often disproportionately elevated, sometimes up to 20 times the normal value. Practitioners are encouraged to evaluate for associated clinical abnormalities found in patients with ALGS when the diagnosis is suspected either on liver biopsy or by characteristic facies, before proceeding with intraoperative cholangiogram.

Cystic Fibrosis

Some infants with CF present with abnormal liver tests, suggestive of biliary obstruction because of the presence of abnormal bile with plugging of the common bile duct (127). Checking the newborn screen for immunoreactive trypsinogen is helpful. The criterion standard remains sequencing of the cystic fibrosis transmembrane receptor (*CFTR*) gene or a positive sweat chloride test, but this is sometimes not possible as infants may not produce enough sweat (128).

Progressive Familial Intrahepatic Cholestasis

PFIC is a group of unrelated monogenic disorders in which mutations in one of the genes involved in canalicular hepatobiliary transport results in progressive cholestasis and liver injury (Table 1). Patients with PFIC1–3 have a significant elevation of the total serum bile acids. A important clinical finding in individuals with PFIC types 1 and 2 (due to *ATP8B1* and *ABCB11* gene deficiencies, respectively) is the presence of a normal or low GGTP out of proportion to the degree of cholestasis (129), associated with normal or low serum cholesterol. Some of the patients with normal GGTP PFIC were found to have a mutation in the *TJP2* gene, which causes failure of protein localization and disruption of tight-junction structure, leading to severe cholestatic liver disease that can present early in life (32). Patients with PFIC type 3 (*ABCB4* deficiency) have elevated GGTP and a variable degree of cholestasis—typically presenting later in infancy or in early childhood (130,131).

Alpha-1-Antitrypsin Deficiency

This is the most common cause of inherited neonatal cholestasis. Approximately 10% to 15% of neonates with this condition will present with cholestasis and a combined picture of hepatocellular injury and obstruction with elevation of the ALT, AST, GGTP, and AP. The cholestasis is usually severe and the presence of acholic stools may present a challenge because of the resemblance to BA. Although some patients may develop cirrhosis early on, jaundice clears in most patients by 4 months of age (132). The diagnosis is made based on the phenotype (normal: MM; abnormal: ZZ or SZ; heterozygous: MZ, MS) (133). It is important to note that neonates with ZZ phenotype may have no biliary excretion on scintigraphic studies (134) and liver biopsy may appear obstructive (110). Hence, obtaining the phenotype early in the evaluation of cholestasis could avoid unnecessary biopsy in this condition. Checking for serum levels of α -1-antitrypsin could be helpful if used along with the phenotype to distinguish patients who are homozygous for the Z allele or SZ compound heterozygotes, both of whom may develop liver disease. Patients with MZ, MS, SZ, or homozygous SS A1 phenotypes do not present with neonatal cholestasis unless associated with another cause (135). Serum α -1-antitrypsin concentrations alone are an insufficient test since α -1-antitrypsin is an acute phase reactant and during illnesses may be elevated (136,137). Of note, there have been few case reports of the concurrence of α -1-antitrypsin deficiency and BA (138,139).

Bile Acid Synthesis Disorders

More than 14 enzymes are involved in the synthesis of bile acids from cholesterol precursor molecules. Bile acid synthetic disorders (BASDs) are rare, but in many cases are treatable forms of cholestasis. Not all of the infants with the genetic abnormalities leading to BASD present with cholestasis and jaundice; some may have a more indolent presentation later during childhood. These conditions often present with normal or low GGTP. Total serum bile acids are usually low, in contrast to other cholestatic disorders. Fast atom bombardment mass spectrometry of urine should be considered as a screening tool before starting ursodeoxycholic acid; it is possible to perform rapid diagnosis of potential inborn errors in bile acid synthesis from urinary bile acid analysis. Molecular techniques then identify the specific mutations in genes encoding the enzymes responsible for bile acid synthesis (25,26,140). Treatment with the end products of bile acid synthesis, cholic acid and chenodeoxycholic acid, is often curative for several of the BASDs, prompting directed evaluations.

Select Inborn Errors of Metabolism

A group of metabolic conditions classified as inborn errors of metabolism can present with cholestasis, and as in the other cholestatic disorders, the practitioner has to have a high index of suspicion. The initial laboratory testing recommended when the clinical picture is compatible with an inborn errors of metabolism includes blood gases, electrolytes, glucose, ammonia, uric acid, lactic acid, pyruvic acid (L:P ratio), ketone bodies; and in urine, ketone bodies, 2-keto acids, reducing substances, acylglycines, pH; and sulfites (141–144). Newborn screening for galactosemia and tyrosinemia are performed in some countries to identify infants before they are symptomatic. Infants with tyrosinemia can present with mild cholestasis, although more typically present with coagulopathy disproportionate to any biochemical abnormalities (145). Diagnosis via serum fumarylacetoacetate hydrolase enzyme determination or urine succinylacetone is vital in this treatable but life-threatening condition. With the incorporation of gene panels

and exome sequencing, these disorders may have more precise and timely means of genetic investigations in the near future.

Infections

Cytomegalovirus

Cytomegalovirus (CMV) the most common congenital infection, affects 1% to 2% of newborns. Most infected newborns are asymptomatic; unfortunately 5% to 10% of the patients have a myriad of clinical symptoms that include low birth weight, microcephaly, periventricular calcifications, chorioretinitis, and deafness. Hepatosplenomegaly and direct hyperbilirubinemia are the most prominent liver-related problems (146,147). The diagnosis of congenital CMV is confirmed by culture or PCR from the nasopharynx, saliva, blood, or urine soon after birth. Urine CMV culture or CMV-DNA detection by PCR is presently used for the diagnosis (148,149). The immunoglobulin M (IgM) CMV-specific antibodies can be monitored but are of limited value and may be less sensitive. Evidence of recent CMV infection at the time of diagnosis of BA has been reported by multiple investigators, but a role for CMV in the etiology of BA remains unproven (150–152).

Viral Hepatitis A, B, and C

In general, these hepatotropic viruses do not cause neonatal cholestasis. Single case reports document special circumstances where these infections present with neonatal cholestasis. Specific studies for these infectious agents in the evaluation of neonatal cholestasis are generally unwarranted.

Other Infections

Syphilis, rubella, toxoplasmosis, and herpes virus can present with neonatal cholestasis, coagulopathy, and growth restriction. Obtaining a good maternal history and discussing with the obstetrician and neonatal intensive care team about placental abnormalities can help with directing the workup for an infection. Typically, infants with these infections present with jaundice within first 24 hours of life. Congenital syphilis incidence is rising in the United States (153). Urinary tract infections present with cholestasis in the neonatal period and a urine culture should be obtained early on in the diagnostic evaluation of cholestasis (154).

Endocrine Disorders

Thyroid Disorders

Few reports in the pediatric literature describe cholestatic liver disease in infants born to mothers with Graves disease (155). The newborn screen is designed to detect high levels of thyroid-stimulating hormone (TSH); hence, in cases of central hypothyroidism, this can be missed and repeating a blood TSH, free T4, and T3 may be helpful (156,157).

Panhypopituitarism

Pituitary hormones are involved in the regulation of bile synthesis and excretion and bile flow. The neonates with this condition present with elevation of the total and direct bilirubin; they may have hypoglycemia and even shock from adrenal insufficiency. Some infants have associated septo-optic dysplasia and on physical examination will lack the ability to focus or track. Diagnostic evaluation includes TSH, total and free T4, early morning cortisol level, and a brain magnetic resonance imaging. In these patients, a nonfasting ultrasound should be requested as prolonged

fasting can lead to devastating complications related to severe hypoglycemia. The cholestasis resolves with the correction of the pituitary hormone insufficiency (83,84,158–160).

Rare Diseases and Idiopathic Neonatal Cholestasis

The neonatal cholestasis “black box” of unidentified etiologies continues to shrink but is still a substantial group of disorders (131). The identifiable causes of neonatal cholestasis have grown more numerous largely because of application of modern techniques of clinical genetics. Reducing costs and easy access to genetic testing, including exome and genome sequencing, and targeted gene panels, have facilitated diagnosis. Among the most studied causes of neonatal cholestasis in recent years are metabolic diseases and disorders of bile transport and bile acid synthesis. It is, however, important to stress that the meaning of a gene mutation or polymorphism is dependent on clinical context. Advanced sequencing methods promise to further increase the diagnostic yield of genetic approaches. Table 1 summarizes known genetic findings presenting as neonatal cholestasis.

CONCLUSIONS

Cholestatic jaundice in an infant is a typical presenting feature of neonatal liver disease and is frequently clinically confused with the more common prolonged unconjugated hyperbilirubinemia. Identification of infants with cholestasis remains crucial and is in the domain of the primary care provider, generally uncovered with measurement of a serum-fractionated bilirubin. Hence a careful history, thorough physical examination, and fractionation of serum bilirubin are recommended in any infant with jaundice seen after 2 weeks of life. The relative rarity of cholestatic jaundice in contrast to unconjugated hyperbilirubinemia in this age range dictates that many jaundiced infants will be tested to detect those with elevated direct bilirubin levels. Investigation for neonatal cholestasis in these settings is, however, highly beneficial, despite its rarity, because of the gravity of the consequences of missing BA and monogenic diagnoses that have specific, and often life-saving, interventions. This guideline has been developed to assist in this process and is not intended as a substitute for clinical judgment or as a protocol for the care of all infants with cholestasis. Vigilance is crucial in detecting these infants and referring them to a pediatric gastroenterologist or hepatologist who can provide the essential diagnostic and treatment modalities to optimize outcome.

REFERENCES

- Guyatt GH, Oxman AD, Vist GE, et al. GRADE: an emerging consensus on rating quality of evidence and strength of recommendations. *BMJ* 2008;336:924–6.
- Dick MC, Mowat AP. Hepatitis syndrome in infancy—an epidemiological survey with 10 year follow up. *Arch Dis Child* 1985;60:512–6.
- Balistreri WF, Bezerra JA. Whatever happened to “neonatal hepatitis”? *Clin Liver Dis* 2006;10:27–53v.
- Moyer V, Freese DK, Whittington PF, et al. Guideline for the evaluation of cholestatic jaundice in infants: recommendations of the North American Society for Pediatric Gastroenterology, Hepatology and Nutrition. *J Pediatr Gastroenterol Nutr* 2004;39:115–28.
- Li L, Krantz ID, Deng Y, et al. Alagille syndrome is caused by mutations in human Jagged1, which encodes a ligand for Notch1. *Nat Genet* 1997;16:243–51.
- McDaniell R, Warthen DM, Sanchez-Lara PA, et al. NOTCH2 mutations cause Alagille syndrome, a heterogeneous disorder of the notch signaling pathway. *Am J Hum Genet* 2006;79:169–73.
- Ackerlmann MA, Patel PD, Valenti J, et al. Loss of actomyosin regulation in distal arthrogryposis myopathy due to mutant myosin binding protein-C slow. *FASEB J* 2013;27:3217–28.
- Cullinane AR, Straatman-Iwanowska A, Zaucker A, et al. Mutations in VIPAR cause an arthrogryposis, renal dysfunction and cholestasis syndrome phenotype with defects in epithelial polarization. *Nat Genet* 2010;42:303–12.
- Gissen P, Johnson CA, Morgan NV, et al. Mutations in VPS33B, encoding a regulator of SNARE-dependent membrane fusion, cause arthrogryposis-renal dysfunction-cholestasis (ARC) syndrome. *Nat Genet* 2004;36:400–4.
- Bjursell C, Stibler H, Wahlström J, et al. Fine mapping of the gene for carbohydrate-deficient glycoprotein syndrome, type I (CDG1): linkage disequilibrium and founder effect in Scandinavian families. *Genomics* 1997;39:247–53.
- Tan J, Dunn J, Jaeken J, et al. Mutations in the MGAT2 gene controlling complex N-glycan synthesis cause carbohydrate-deficient glycoprotein syndrome type II, an autosomal recessive disease with defective brain development. *Am J Hum Genet* 1996;59:810–7.
- Cutting GR, Kasch LM, Rosenstein BJ, et al. Two patients with cystic fibrosis, nonsense mutations in each cystic fibrosis gene, and mild pulmonary disease. *N Engl J Med* 1990;323:1685–9.
- Cutting GR, Kasch LM, Rosenstein BJ, et al. A cluster of cystic fibrosis mutations in the first nucleotide-binding fold of the cystic fibrosis conductance regulator protein. *Nature* 1990;346:366–9.
- Carroll CJ, Isohanni P, Pöyhönen R, et al. Whole-exome sequencing identifies a mutation in the mitochondrial ribosome protein MRPL44 to underlie mitochondrial infantile cardiomyopathy. *J Med Genet* 2013;50:151–9.
- Holt IJ, Harding AE, Morgan-Hughes JA. Deletions of muscle mitochondrial DNA in patients with mitochondrial myopathies. *Nature* 1988;331:717–9.
- Wallace DC, Zheng XX, Lott MT, et al. Familial mitochondrial encephalomyopathy (MERRF): genetic, pathophysiological, and biochemical characterization of a mitochondrial DNA disease. *Cell* 1988;55:601–10.
- Hadj-Rabia S, Baala L, Vabres P, et al. Claudin-1 gene mutations in neonatal sclerosing cholangitis associated with ichthyosis: a tight junction disease. *Gastroenterology* 2004;127:1386–90.
- Arnell H, Fischler B. Population-based study of incidence and clinical outcome of neonatal cholestasis in patients with Down syndrome. *J Pediatr* 2012;161:899–902.
- Gonzales E, Davit-Spraul A, Baussan C, et al. Liver diseases related to MDR3 (ABCB4) gene deficiency. *Front Biosci (Landmark Ed)* 2009;14:4242–56.
- Kidd VJ, Wallace RB, Itakura K, et al. Alpha 1-antitrypsin deficiency detection by direct analysis of the mutation in the gene. *Nature* 1983;304:230–4.
- Kueppers F, Briscoe WA, Bearn AG. Hereditary deficiency of serum alpha-1-antitrypsin. *Science* 1964;146:1678–9.
- Sharp HL, Bridges RA, Krivit W, et al. Cirrhosis associated with alpha-1-antitrypsin deficiency: a previously unrecognized inherited disorder. *J Lab Clin Med* 1969;73:934–9.
- Talamo RC, Feingold M. Infantile cirrhosis with hereditary alpha 1-antitrypsin deficiency. Clinical improvement in two siblings. *Am J Dis Child* 1973;125:845–7.
- Setchell KD, Schwarz M, O’Connell NC, et al. Identification of a new inborn error in bile acid synthesis: mutation of the oxysterol 7alpha-hydroxylase gene causes severe neonatal liver disease. *J Clin Invest* 1998;102:1690–703.
- Cheng JB, Jacquemin E, Gerhardt M, et al. Molecular genetics of 3beta-hydroxy-Delta5-C27-steroid oxidoreductase deficiency in 16 patients with loss of bile acid synthesis and liver disease. *J Clin Endocrinol Metab* 2003;88:1833–41.
- Schwarz M, Wright AC, Davis DL, et al. The bile acid synthetic gene 3beta-hydroxy-Delta(5)-C(27)-steroid oxidoreductase is mutated in progressive intrahepatic cholestasis. *J Clin Invest* 2000;106:1175–84.
- Falany CN, Johnson MR, Barnes S, et al. Glycine and taurine conjugation of bile acids by a single enzyme. Molecular cloning and expression of human liver bile acid CoA:amino acid N-acyltransferase. *J Biol Chem* 1994;269:19375–9.
- Falany CN, Xie X, Wheeler JB, et al. Molecular cloning and expression of rat liver bile acid CoA ligase. *J Lipid Res* 2002;43:2062–71.

29. Bull LN, van Eijk MJ, Pawlikowska L, et al. A gene encoding a P-type ATPase mutated in two forms of hereditary cholestasis. *Nat Genet* 1998;18:219–24.
30. Strautnieks SS, Bull LN, Knisely AS, et al. A gene encoding a liver-specific ABC transporter is mutated in progressive familial intrahepatic cholestasis. *Nat Genet* 1998;20:233–8.
31. Deleuze JF, Jacquemin E, Dubuisson C, et al. Defect of multidrug-resistance 3 gene expression in a subtype of progressive familial intrahepatic cholestasis. *Hepatology* 1996;23:904–8.
32. Sambrotta M, et al. Mutations in TJP2 cause progressive cholestatic liver disease. *Nat Genet* 2014;46:326–8.
33. Liu LY, Wang XH, Lu Y, et al. Association of variants of ABCB11 with transient neonatal cholestasis. *Pediatr Int* 2013;55:138–44.
34. Tamamori A, Okano Y, Ozaki H, et al. Neonatal intrahepatic cholestasis caused by citrin deficiency: severe hepatic dysfunction in an infant requiring liver transplantation. *Eur J Pediatr* 2002;161:609–13.
35. Kobayashi K, Sinasac DS, Iijima M, et al. The gene mutated in adult-onset type II citrullinaemia encodes a putative mitochondrial carrier protein. *Nat Genet* 1999;22:159–63.
36. Russell A, Levin B, Oberholzer VG, et al. Hyperammonaemia: a new instance of an inborn enzymatic defect of the biosynthesis of urea. *Lancet* 1962;2:699–700.
37. Reichardt JK. Molecular analysis of 11 galactosemia patients. *Nucleic Acids Res* 1991;19:7049–52.
38. Reichardt JK, Packman S, Woo SL. Molecular characterization of two galactosemia mutations: correlation of mutations with highly conserved domains in galactose-1-phosphate uridylyl transferase. *Am J Hum Genet* 1991;49:860–7.
39. Reichardt JK, Woo SL. Molecular basis of galactosemia: mutations and polymorphisms in the gene encoding human galactose-1-phosphate uridylyltransferase. *Proc Natl Acad Sci U S A* 1991;88:2633–7.
40. Phaneuf D, Labelle Y, Bérubé D, et al. Cloning and expression of the cDNA encoding human fumarylacetoacetate hydrolase, the enzyme deficient in hereditary tyrosinemia: assignment of the gene to chromosome 15. *Am J Hum Genet* 1991;48:525–35.
41. Vance JE. Lipid imbalance in the neurological disorder, Niemann-Pick C disease. *FEBS Lett* 2006;580:5518–24.
42. Schiff L, Schubert WK, McAdams AJ, et al. Hepatic cholesterol ester storage disease, a familial disorder. I. Clinical aspects. *Am J Med* 1968;44:538–46.
43. Lauriti G, Zani A, Aufieri R, et al. Incidence, prevention, and treatment of parenteral nutrition-associated cholestasis and intestinal failure-associated liver disease in infants and children: a systematic review. *JPEN J Parenter Enteral Nutr* 2014;38:70–85.
44. Jolin-Dahel K, Ferretti E, Montiveros C, et al. Parenteral nutrition-induced cholestasis in neonates: where does the problem lie? *Gastroenterol Res Pract* 2013;2013:163632.
45. Champion V, Carbajal R, Lozar J, et al. Risk factors for developing transient neonatal cholestasis. *J Pediatr Gastroenterol Nutr* 2012;55:592–8.
46. Chiu CY, Chen PH, Chan CF, et al. Biliary atresia in preterm infants in Taiwan: a nationwide survey. *J Pediatr* 2013;163:100–3e1.
47. Fischler B, Haglund B, Hjern A. A population-based study on the incidence and possible pre- and perinatal etiologic risk factors of biliary atresia. *J Pediatr* 2002;141:217–22.
48. The NS, Honein MA, Caton AR, et al. Risk factors for isolated biliary atresia, National Birth Defects Prevention Study, 1997-2002. *Am J Med Genet A* 2007;143A:2274–84.
49. Schreiber RA, Barker CC, Roberts EA, et al. Biliary atresia: the Canadian experience. *J Pediatr* 2007;151:659–65665 e1.
50. McKiernan PJ, Baker AJ, Kelly DA. The frequency and outcome of biliary atresia in the UK and Ireland. *Lancet* 2000;355:25–9.
51. Schwarz KB, Haber BH, Rosenthal P, et al. Extrahepatic anomalies in infants with biliary atresia: results of a large prospective North American multicenter study. *Hepatology* 2013;58:1724–31.
52. Sokol RJ, Mack C. Etiopathogenesis of biliary atresia. *Semin Liver Dis* 2001;21:517–24.
53. Mack CL. The pathogenesis of biliary atresia: evidence for a virus-induced autoimmune disease. *Semin Liver Dis* 2007;27:233–42.
54. Schreiber RA, Kleinman RE. Genetics, immunology, and biliary atresia: an opening or a diversion? *J Pediatr Gastroenterol Nutr* 1993;16:111–3.
55. Bezerra JA. Potential etiologies of biliary atresia. *Pediatr Transplant* 2005;9:646–51.
56. Harpavat S, Finegold MJ, Karpen SJ. Patients with biliary atresia have elevated direct/conjugated bilirubin levels shortly after birth. *Pediatrics* 2011;128:e1428–33.
57. Serinet MO, Wildhaber BE, Broué P, et al. Impact of age at Kasai operation on its results in late childhood and adolescence: a rational basis for biliary atresia screening. *Pediatrics* 2009;123:1280–6.
58. Shneider BL, Brown MB, Haber B, et al. A multicenter study of the outcome of biliary atresia in the United States, 1997 to 2000. *J Pediatr* 2006;148:467–74.
59. Hoernig A, Raub S, Dechêne A, et al. Diversity of disorders causing neonatal cholestasis—the experience of a tertiary pediatric center in Germany. *Front Pediatr* 2014;2:65.
60. Wildhaber BE, Majno P, Mayr J, et al. Biliary atresia: Swiss national study, 1994-2004. *J Pediatr Gastroenterol Nutr* 2008;46:299–307.
61. Grizelj R, Vuković J, Novak M, et al. Biliary atresia: the Croatian experience. *Eur J Pediatr* 2010;169:1529–34.
62. Davenport M, Caponcelli E, Livesey E, et al. Biliary atresia in England and Wales: results of centralization and new benchmark. *J Pediatr Surg* 2011;46:1689–94.
63. Lampela H, Ritvanen A, Kosola S, et al. National centralization of biliary atresia care to an assigned multidisciplinary team provides high-quality outcomes. *Scand J Gastroenterol* 2012;47:99–107.
64. Davenport M, Puricelli V, Farrant P, et al. The outcome of the older (> or = 100 days) infant with biliary atresia. *J Pediatr Surg* 2004;39:575–81.
65. Lien TH, Chang MH, Wu JF, et al. Effects of the infant stool color card screening program on 5-year outcome of biliary atresia in Taiwan. *Hepatology* 2011;53:202–8.
66. Moyer VA, Ahn C, Sneed S. Accuracy of clinical judgment in neonatal jaundice. *Arch Pediatr Adolesc Med* 2000;154:391–4.
67. Winfield CR, MacFaul R. Clinical study of prolonged jaundice in breast- and bottle-fed babies. *Arch Dis Child* 1978;53:506–7.
68. Kelly DA, Stanton A. Jaundice in babies: implications for community screening for biliary atresia. *BMJ* 1995;310:1172–3.
69. Kamath BM, Loomes KM, Oakey RJ, et al. Facial features in Alagille syndrome: specific or cholestasis facies? *Am J Med Genet* 2002;112:163–70.
70. Lo SF, Kytzia HJ, Schumann G, et al. Interlaboratory comparison of the Dumas bilirubin reference method. *Clin Biochem* 2009;42:1328–30.
71. Lo SF, Dumas BT. The status of bilirubin measurements in U.S. laboratories: why is accuracy elusive? *Semin Perinatol* 2011;35:141–7.
72. Rosenthal P, Blanckaert N, Kabra PM, et al. Formation of bilirubin conjugates in human newborns. *Pediatr Res* 1986;20:947–50.
73. Keffler S, Kelly DA, Powell JE, et al. Population screening for neonatal liver disease: a feasibility study. *J Pediatr Gastroenterol Nutr* 1998;27:306–11.
74. Gourley GR. Breast-feeding, neonatal jaundice and kernicterus. *Semin Neonatol* 2002;7:135–41.
75. Maisels MJ, Gifford K. Normal serum bilirubin levels in the newborn and the effect of breast-feeding. *Pediatrics* 1986;78:837–43.
76. Arias IM, Gartner LM, Seifter S, et al. Prolonged neonatal unconjugated hyperbilirubinemia associated with breast feeding and a steroid, pregnane-3(alpha), 20(beta)-diol, in maternal milk that inhibits glucuronide formation *in vitro*. *J Clin Invest* 1964;43:2037–47.
77. American Academy of Pediatrics Subcommittee on Hyperbilirubinemia. Management of hyperbilirubinemia in the newborn infant 35 or more weeks of gestation. *Pediatrics* 2004;114:297–316.
78. Bakshi B, Sutcliffe A, Akindolie M, et al. How reliably can paediatric professionals identify pale stool from cholestatic newborns? *Arch Dis Child Fetal Neonatal Ed* 2012;97:F385–7.
79. Chen SM, Chang MH, Du JC, et al. Screening for biliary atresia by infant stool color card in Taiwan. *Pediatrics* 2006;117:1147–54.
80. Schreiber RA, Masucci L, Kaczorowski J, et al. Home-based screening for biliary atresia using infant stool colour cards: a large-scale prospective cohort study and cost-effectiveness analysis. *J Med Screen* 2014;21:126–32.
81. Wildhaber BE. Screening for biliary atresia: Swiss stool color card. *Hepatology* 2011;54:367–8.

82. Carter BA, Karpen SJ. Intestinal failure-associated liver disease: management and treatment strategies past, present, and future. *Semin Liver Dis* 2007;27:251–8.
83. Ellaway CJ, Silinik M, Cowell CT, et al. Cholestatic jaundice and congenital hypopituitarism. *J Paediatr Child Health* 1995;31:51–3.
84. Karnsakul W, Sawathiparnich P, Nimkarn S, et al. Anterior pituitary hormone effects on hepatic functions in infants with congenital hypopituitarism. *Ann Hepatol* 2007;6:97–103.
85. Sokol RJ, Shepherd RW, Superina R, et al. Screening and outcomes in biliary atresia: summary of a National Institutes of Health workshop. *Hepatology* 2007;46:566–81.
86. Hirfanoglu IM, Unal S, Onal EE, et al. Analysis of serum gamma-glutamyl transferase levels in neonatal intensive care unit patients. *J Pediatr Gastroenterol Nutr* 2014;58:99–101.
87. Lu FT, Wu JF, Hsu HY, et al. gamma-Glutamyl transpeptidase level as a screening marker among diverse etiologies of infantile intrahepatic cholestasis. *J Pediatr Gastroenterol Nutr* 2014;59:695–701.
88. van Mil SW, Houwen RH, Klomp LW. Genetics of familial intrahepatic cholestasis syndromes. *J Med Genet* 2005;42:449–63.
89. Balistreri WF. Neonatal cholestasis. *J Pediatr* 1985;106:171–84.
90. Mittal V, Saxena AK, Sodhi KS, et al. Role of abdominal sonography in the preoperative diagnosis of extrahepatic biliary atresia in infants younger than 90 days. *AJR Am J Roentgenol* 2011;196:W438–45.
91. Humphrey TM, Stringer MD. Biliary atresia: US diagnosis. *Radiology* 2007;244:845–51.
92. Lee HJ, Lee SM, Park WH, et al. Objective criteria of triangular cord sign in biliary atresia on US scans. *Radiology* 2003;229:395–400.
93. Kim WS, Cheon JE, Youn BJ, et al. Hepatic arterial diameter measured with US: adjunct for US diagnosis of biliary atresia. *Radiology* 2007;245:549–55.
94. Tan Kendrick AP, Phua KB, Ooi BC, et al. Biliary atresia: making the diagnosis by the gallbladder ghost triad. *Pediatr Radiol* 2003;33:311–5.
95. Farrant P, Meire HB, Mieli-Vergani G. Ultrasound features of the gall bladder in infants presenting with conjugated hyperbilirubinaemia. *Br J Radiol* 2000;73:1154–8.
96. Kianifar HR, Tehrani S, Shojaei P, et al. Accuracy of hepatobiliary scintigraphy for differentiation of neonatal hepatitis from biliary atresia: systematic review and meta-analysis of the literature. *Pediatr Radiol* 2013;43:905–19.
97. Gilmour SM, Hershkop M, Reifen R, et al. Outcome of hepatobiliary scanning in neonatal hepatitis syndrome. *J Nucl Med* 1997;38:1279–82.
98. Yang JG, Ma DQ, Peng Y, et al. Comparison of different diagnostic methods for differentiating biliary atresia from idiopathic neonatal hepatitis. *Clin Imaging* 2009;33:439–46.
99. Majd M, Reba RC, Altman RP. Hepatobiliary scintigraphy with 99mTc-PIPIDA in the evaluation of neonatal jaundice. *Pediatrics* 1981;67:140–5.
100. Shneider BNK, Superina R, Erlichman J, et al. Diagnostic imaging in neonatal cholestasis: a multi-center prospective analysis. *Hepatology* 2006;44:437A.
101. Williamson SL, Seibert JJ, Butler HL, et al. Apparent gut excretion of Tc-99m-DISIDA in a case of extrahepatic biliary atresia. *Pediatr Radiol* 1986;16:245–7.
102. Shanmugam NP, Harrison PM, Devlin J, et al. Selective use of endoscopic retrograde cholangiopancreatography in the diagnosis of biliary atresia in infants younger than 100 days. *J Pediatr Gastroenterol Nutr* 2009;49:435–41.
103. Shteyer E, Wengrower D, Benuri-Silbiger A, et al. Endoscopic retrograde cholangiopancreatography in neonatal cholestasis. *J Pediatr Gastroenterol Nutr* 2012;55:142–5.
104. Keil R, Snajdauf J, Rygl M, et al. Diagnostic efficacy of ERCP in cholestatic infants and neonates—a retrospective study on a large series. *Endoscopy* 2010;42:121–6.
105. Chardot C. Endoscopic retrograde cholangiopancreatography in patients with neonatal cholestasis: an additional diagnostic tool for selected indications. *J Pediatr Gastroenterol Nutr* 2009;49:380–1.
106. Metreweli C, So NM, Chu WC, et al. Magnetic resonance cholangiography in children. *Br J Radiol* 2004;77:1059–64.
107. Liu B, Cai J, Xu Y, et al. Three-dimensional magnetic resonance cholangiopancreatography for the diagnosis of biliary atresia in infants and neonates. *PLoS One* 2014;9:e88268.
108. Meyers RL, Book LS, O’Gorman MA, et al. Percutaneous cholecystocholangiography in the diagnosis of obstructive jaundice in infants. *J Pediatr Surg* 2004;39:16–8.
109. Jensen MK, Biank VF, Moe DC, et al. HIDA, percutaneous transhepatic cholecystocholangiography and liver biopsy in infants with persistent jaundice: can a combination of PTCC and liver biopsy reduce unnecessary laparotomy? *Pediatr Radiol* 2012;42:32–9.
110. Russo P, Magee JC, Boitnott J, et al. Design and validation of the biliary atresia research consortium histologic assessment system for cholestasis in infancy. *Clin Gastroenterol Hepatol* 2011;9:357–62e2.
111. Morotti RJ. Pediatric Cholestatic Disorders. Approach to pathologic diagnosis. *Surg Pathol Clin* 2013;6:205–390.
112. Davenport M, Tizzard SA, Underhill J, et al. The biliary atresia splenic malformation syndrome: a 28-year single-center retrospective study. *J Pediatr* 2006;149:393–400.
113. Rastogi A, Krishnani N, Yachha SK, et al. Histopathological features and accuracy for diagnosing biliary atresia by prelaparotomy liver biopsy in developing countries. *J Gastroenterol Hepatol* 2009;24:97–102.
114. Azar G, Benek D, Lane B, et al. Atypical morphologic presentation of biliary atresia and value of serial liver biopsies. *J Pediatr Gastroenterol Nutr* 2002;34:212–5.
115. Weerasooriya VS, White FV, Shepherd RW. Hepatic fibrosis and survival in biliary atresia. *J Pediatr* 2004;144:123–5.
116. Shteyer E, Ramm GA, Xu C, et al. Outcome after portoenterostomy in biliary atresia: pivotal role of degree of liver fibrosis and intensity of stellate cell activation. *J Pediatr Gastroenterol Nutr* 2006;42:93–9.
117. Govender P, Jonas MM, Alomari A, et al. Sonography-guided percutaneous liver biopsies in children. *AJR Am J Roentgenol* 2013;201:645–50.
118. Amaral JG, Schwartz J, Chait P, et al. Sonographically guided percutaneous liver biopsy in infants: a retrospective review. *AJR Am J Roentgenol* 2006;187:W644–9.
119. el-Youssef M, Whittington PF. Diagnostic approach to the child with hepatobiliary disease. *Semin Liver Dis* 1998;18:195–202.
120. Hays DM, Woolley MM, Snyder WH Jr et al. Diagnosis of biliary atresia: relative accuracy of percutaneous liver biopsy, open liver biopsy, and operative cholangiography. *J Pediatr* 1967;71:598–607.
121. Altman RP, Abramson S. Potential errors in the diagnosis and surgical management of neonatal jaundice. *J Pediatr Surg* 1985;20:529–34.
122. Kim WS, Kim IO, Yeon KM, et al. Choledochal cyst with or without biliary atresia in neonates and young infants: US differentiation. *Radiology* 1998;209:465–9.
123. Matsubara H, Oya N, Suzuki Y, et al. Is it possible to differentiate between choledochal cyst and congenital biliary atresia (type I cyst) by antenatal ultrasonography? *Fetal Diagn Ther* 1997;12:306–8.
124. Casaccia G, Bilancioni E, Nahom A, et al. Cystic anomalies of biliary tree in the fetus: is it possible to make a more specific prenatal diagnosis? *J Pediatr Surg* 2002;37:1191–4.
125. Hartley JL, Gissen P, Kelly DA. Alagille syndrome and other hereditary causes of cholestasis. *Clin Liver Dis* 2013;17:279–300.
126. Emerick KM, Rand EB, Goldmuntz E, et al. Features of Alagille syndrome in 92 patients: frequency and relation to prognosis. *Hepatology* 1999;29:822–9.
127. Lykavieris P, Bernard O, Hadchouel M. Neonatal cholestasis as the presenting feature in cystic fibrosis. *Arch Dis Child* 1996;75:67–70.
128. Wagener JS, Zemanick ET, Sontag MK. Newborn screening for cystic fibrosis. *Curr Opin Pediatr* 2012;24:329–35.
129. Lu FT, Wu JF, Hsu HY, et al. Gamma-glutamyl transpeptidase level as a screening marker among diverse etiologies of infantile intrahepatic cholestasis. *J Pediatr Gastroenterol Nutr* 2014;59:695–701.
130. Pawlikowska L, Strautnieks S, Jankowska I, et al. Differences in presentation and progression between severe FIC1 and BSEP deficiencies. *J Hepatol* 2010;53:170–8.
131. Hoerning A, Raub S, Dechêne A, et al. Diversity of disorders causing neonatal cholestasis—the experience of a tertiary pediatric center in Germany. *Front Pediatr* 2014;2:65.
132. Suchy FJ. Neonatal cholestasis. *Pediatr Rev* 2004;25:388–96.

133. Ovchinsky N, Moreira RK, Lefkowitz JH, et al. Liver biopsy in modern clinical practice: a pediatric point-of-view. *Adv Anat Pathol* 2012;19:250–62.
134. Johnson K, Alton HM, Chapman S. Evaluation of mebrofenin hepatoscintigraphy in neonatal-onset jaundice. *Pediatr Radiol* 1998;28:937–41.
135. Pittschieler K, Massi G. Liver involvement in infants with PiSZ phenotype of alpha 1-antitrypsin deficiency. *J Pediatr Gastroenterol Nutr* 1992;15:315–8.
136. Topic A, Ljubic M, Nikolic A, et al. Alpha-1-antitrypsin phenotypes and neutrophil elastase gene promoter polymorphisms in lung cancer. *Pathol Oncol Res* 2011;17:75–80.
137. Lang T, Mühlbauer M, Strobelt M, et al. Alpha-1-antitrypsin deficiency in children: liver disease is not reflected by low serum levels of alpha-1-antitrypsin—a study on 48 pediatric patients. *Eur J Med Res* 2005;10:509–14.
138. Nord KS, Saad S, Joshi VV, et al. Concurrence of alpha 1-antitrypsin deficiency and biliary atresia. *J Pediatr* 1987;111:416–8.
139. Tolaymat N, Figueroa-Colon R, Mitros FA. Alpha 1-antitrypsin deficiency (Pi SZ) and biliary atresia. *J Pediatr Gastroenterol Nutr* 1989;9:256–60.
140. Setchell KD, Heubi JE. Defects in bile acid biosynthesis—diagnosis and treatment. *J Pediatr Gastroenterol Nutr* 2006;43(suppl 1):S17–22.
141. Hommes FA, Varghese M. High-performance liquid chromatography of urinary oligosaccharides in the diagnosis of glycoprotein degradation disorders. *Clin Chim Acta* 1991;203:211–24.
142. Blau N, Beck M, Matern D. Tetrahydrobiopterin induced neonatal tyrosinaemia. *Eur J Pediatr* 1996;155:832.
143. Wraith JE. Diagnosis and management of inborn errors of metabolism. *Arch Dis Child* 1989;64 (10 Spec No):1410–5.
144. Mak CM, Lee HC, Chan AY, et al. Inborn errors of metabolism and expanded newborn screening: review and update. *Crit Rev Clin Lab Sci* 2013;50:142–62.
145. Croffie JM, Gupta SK, Chong SK, et al. Tyrosinemia type 1 should be suspected in infants with severe coagulopathy even in the absence of other signs of liver failure. *Pediatrics* 1999;103:675–8.
146. McCracken GH Jr, Shinefield HM, Cobb K, et al. Congenital cytomegalic inclusion disease. A longitudinal study of 20 patients. *Am J Dis Child* 1969;117:522–39.
147. Watkins JB, Sunaryo FP, Berezin SH. Hepatic manifestations of congenital and perinatal disease. *Clin Perinatol* 1981;8:467–80.
148. Plosa EJ, Esbenshade JC, Fuller MP, et al. Cytomegalovirus infection. *Pediatr Rev* 2012;33:156–63.
149. Wieringa JW, de Vries JJ, Murk JL. Congenital CMV infections. *Ned Tijdschr Geneesk* 2013;157:A6250.
150. Xu Y, Yu J, Zhang R, et al. The perinatal infection of cytomegalovirus is an important etiology for biliary atresia in China. *Clin Pediatr (Phila)* 2012;51:109–13.
151. Jevon GP, Dimmick JE. Biliary atresia and cytomegalovirus infection: a DNA study. *Pediatr Dev Pathol* 1999;2:11–4.
152. Fischler B, Ehrnst A, Forsgren M, et al. The viral association of neonatal cholestasis in Sweden: a possible link between cytomegalovirus infection and extrahepatic biliary atresia. *J Pediatr Gastroenterol Nutr* 1998;27:57–64.
153. Mattei PL, Beachkofsky TM, Gilson RT, et al. Syphilis: a reemerging infection. *Am Fam Physician* 2012;86:433–40.
154. Seeler RA, Hahn K. Jaundice in urinary tract infection in infancy. *Am J Dis Child* 1969;118:553–8.
155. Regelman MO, Miloh T, Arnon R, et al. Graves' disease presenting with severe cholestasis. *Thyroid* 2012;22:437–9.
156. Mitchell ML, Hsu HW, Sahai I. Changing perspectives in screening for congenital hypothyroidism and congenital adrenal hyperplasia. *Curr Opin Endocrinol Diabetes Obes* 2014;21:39–44.
157. Minamitani K, Inomata H. Neonatal screening for congenital hypothyroidism in Japan. *Pediatr Endocrinol Rev* 2012;10(suppl 1):79–88.
158. Geffner ME. Hypopituitarism in childhood. *Cancer Control* 2002;9:212–22.
159. DeSalvo D, Pohl JF, Wilson DP, et al. Cholestasis secondary to panhypopituitarism in an infant. *J Natl Med Assoc* 2008;100:342–4.
160. Kaufman FR, Costin G, Thomas DW, et al. Neonatal cholestasis and hypopituitarism. *Arch Dis Child* 1984;59:787–9.