

Diagnosis and Treatment of Perianal Crohn Disease: NASPGHAN Clinical Report and Consensus Statement

*Edwin F. de Zoeten, †Brad A. Pasternak, §Peter Mattei, *Robert E. Kramer, and †Howard A. Kader

ABSTRACT

Inflammatory bowel disease is a chronic inflammatory disorder of the gastrointestinal tract that includes both Crohn disease (CD) and ulcerative colitis. Abdominal pain, rectal bleeding, diarrhea, and weight loss characterize both CD and ulcerative colitis. The incidence of IBD in the United States is 70 to 150 cases per 100,000 individuals and, as with other autoimmune diseases, is on the rise. CD can affect any part of the gastrointestinal tract from the mouth to the anus and frequently will include perianal disease. The first description connecting regional enteritis with perianal disease was by Bissell et al in 1934, and since that time perianal disease has become a recognized entity and an important consideration in the diagnosis and treatment of CD. Perianal Crohn disease (PCD) is defined as inflammation at or near the anus, including tags, fissures, fistulae, abscesses, or stenosis. The symptoms of PCD include pain, itching, bleeding, purulent discharge, and incontinence of stool. In this report, we review and discuss the etiology, diagnosis, evaluation, and treatment of PCD.

Key Words: perianal abscess, perianal Crohn disease, perianal fistula

(*JPGN* 2013;57: 401–412)

Inflammatory bowel disease (IBD) is a chronic inflammatory disorder of the gastrointestinal tract that includes both Crohn disease (CD) and ulcerative colitis (UC). Abdominal pain, rectal bleeding, diarrhea, and weight loss characterize both CD and UC. The incidence of IBD in the United States is 70 to 150 cases per 100,000 individuals and, as with other autoimmune diseases, is on the rise (1). CD can affect any part of the gastrointestinal tract from the mouth to the anus and frequently will include perianal

Received June 18, 2013; accepted June 6, 2013.

From the *Department of Pediatrics, University of Colorado School of Medicine, Children's Hospital Colorado, Digestive Health Institute, Pediatric Inflammatory Bowel Disease Center, Denver, CO, the †Department of Pediatrics, Division of Pediatric Gastroenterology and Nutrition, University of Maryland School of Medicine Pediatric Inflammatory Bowel Disease Center, Baltimore, MD, the ‡Department of Pediatric Gastroenterology, Phoenix Children's Hospital, Phoenix, AZ, and the §Department of Surgery, University of Pennsylvania, The Children's Hospital of Philadelphia, Philadelphia, PA.

Address correspondence and reprint requests to Edwin de Zoeten, MD, PhD, Pediatric IBD Center, Children's Hospital Denver Digestive Health Institute, Anschutz Medical Campus, 13123 East 16th Ave, B290 Aurora, CO 80045.

This article has been developed as a Journal CME Activity by NASPGHAN. Visit <http://www.naspghan.org/wmspage.cfm?parm1=742> to view instructions, documentation, and the complete necessary steps to receive CME credit for reading this article.

Copyright © 2013 by European Society for Pediatric Gastroenterology, Hepatology, and Nutrition and North American Society for Pediatric Gastroenterology, Hepatology, and Nutrition

DOI: 10.1097/MPG.0b013e3182a025ee

disease. The first description connecting regional enteritis with perianal disease was by Bissell et al in 1934 (2), and since that time perianal disease has become a recognized entity and an important consideration in the diagnosis and treatment of CD. Perianal Crohn disease (PCD) is defined as inflammation at or near the anus, including tags, fissures, fistulae, abscesses, or stenosis. The symptoms of PCD include pain, itching, bleeding, purulent discharge, and incontinence of stool.

INCIDENCE AND NATURAL HISTORY

Limited pediatric data describe the incidence and prevalence of PCD. The incidence of PCD in the pediatric age group has been estimated to be between 13.6% and 62% (3). In a review by Palder et al (4), 62% of 325 children with CD developed PCD. Skin tags were present in 114 (35%), fissures in 185 (51%), fistulae in 41 (15%), and perirectal abscesses in 47 (13%). In another study of 276 patients with CD, Keljo et al identified perianal lesions in 41 (15%) who were studied within 30 days of diagnosis (3). A 2012 study in New Zealand reported that 26.5% of children with CD develop some form of PCD (5).

In the adult literature, the reported incidence of PCD ranges from 25% to 80% (6) and fistulizing PCD from 17% to 43% (7–9). The clinical course of PCD depends on the type, including skin tag, rectal stricture, fistulae or fissures, and location of disease. Skin tags in general do not resolve completely with treatment, but remain present and benign. Fissures will often heal completely with minor medical therapy. Simple fistulizing disease, when superficial and confined to the anal canal, heals spontaneously in 50% of cases (10). In contrast, rectovaginal and complex fistulae rarely heal without therapy (11). Complex fistulae include those with origin of the fistulous tract that is high intersphincteric, high transsphincteric, extrasphincteric, or suprasphincteric.

ETIOLOGY

CD is defined in part by the transmural nature of inflammation, which in turn predisposes patients to fistulae and abscess formation around the anus and in other locations. Two mechanisms have been postulated with regard to the pathogenesis of fistulae and abscesses: initial inflammation in the rectum forms either ulcers or shallow fistulae, which subsequently extend into deep or penetrating fistulae with the persistent exposure to feces and pressure caused by defecation (12); infected anal glands penetrate the intrasphincteric space and then progress to form fistulae or abscesses (13).

Increasing evidence supports a role for genetic predisposition and microbiota influence in the development of perianal fistulae (PF) and abscesses (PAs). A study from New Zealand looking at 715 patients younger than 20 years found that PCD not only was significantly associated with younger age at diagnosis, complicated intestinal disease, and ileal disease location but it also had a genetic link (5). The characterization of the genetic background in CD

continues to develop rapidly, especially by means of genome-wide association studies. An association of CD fistulae and abscesses has been linked to specific gene variants at the susceptibility locus on chromosome 5q31 (IBD5), including *OCTN* (14) and *IRGM* (14–16). Impaired *OCTN* activity or expression may reduce carnitine transport, which can lead to defects in oxygen burst-mediated pathogen killing, fatty acid oxidation defects in the intestinal epithelial cells, or defects in transport of bacterial toxins into and out of the epithelial cells causing inflammation. Whether these are mechanisms that cause PCD is unknown. *IRGM* is part of the autophagy pathway that eliminates intracellular organisms. Although the study from New Zealand did not show the same association with *IRGM*, it did note an association with a novel gene neutrophil cytosolic factor 4 (*NCF4*), a gene that has a role in phagocytosis and bacterial killing (5).

A few investigators have studied the association between the *NOD2/CARD15* genotype and PCD. To date, no correlation exists between this genotype and PF (17); however, *NOD2/CARD15* gene status appears to influence the response of PF to antibiotic therapy, with a greater response noted in patients with *NOD2/CARD15* wild type (18).

Although the use of antibiotics and fecal diversion appears useful in some patients with PF and PA, suggesting a pathogenic contribution of the microbiome, their incomplete efficacy suggests that microbes alone cannot explain PCD. The search for a single organism as the causative agent has yielded inconsistent results. In general, many bacterial species have been implicated in inflammation, including enteroadherent strains of *Escherichia coli* (19) *Chlamydia* (20), and mycobacteria (21). Whether these changes in bacterial flora are primary or secondary to the disease process is not clear. Few studies have assessed microbiological changes in Crohn fistulae. One involved the aspiration of pus from the fistulous tracts of 13 Crohn patients with perianal disease (22). These samples were analyzed by standard bacterial culture techniques. Gram-positive organisms, in particular staphylococci, streptococci, and corynebacter, predominated over Gram-negative enteric organisms (23). This differs from idiopathic fistula (22), in which the microbiota found on excised granulation tissue were largely of gastrointestinal origin. Additional investigations are needed to clarify the role of the microbiology of CD fistulizing disease.

CLINICAL PRESENTATION

Manifestations of PCD fall into 3 distinct categories: tissue destruction, which includes anal fissures, tags, and deep ulcers lined with exuberant granulation tissue; fistulae and abscesses, which are often multiple and complex and are frequently related; and rectal stricture, which is likely the result of long-standing or even healed circumferential Crohn-related inflammation of the rectum or anoderm. The spectrum of PCD is variable in that some may have relatively mild disease, whereas others can have a severe, destructive, and debilitating course leading to constipation, fecal incontinence, recurrent infections and sepsis, compromise of sexual function, significantly diminished quality of life, and, in some cases resulting in a diverting colostomy or ileostomy (3,24). Even in its most severe form, PCD can be surprisingly painless. Children and adolescents are often reticent to volunteer information about bowel habits, drainage, or anal pruritus; it is therefore extremely important to ask direct questions about these symptoms. Fissures may cause bleeding but, despite their depth or severity, do not always cause pain with defecation. Anal skin tags, classic hallmarks of CD, may result in cosmetic concerns, but are not frequently associated with pain unless inflamed.

Strictures are typically the result of long-standing inflammation (25) and generally form extremely slowly, which allows

patients to accommodate themselves to the relative narrowing of the rectum. Thus, often patients state an ability to pass stool normally despite having a rectal stricture. Nevertheless, although children with PCD may not complain of pain, the functional impairments (constipation, incontinence, spontaneous drainage) and the social implications (odor, stained undergarments, anxiety) are often significant.

PERIANAL FISTULA

Diagnosis

Diagnosing PF in CD is extremely important because this ultimately influences not only the medical but also the surgical management and approach to therapy (Fig. 1). In addition, definition of the anatomic location of the fistula is critical if surgical intervention is considered.

Grading and Naming Systems

Various attempts to develop a consistent and useful severity score or staging system have been described over the years; however, their clinical value, especially in children, has been limited. Several of the more common approaches are discussed here.

Cardiff System

The earliest and perhaps still most commonly used classification scheme is the Cardiff system, originally described in 1978 by Hughes (12) and later modified in 1992 (26). The Cardiff classification provides a thorough anatomic description of the disease, but its real clinical significance has been questioned (6,27). Each major component of the disease (ulceration, fistula, and stricture) is graded on a scale of 0, 1, or 2. The score is also modified by the presence of associated anal conditions (hemorrhoids, malignancy), proximal intestinal disease, and relative disease activity (active inflammation).

Park Classification

PF are still often classified according to the descriptive surgical Park classification, which was originally used to describe fistula-in-ano not associated with CD. Although helpful in the operative setting, this system may be difficult to use in clinical practice (28). Park described 5 types of fistula (Fig. 2, left side): superficial, which stays below the internal and external sphincters, travels inferior to the sphincters, and involves the ischioanal fossa; intersphincteric, which travels between the internal and external anal sphincters; transsphincteric, which passes through the external sphincter; suprasphincteric, a complex fistula that passes through the internal sphincter and then travels up through the levator ani musculature before tracking to the skin, which can also result in supralelevator abscesses as the tract extends through the levator ani muscle toward the skin after leaving the intersphincteric space by going over the top of the puborectalis muscle; and extrasphincteric, which stays external to the sphincters connecting rectum and skin. These fistulae pass through the ischioanal fossa and levator ani muscle opening into the rectum (28). Patients with PF often have complex, branching, and interconnected series of fistulae that defy easy description, let alone objective classification.

Simple Versus Complex Fistula

Location of the fistula (high or low in relation to the anorectal ring) is traditionally used by clinicians to classify fistulae; however, a recent description as to whether it is a simple or complex fistula,

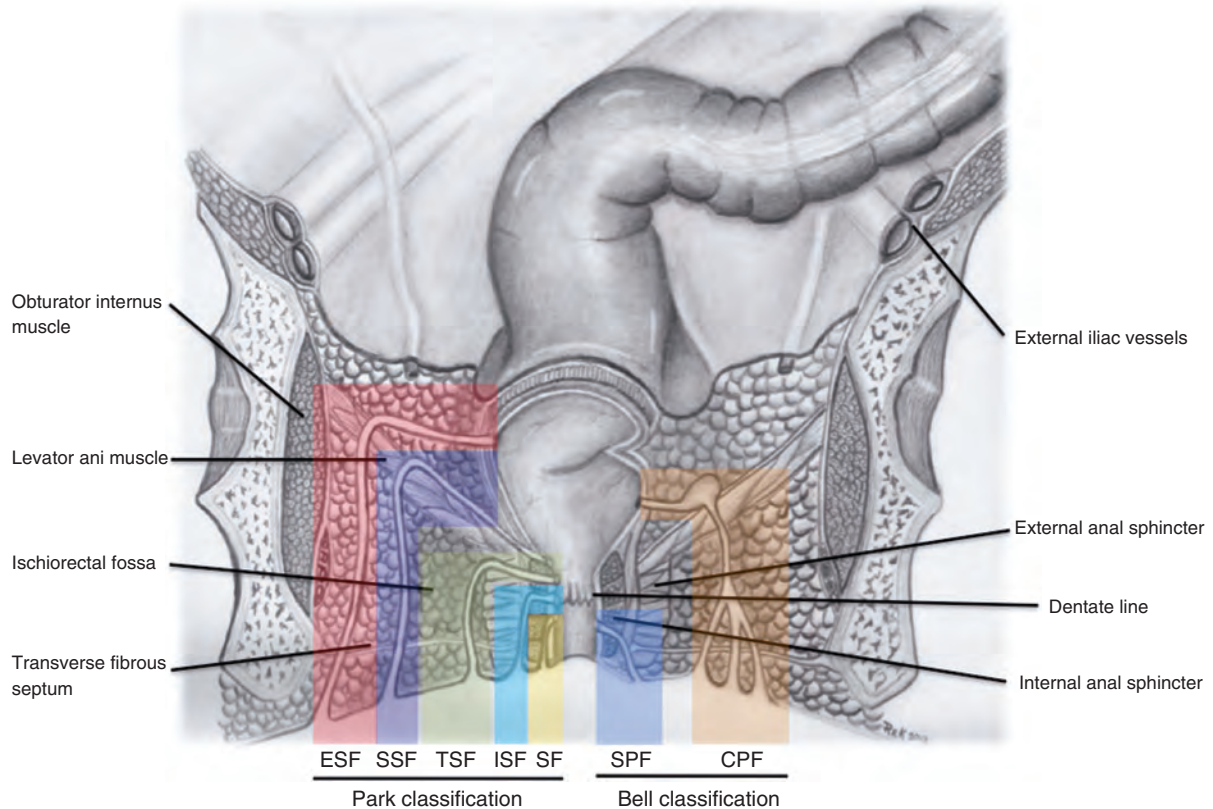


FIGURE 1. Schematic illustration of 2 classification systems for perianal fistulas. On the left, the Park classification identifies strictures based on their anatomic relation to the internal and external anal sphincters. On the right, the Bell classification divides fistulas into either simple or complex categories, depending on how low the internal opening is or if the fistula contains an abscess or multiple branches. CPF = complex perianal fistula (orange); ESF = extrasphincteric fistula (red); ISF = intrasphincteric fistula (light blue); SF = superficial fistula (yellow); SPF = simple perianal fistula (dark blue); SSF = suprasphincteric fistula (purple); TSF = transsphincteric fistula (green). Illustration by Robert Kramer, MD.

such as that suggested by Bell et al (29) in 2003 (Fig. 2, right side), may be more relevant for the clinician. To determine a simple versus complex fistula, the clinician assesses the perianal region for the presence of abscesses, strictures, and fistulous connections by inspection as well as endoscopically. A simple fistula involves a low intersphincteric or transsphincteric location, a single short tract, an

internal opening lower and closer to the anal verge, and the external opening near the anal verge without an abscess. A complex fistula involves the sphincter muscle/anorectal ring, multiple fistulae, and branches with or without an abscess; an internal opening of the fistulous tract is above the sphincter muscles, with the external opening further away from the anal opening.

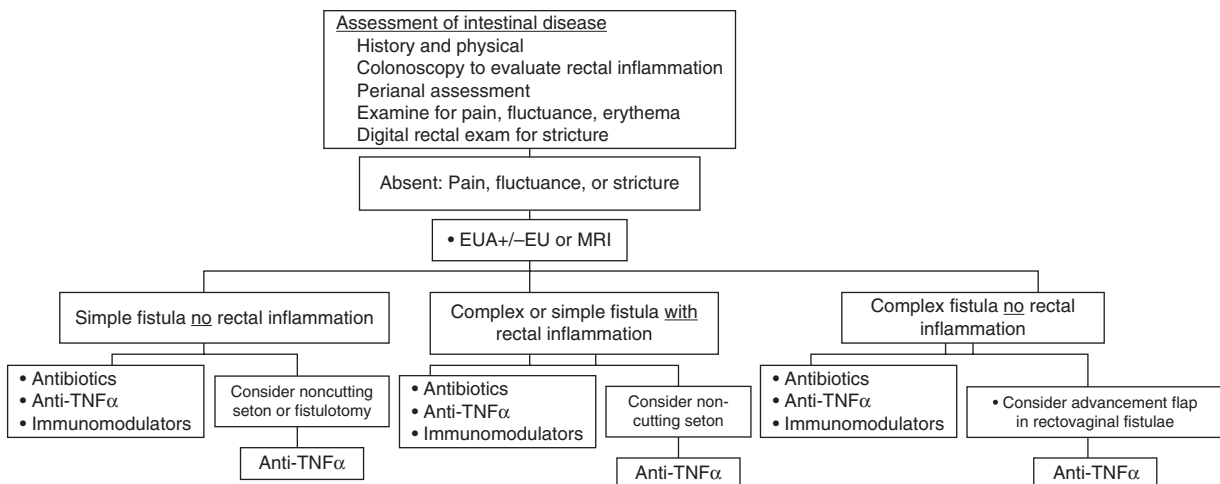


FIGURE 2. Perianal fistula—assessment and treatment algorithm.

PCD Activity Index

Pikarsky et al (30) in 2002 proposed a much more comprehensive score, the PCD activity index, which entails separately grading the degree of abscesses, fistula, ulcer, fissure, stenosis, incontinence, and concomitant upper-tract bowel disease by separate scales and adding them together to produce a score between 0 and 55. Although more sophisticated and possibly more predictive than the Cardiff classification, the clinical usefulness of this more cumbersome system has yet to be demonstrated and may have more use in clinical trials and outcome assessment than in clinical practice (31).

Several imaging modalities are available to adequately diagnose, define, and classify a PF. Complete documentation of PCD is accomplished with radiologic imaging, visual inspection under anesthesia, and endoscopic assessment to formulate an individual treatment plan.

Imaging of PF

All children with CD, with or without perianal complaints, should at minimum have an external examination of the perianal region. Without external visible signs of PCD, most children will tolerate a gentle and brief digital rectal examination to identify a significant stricture or fluctuance; however, if clear signs of PCD are present, radiographic evaluation or examination under anesthesia are more useful and less traumatic and should be considered (32).

Radiographic imaging modalities include magnetic resonance imaging (MRI), computerized tomography (CT), endoscopic anorectal ultrasound (EUS), and fistulography. It is often difficult to visualize the enteric opening of a fistula or to attain retrograde fill of a fistulous tract with contrast externally, making a fistulogram challenging. Consequently, the accuracy of fistulography has been reported to be poor, 16% to 50% (33). EUS has technical limitations and requires considerable expertise, especially if a stricture/stenosis or abscess is present. CT scans, although beneficial for identifying strictures, thickened bowel wall, and fluid collections/abscesses, is not useful for delineating soft tissue and muscle layers containing the fistulous tracts. Consequently, the most useful radiologic modality to evaluate abscesses and fistulae is MRI. The MRI can show separate soft tissues with high distinction; images can be viewed in both coronal and sagittal planes to better delineate landmarks, and nonionizing radiation avoids exposure to radiation (34). MRI is highly sensitive for fistulae and abscesses. Compared with examination under anesthesia (EUA), the specificity of MRI in identifying the fistula and its path ranges from 76% to 100%. Additionally, MRI incorporates the benefit that a CT offers without the radiation exposure, and thus is considered to be the radiologic study of choice under most circumstances (8). Most patients, therefore, benefit from MRI followed by EUA.

Abdominal MRI and pelvic MRI have been applied in the diagnosis of fistulae and PF in children (35–39). Advances such as higher field strength and greater signal-to-noise ratio have reduced scan time and improved image resolution (35–39). New techniques in breath hold image capture, fat suppression, oral contrast agents, and intravenous gadolinium generate consistent high-quality MRI images in children (12,14). In pediatrics, MRI has been used to identify fistula, inflammation, and evaluate related complications in the perianal and perirectal regions, similar to adult studies (15,16). Others have shown the use of MRI in determining the extent of the disease to assist in operative planning and management in adult patients (40–44).

EUA is a safe and well-tolerated procedure that has a reported specificity of 91% (45,46). Where available, EUA is the preferred diagnostic choice if a PA is suspected (47). Consensus recommendations from the European Crohn's and Colitis Organization in 2006 support the combination of MRI and proctosigmoidoscopy evaluation in making a diagnosis of PF or PA and for planning therapy (8). The European Crohn's and Colitis Organization statement also recommended an EUA alone if there is a contraindication to using the MRI and determined that the EUA is considered the criterion standard in the hands of an experienced surgeon (8). Although EUA is considered a diagnostic procedure, it often offers the concomitant opportunity to provide symptomatic relief or to treat or prevent an infectious complication (33).

To perform EUA, careful external examination is performed, followed by digital examination. The degree and extent of inflammatory changes and any degree of stricture, if present, should be noted. Areas of induration or fluctuance may indicate an abscess, highlighting the benefit of preoperative imaging. Aspiration with a large-bore needle and syringe can be used to identify pockets of purulent fluid that require drainage. Any dimple or potential fistula should be probed gently to identify cavities or communication with the rectum or anoderm. In boys, the base of the scrotum and in girls the labia majora and the vaginal walls should be included in the field to help identify all potential sites of disease extension and fistulae. Meticulous probing should allow characterization of the full extent of most PF; dilute methylene blue or hydrogen peroxide injected gently into an external opening may be helpful to identify an internal fistulous tract.

In summary, the most common approach to evaluate PCD involves an external examination and rectal examination, followed by imaging with MRI and finally EUA performed by an experienced surgeon (Fig. 1).

PA

Classification of a PA involves the relation of the abscess to the internal sphincter and levator muscles (Fig. 3). Abscesses may be perianal, ischiorectal, or submucosal, indicating collections of pus in the shallower or more superficial layers of the skin around the anus. A pelvirectal abscess is deeper, occurring between the levator muscle and the anterior peritoneal reflection. Approximately 60% of such abscesses are perianal, with another 30% being ischiorectal, and the remainder are equally split at 5% for submucosal/intramural and pelvirectal (48). The goal of diagnosing a PA is not only to correctly identify this entity but also to promptly institute therapy to alleviate the clinical signs and symptoms.

The diagnosis of a PA relies primarily on visual inspection and physical examination. Features include erythema and swelling involving the skin around the anus with a visual bulge and a palpable bump that may be either firm, tense, and painful to the touch or fluctuant. Pain at the anus can also be a symptom as well as signs of pus or purulent drainage from the anus. Fever, chills, and malaise may be systemic signs of a PA.

Imaging modalities that may be useful to evaluate the extent of the PA include CT scan, MRI, or ultrasound. CT with intravenous and rectal contrast may show the presence and the location of a perirectal abscess and can identify deeper abscesses than ultrasonography; however, ultrasound is useful to assess the presence, location, and extent of the submucosal and intersphincteric abscesses and is a cost-effective method for documenting perirectal and perianal fluid collections. Other advantages to ultrasound include the absence of nonionizing radiation and bedside performance (49). Ultrasound techniques include endoanorectal, transperineal, and transvaginal approaches. MRI, like CT, is good at identifying deep abscesses, detecting granulation tissue, and separating the anatomical plains

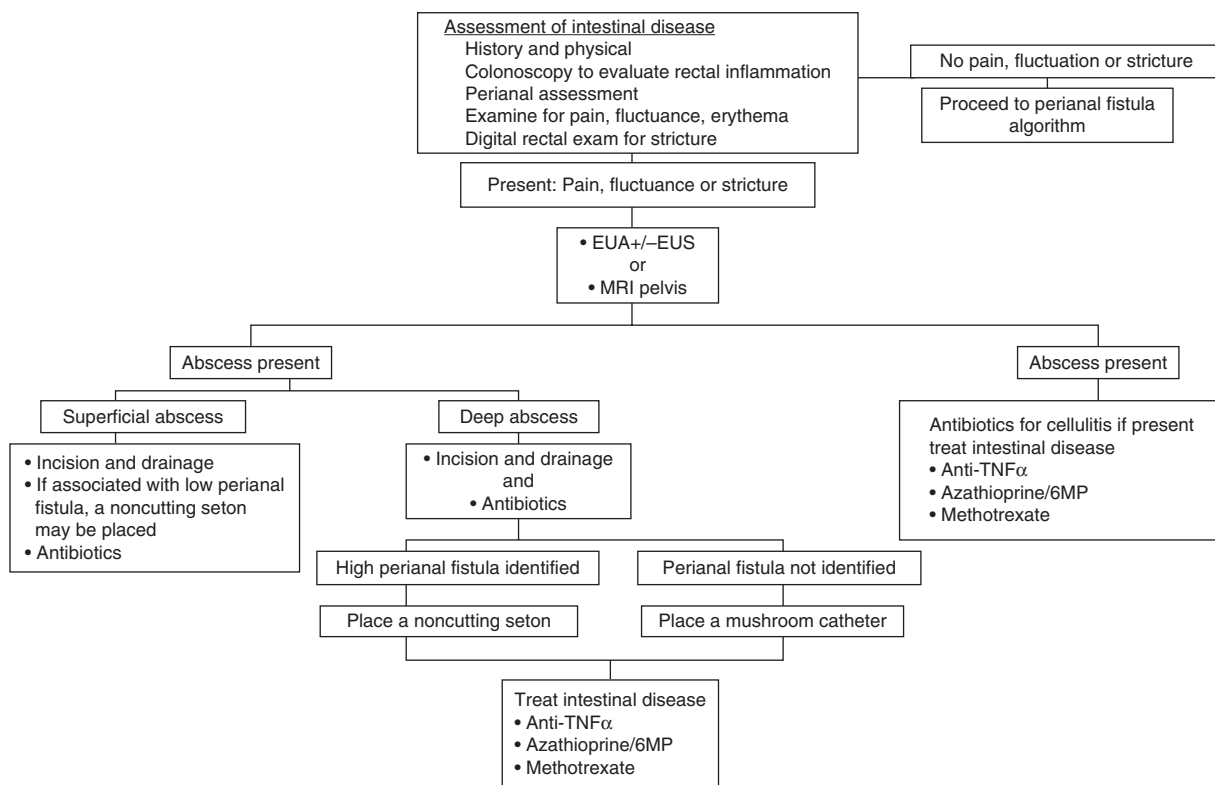


FIGURE 3. Perianal abscess—assessment and treatment algorithm.

more specifically than CT while avoiding radiation exposure (50). Most adult guidelines for evaluation of PA presently recommend some combination of EUA with pelvic MRI (Fig. 3).

Therapy for PCD

A decade ago, the goal of treatment for PF and PA was simply improvement in drainage. With the newer therapeutics, the aim is complete healing of abscesses and complete fistula closure with cessation of drainage (51). In addition, attention is focused on improved quality of life, decreased need for surgery, and prevention of recurrence.

The clinical assessment of healing in most studies is based on fistula drainage, for example, reduction of $\geq 50\%$ in the number of draining fistulae from baseline observed at ≥ 2 consecutive visits >4 weeks apart. Closure means no drainage despite gentle finger compression at examination, and remission is the absence of any drainage at 2 consecutive visits (31,52). No widely accepted scoring system to assess fistula activity exists, but many studies use a decrease in the Perianal Disease Activity Index (PDAI) as a secondary endpoint (53). Recent studies have used MRI to document fistula closure because track closure may lag behind clinical remission of luminal disease by months (54). It is important to recognize that this is a more rigorous endpoint for fistula healing.

Present treatment modalities are based on a combination of surgery, antibiotics, immunosuppressive agents, and biologics. No studies have shown benefit of sulfasalazine or 5-aminosalicylic acid agents in the treatment of PCD.

Corticosteroids

Corticosteroids must be used with caution in treatment of PF from CD. The presence of active proctitis decreases the chance

of fistula healing, and the use of steroids in these patients is aimed at treating luminal disease, not the fistulae; however, studies have shown worse outcomes in fistula activity in patients in steroid-treated groups (55).

Antibiotics

Despite the lack of strong evidence, antibiotics remain first-line therapy, especially in simple fistula or abscess. An adult clinical practice guideline published in 2003 revealed no controlled trials showing effectiveness, yet they remain a part of the recommendations and are part of numerous algorithms based on uncontrolled studies and case series (31). Bernstein et al (56) evaluated 21 adult patients with metronidazole ($20 \text{ mg} \cdot \text{kg}^{-1} \cdot \text{day}^{-1}$) and noted clinical response in all patients and complete healing with rapid onset of improvement in 56%. Unfortunately, a high rate of relapse upon discontinuation of metronidazole was noted and long-term metronidazole was associated with nausea, glossitis, metallic taste, peripheral neuropathy, and paresthesias (57). Because of these adverse effects, ciprofloxacin began to gain favor (58). Only anecdotal reports and small case series document the efficacy of ciprofloxacin. Eight adult patients who were initially resistant to metronidazole showed improvement on ciprofloxacin, but half continued to have persistent drainage (59). A randomized, double-blind, placebo-controlled study of 25 adult patients with actively draining fistulae randomized to ciprofloxacin (500 mg/day), metronidazole (500 mg), or placebo for 10 weeks resulted in higher response and remission in the ciprofloxacin group but was underpowered to show significance (60). Another study using a combination of ciprofloxacin and metronidazole showed effectiveness in severe disease, with two-thirds of patients showing response (61).

Antibiotic effectiveness as a bridge or adjuvant to other immunomodulatory therapy was evaluated in 2 studies. A prospective, open-label trial of ciprofloxacin (500–1000 mg/day) and/or metronidazole (1000–1500 mg/day) with azathioprine (2–2.5 mg/kg) showed some benefit for antibiotics as a bridge, with a response of 35% and complete healing in 18% at week 20. Patients taking the immunomodulator were more likely to respond, and those not bridged to azathioprine experienced a higher relapse rate (62). In addition, a double-blind, placebo-controlled study, in which all patients were induced with infliximab and randomized to receive ciprofloxacin or placebo for 12 weeks, showed a 73% response, with significant improvement in the PDAI in the antibiotic group compared with 39% in placebo-treated patients (63). No controlled pediatric studies have been performed to evaluate the use of antibiotics in PCD, and no studies to date have evaluated the efficacy of newer agents such as rifaximin on PCD.

Immunomodulators

Azathioprine/6-Mercaptopurine

Initial use of immunomodulators for PF was based on a meta-analysis of 5 controlled adult trials with closure as a secondary endpoint; however, no controlled trials exist with this outcome as the primary endpoint (3,64,65). The subanalysis of a pivotal adult trial by Present et al (63) revealed 24% with partial response and 31% with complete response in patients taking azathioprine, but time to response was delayed. A meta-analysis of 41 adult patients with PCD given either 6-mercaptopurine/azathioprine or placebo reported fistula healing in 54% on thiopurines versus 21% given placebo (66). The largest adult series evaluated 34 patients (18 with fistula) on 1.5 mg/kg 6-mercaptopurine, showing 39% with complete closure and 26% with clinical improvement (3). Multiple uncontrolled studies in children have been published. A retrospective review of a pediatric IBD registry revealed 75% of patients whose fistulae resolved were treated with immunomodulators before resolution (67). The pivotal Markowitz study evaluating the use of azathioprine or 6-mercaptopurine as maintenance therapy in CD included 40% with PCD before therapy with no new development, and only 14% reported to have disease during therapy (68). Kirschner et al (69) evaluated the safety of immunomodulators in pediatric CD and included 10 patients with fistulae; 3 had complete closure, 3 had a fluctuating course, and 4 had no change while receiving therapy. Another retrospective review of 15 pediatric patients with significant PF treated for >6 months with azathioprine resulted in 67% with improved drainage, 40% with fistula closure, and an improvement in PDAI (69). Although these studies suggest benefit, their slow onset of action has led the American Gastroenterological Association (AGA) to suggest these agents be used to maintain closure, rather than for induction (31).

Methotrexate

A few uncontrolled published trials have reported use of methotrexate in PF in adults; none reported use in pediatric patients. A retrospective study showed 44% with partial or complete closure after 6 months of therapy (70). A chart review of 16 patients receiving 3 months of intramuscular and then oral therapy reported complete closure in 25% and partial closure in 31% (70,71). More recently, a series evaluating a regimen of induction with infliximab followed by maintenance with methotrexate in 12 consecutive patients resulted in persistent complete closure in 4 (33%) and partial closure in 3 (25%) (71).

Enteral Therapy

Enteral therapy has been shown to be effective at both inducing and maintaining remission in CD, with limited data specific to PCD. An adult study by Day et al evaluated enteral nutrition as primary therapy and showed benefit in treating perianal disease, whether isolated or in combination with luminal disease (72). A report of 3 pediatric patients with PCD described successful induction of remission with primary enteral therapy and avoidance of steroids, infliximab, and repeat surgical procedures (73). Another case series of 6 adult patients receiving enteral therapy for routine management demonstrated improved fistula response in 4 patients and complete healing in 1 patient (74). A retrospective review of 112 adult patients with CD on an elemental diet reported achieving remission in 8 of 10 patients with fistula and 9 of 12 patients with general PCD; however, relapse occurred in all but 1 patient once normal food resumed (75).

Biologics

The introduction of anti-tumor necrosis factor (TNF) antibodies has clearly enhanced the management of PCD. A number of studies confirmed the benefit of anti-TNF agents in the induction and maintenance of PCD, including as an adjuvant to surgery. The AGA clinical practice guidelines state that anti-TNF agents are the treatment of choice in complex PF (31).

Infliximab

The initial study of infliximab in adult CD by Present et al included 94 adult patients with PF and showed that 62% had a reduction of $\geq 50\%$ from baseline in the number of draining fistulas and 55% had complete closure of all fistulae, with a median duration until closure of 12 weeks (76). An analysis of ACCENT II reviewed 195 patients with fistulizing CD and showed early benefit. A partial response at week 14 was shown in 64%, and at 54 weeks, a durable response was noted with partial response in 46% and complete response in 36% compared with 19% partial response in the placebo group. In addition, the treatment group showed decreased rates of hospitalizations, further surgeries, and procedures (77,78). A prospective study of 34 patients with PCD showed that 6 months of treatment led to a remission rate of 58% and a response rate of 37%, with a reduction of PDAI based on MRI findings and increased quality of life (54). An Italian study evaluated predictors of infliximab response in 190 patients with fistulizing disease; 72% of these patients had a 50% reduction of their fistula, and 41% had total closure; however, relapse was seen once infliximab was stopped (79). In addition, a study evaluating the evolution of CD after discontinuing infliximab showed that the probability of being relapse free after discontinuation at 12 months was 69%, but perianal disease resulted in earlier relapse, with only 34% maintaining remission after 1 year (80).

Various small pediatric studies with different dosing regimens have shown benefit of infliximab on PF (81,82). A post hoc analysis of the REACH trial revealed 22 patients with PCD at baseline; response rates were 41% at week 2 and 72% at week 54 (1 partial and 15 complete) (81). De Ridder (83) reviewed 16 pediatric patients with refractory CD and draining fistulae on infliximab and reported that 9 (56%) had long-term clinical response. A retrospective review of a pediatric IBD registry showed 70% of patients treated with infliximab within 3 months of diagnosis experienced resolution of the fistulae. More recently, a pediatric study evaluating the “top down” versus “step up” strategy noted significant improvement in PF in the top down group

(58% complete closure vs 17% in step up group) at 8 weeks and 50% (3/6) in the step up group compared with 100% (12/12) completely closed in the top down group at 1 year (84).

The combination of infliximab and surgery has been assessed, looking at the use of infliximab first, surgery first, and infliximab with interval EUA and seton (85). Two series evaluated infliximab before a primary drainage procedure, and both showed improved healing and decreased recurrence of fistulae compared with surgery alone (85,86). Another study evaluating a protocol of primary drainage or seton placement for abscesses or fistulae, followed by infliximab (average of 7.68 ± 7.85 doses given), then followed by seton removal and maintenance methotrexate resulted in an 85% response rate (74% complete response) that was maintained in 50% at 1 year and noted significant decrease in PDAI (87). In a retrospective review of 93 patients with fistula who had setons placed followed by infliximab, 70% were able to avoid further surgical treatment (88). Talbot et al (89) evaluated complex fistulae using a seton to maintain drainage and removal of the seton after the second dose of infliximab, which resulted in a partial response in all patients and complete healing in 47%. A similar study using EUS in 32 patients to guide seton placement and removal combined with infliximab had a complete response in 86%, and 76% maintained a long-term response (90).

Adalimumab

Several studies have been conducted on the effects of adalimumab on PCD in adults, yet none are reported in a pediatric population (91,92). The CHARM study included 130 patients with fistulae, in which 33% achieved long-term fistula closure at 56 weeks. An open-label extension of this study looked at the mean number of draining fistulae per day showing a significant increase in closure, with 41% healed at week 56 and 90% maintained after an additional year of treatment (92). Additional case reports and single-center studies have shown similar benefit.

Several studies have evaluated adalimumab following infliximab failure or intolerance. The GAIN study, in which patients have failed previous biologic therapy, had 45 patients enrolled with fistulae with no difference in improvement between adalimumab and placebo (93). In a single-center study with 54 patients who lost response to infliximab, complete closure was induced in 60%, which was sustained up to 3 years (94). A study from Spain in which 30% had active fistulizing disease, with 60% having previous infliximab exposure, resulted in complete response in 50% after 4 weeks and 87.5% maintained remission after 48 weeks (95). One case report of a patient who developed a fistula while taking infliximab documented complete closure with seton placement plus adalimumab (96).

Certolizumab

Fewer studies have evaluated certolizumab in treating PF in CD in adults, with no studies performed in children. In PRECISE2, 108 adults with PF were induced with 400 mg at baseline, week 2, and week 4 with significantly more patients with complete closure (36%) at week 26 than placebo; however, protocol-defined closure (>50% closure at 2 consecutive visits) was not significant, thus concluding it did not improve the likelihood of sustained closure (97). The FACTS survey evaluated complex CD, including 56% with fistulae or stricture, and many of these patients had previous immunomodulator and/or biologic exposure (98). Of those with PF, disease activity significantly decreased; 54% with fistula had a response to treatment, and 40% of those fistulae went into remission.

Tacrolimus

A few studies report on the role of tacrolimus in PF. The AGA guidelines do not recommend this therapy in simple fistulae because of toxicity, but its role appears to be in those failing multimodality treatment (31). A single, short-term, placebo-controlled trial with 46 patients had a 43% response rate compared with 8% of placebo, with no difference in complete closure response and a high rate of nephrotoxicity being noted (99); however, in 15 patients previously treated with infliximab, 47% did improve on tacrolimus (100). In an open-label, nonrandomized study evaluating 10 patients with fistulae refractory to infliximab, 40% had complete response and 50% had partial response based on the PCAI and an MRI-based scoring system (101).

Topical tacrolimus (0.5 mg/g applied twice daily) was studied in 19 patients (12 with fistulizing and 7 with ulcerating perianal disease) showing no benefit compared with placebo (102); however, a small retrospective study showed efficacy in 6 of 7 children with PCD using topical tacrolimus (103).

Cyclosporine

No controlled trials have been performed illustrating efficacy in PCD, although several uncontrolled trials have shown benefit. Ten adult trials in a total of 64 patients given $4 \text{ mg} \cdot \text{kg}^{-1} \cdot \text{day}^{-1}$ of intravenous cyclosporine have been conducted, with an initial rapid response rate of up to 83% (104). Unfortunately, its use is limited by a high relapse rate once the drug is discontinued. Because of this, it has been typically used as rescue therapy to induce closure followed by oral cyclosporine for 4 to 6 months to bridge to another immunomodulator (105). A study of 20 patients evaluated this protocol with initial intravenous therapy followed by oral cyclosporine with 80% to 85% showing acute symptomatic improvement, 25% with improvement of the lesion, and 45% with closure of the fistula 20 months following initiation of treatment (106).

Thalidomide

Some uncontrolled series indicated that thalidomide may be effective treatment for PCD, but severe adverse effects were common. An open series, in which 6 of 12 patients had fistulae, showed improvement in 5 patients (107). In a retrospective review of 11 patients, 9 (82%) reported at least 50% improvement of draining fistulae and 3 (27%) had complete closure (106). A single study of lenalidomide (a thalidomide analog with less teratogenicity) showed a trend toward efficacy in fistulizing disease, but the study was limited by a small sample size (108).

Granulocyte Colony-Stimulating Factor

Two studies evaluated the use of granulocyte colony-stimulating factor (GCSF) for severe complicated CD, which included PF. A study of 5 patients with severe ileitis following intestinal resection given 300 mg GCSF subcutaneously 3 times per week for 12 weeks resulted in closure of both an anovaginal and perianal fistula in 1 patient (109). Another open-labeled study using GCSF in 20 patients with CD, 4 of which had PF, identified a response (closure of 50% of the fistulae) in 3 of 4 of the treated patients (110).

Mycophenolate Mofetil

A single published study evaluated 20 adult patients with complicated Crohn disease (8 with fistula) treated with 1 g

of mycophenolate mofetil BID for up to 7 years with improvement in 7 of the 8; however, relapse was common once therapy was discontinued (109).

In summary, current recommendations for medical therapy of PF include antibiotics, immunomodulators and infliximab (Fig. 1), whereas PA are generally treated with surgical drainage followed by antibiotics and in the case of deep abscesses medical treatment of intestinal disease with infliximab (Fig. 3).

Surgical Aspects of PCD

Many patients with PCD eventually come to the attention of the pediatric or colorectal surgeon for EUA, relief of symptoms, or definitive treatment. Here we discuss surgical intervention for PCD.

Therapeutic Surgical Intervention

As a general rule, the success of traditional surgical techniques (incising, mobilizing tissue flaps, suturing) in the setting of active tissue inflammation is extremely limited. This is because the risk of creating large, poorly healing wounds and more complications is high (111); however, patients who have responded well to medical therapy, although now candidates for surgical repair, rarely have persistent manifestations that require complex or elaborate interventions. Therefore, in the presence of active inflammation, surgery, whether for PA or PF, should be limited if possible to draining abscesses and relieving acute symptoms. Once the inflammation has resolved, surgery may be planned electively to deal with strictures and chronic fistula.

Surgery and PA

A PA cavity should always be evacuated (112). Most abscesses are near the skin (“pointing”) and can be incised and drained through a small skin incision. A silastic drain of a size appropriate to maintain adequate drainage should be placed after the cavity has been completely evacuated of pus, debris, and granulation tissue. It is almost never necessary to “pack” an abscess cavity with gauze—in most cases this is ineffective, associated with complications, and simply extremely painful. Although sometimes difficult to identify, every abscess should be assumed to have an associated internal fistulous opening. Abscesses drained “internally” by making an incision within the anal canal or rectum without making an additional skin incision will usually quickly recur and need to be drained again. Although it is certainly true that the internal and external fistulous tracts will evolve into a true fistula even after the abscess heals, a controlled fistula, open and draining both internally and externally is far preferable to an uncontrolled fistula, which will be a persistent source of recurring abscesses. In fact, when draining an abscess, it is helpful to pass a heavy silk or braided nylon thread through both the internal and external openings of a new or established fistula and to tie it loosely to itself in the manner of a seton. It can be used to secure the silastic drain—thus avoiding the use of skin sutures—and can be kept in place indefinitely to control the fistula, decreasing the likelihood of a recurrent abscess. Most silastic drains can be removed in 2 to 3 weeks, and in most cases antibiotics are continued for 10 to 14 days beyond the removal of the drain.

Surgery and Perianal Fistula

Setons are useful because they keep the fistulae open, presumably allowing the egress of colonized fluid and preventing

abscess formation. The seton does delay fistula healing and closure, but infliximab may be given while a seton is in place. One strategy is to place setons in patients with a known fistulae who are about to start therapy with infliximab, specifically for the prevention of an abscess while on therapy (113). Noncutting setons are the rule because “cutting” setons, which were sequentially tightened at regular intervals until they cut through the enclosed tissue, are considered a dangerous remnant of a bygone era because of the damage they can cause to the anal sphincters and resulting incontinence.

Setons can be left in place indefinitely and usually deteriorate and fall out on their own in about 1 year. They are well tolerated by most patients and they cause no long-term harm. If there are persistent signs of inflammation or infection, it is best to replace them every 6 months. Patients who have responded well to infliximab will generally have the seton removed, which can be done easily and painlessly in the physician’s office. After removal of the seton, medical therapy should be continued.

Setons are generally reserved for the complex fistulae. Simple fistulae can be opened (fistulotomy) or excised (fistulectomy) and either left open to heal by secondary intention or closed with suture with or without a drain. The patient with no signs of active inflammation or infection but who has a persistent fistula (most fistulae will heal when the underlying inflammation has resolved) could be considered for direct surgical repair (114); however, such an approach for a complex fistula increases the risk of sphincter injury and incontinence. Stubborn fistulae that persist despite otherwise effective medical therapy have been treated successfully with fibrin plug (115) or injection of fibrin glue (116), although the efficacy of these remains questionable and multiple attempts are often necessary. Numerous surgical procedures are described for the creation of advancement flaps, especially for women with a rectovaginal fistula. Surgery should be approached with caution because in the presence of active inflammation, these complex operations are usually doomed to fail, and in the absence of active inflammation, they are usually not necessary.

Ostomy Diversion

Patients with severe PCD or complications may benefit from colostomy or ileostomy diversion. Some are able to subsequently heal enough to have the ostomy reversed; however, the risk of the ostomy becoming permanent is significant. Diversion is especially useful for the treatment of refractory infectious complications (cellulitis, recurrent abscesses, destructive deep infections) but sometimes disappointingly ineffective at reducing the progression of the inflammatory and fibrotic aspects of the disease (fissures, fistulae, or stricture) (117). Patients with minimal colitis can have a sigmoid (left lower quadrant) colostomy, whereas others will require an ileostomy (right lower quadrant). Transverse colostomies and other ostomies created above the level of the umbilicus are difficult to manage and cosmetically unappealing. Patients who have complete resolution of their PCD or manageable sequelae (skin tags, epithelialized chronic fistulae) can be considered for ostomy closure, but this is typically only a consideration after 6 to 12 months. This type of patient should also be warned about the high likelihood of recurrent symptoms and the possible need for another diversion.

PF and PA can be a frustrating and painful manifestation of CD, with significant deleterious effects on the patient’s self-image and quality of life. Like all CD, treatment is primarily medical. Surgical intervention, although rarely curative, is useful for assessment of the extent of disease and helping to manage

complications. The goals of the surgeon should be to control sepsis, relieve discomfort, and help maintain good function so that children and adolescents with the disease can have a normal lifestyle and avoid long-term complications.

Other Perianal Complications of CD

Skin Tags

Anal skin tags (ASTs) are commonly associated with CD and can precede intestinal disease by months or years (118,119). ASTs are generally fleshy and sometimes pendulous in appearance and associated with fissures. Evidence about the association of ASTs with activity of disease is conflicting. Skin tags have been classified into 2 categories: type 1 “elephant ears” and type 2 arising from healed ulcers, fissures, or hemorrhoids (120). Noninflamed ASTs are rarely painful, rarely require treatment, and should not be excised—the subsequent wound may heal poorly and the skin tag will typically recur. In patients with ASTs but whose diagnosis of CD is uncertain, a skin tag may be excised for biopsy purposes because they have been found to harbor the granulomas diagnostic of CD in up to 30% of patients (121). In general, however, they should be left alone.

Anal Fissures

Fissures make up approximately 20% to 30% of anal lesions in PCD. Fissures in patients with CD tend to be broad-based, have undermining edges, and are most often found posteriorly. Associated symptoms include discharge, pruritus, and bleeding. An anal fissure may be an external sign raising suspicion for PA or PF. Fissures suggest active CD and are therefore treated medically. It is occasionally necessary to gently debride a fissure when the granulating bed is filled with necrotic tissue, debris, or thick exudate. In the presence of acute inflammation (robust granulation tissue, induration), it is futile and potentially dangerous to attempt to excise a fissure or close it with suture. The repair is extremely unlikely to heal and the resulting wound will be larger and more inflamed than that upon presentation. Fortunately, the discomfort associated with fissures is rarely debilitating and they typically respond to effective medical therapy using nitrate-based ointments (122), and sitz baths. No controlled trials show any efficacy of oral antibiotics in the treatment of perianal fissures.

Rectal Strictures

Rectal strictures occur in a small subset of pediatric patients with CD; evaluation of the adult data suggests that these strictures are a predictor of poor outcome (25) and have been noted in 7% to 9% of adult patients with IBD. Stricture may be more common but asymptomatic, and diagnosis is often delayed until other PCD develops. In 1 study, up to 50% of strictures were noted in the rectum and 34% in the anus and a majority of these were associated with proctitis (123). Rectal strictures vary in degree (caliber of the opening), extent (location and length), and response to therapy. They result from circumferential rectal or anal inflammation either when it has been present for a long time or, ironically, after the inflammation has resolved in response to therapy. They are most commonly located at the dentate line (distal rectum), but can occur in the mid-rectum or proximal rectum. They can occasionally occur only in the anal canal, in which they resemble a fibrotic dermal stricture, or they can be extremely long, involving essentially the entire length of the rectum.

Most patients respond to anal dilatation, but this almost always requires a general anesthetic and typically needs to be

repeated at frequent intervals, sometimes indefinitely. No surgical procedure allows one to definitively resect, remove, or otherwise permanently open a rectal stricture. Anal dilatation is most easily performed using cervical dilators, starting with the largest one that can be inserted easily, and progressing stepwise up to a minimum of 18 mm, if possible, or, in adolescents and young adults, up to 24 to 26 mm in diameter. The goal is to gradually and gently stretch the fibrotic ring. Some tearing (and brisk bleeding) is inevitable but excessive tearing is thought to create more scar tissue and therefore worsening of the stricture. Some patients can be taught to dilate themselves at home with smaller dilator (15–16 mm), but few patients can seem to do so regularly and successfully. Dilatation is safe, although dilatation of proximal strictures carries a significant risk of perforation into the abdomen and subsequent peritonitis. Patients with tight, long, or refractory strictures should be considered for ostomy diversion and proctectomy.

SUMMARY

PCD is a severe and debilitating manifestation of CD, yet despite our increased understanding of CD, this issue remains poorly studied. Our present knowledge remains in its infancy and also leaves opportunities for further research. Present concepts include proper diagnosis and classification using imaging and EUA, followed by treatment with antibiotics, immunomodulators, and/or a biologic. Although evaluation by a surgeon is important for understanding the extent of patient issues, extensive surgical intervention should be undertaken with caution.

REFERENCES

- Bach JF. The effect of infections on susceptibility to autoimmune and allergic diseases. *N Engl J Med* 2002;347:911–20.
- Bissell AD. Localized chronic ulcerative ileitis. *Ann Surg* 1934;99:957–66.
- Keljo DJ, Markowitz J, Langton C, et al. Course and treatment of perianal disease in children newly diagnosed with Crohn's disease. *Inflamm Bowel Dis* 2009;15:383–7.
- Palder SB, Shandling B, Bilik R, et al. Perianal complications of pediatric Crohn's disease. *J Pediatr Surg* 1991;26:513–5.
- Eglinton TW, Roberts R, Pearson J, et al. Clinical and genetic risk factors for perianal Crohn's disease in a population-based cohort. *Am J Gastroenterol* 2012;107:589–96.
- Vermeire S, Van Assche G, Rutgeerts P. Perianal Crohn's disease: classification and clinical evaluation. *Dig Liver Dis* 2007;39:959–62.
- Farmer RG, Hawk WA, Turnbull RB Jr. Clinical patterns in Crohn's disease: a statistical study of 615 cases. *Gastroenterology* 1975;68:627–35.
- Williams DR, Collier JA, Corman ML, et al. Anal complications in Crohn's disease. *Dis Colon Rectum* 1981;24:22–4.
- Goebell H. Perianal complications in Crohn's disease. *Neth J Med* 1990;37(Suppl 1):S47–51.
- Halme L, Sainio AP. Factors related to frequency, type, and outcome of anal fistulas in Crohn's disease. *Dis Colon Rectum* 1995;38:55–9.
- Judge TA, Lichtenstein GR. Treatment of fistulizing Crohn's disease. *Gastroenterol Clin North Am* 2004;33:421–54xi–xiii.
- Hughes LE. Surgical pathology and management of anorectal Crohn's disease. *J R Soc Med* 1978;71:644–51.
- Parks AG. Pathogenesis and treatment of fistula-in-ano. *Br Med J* 1961;1:463–9.
- Vermeire S, Pierik M, Hlavaty T, et al. Association of organic cation transporter risk haplotype with perianal penetrating Crohn's disease but not with susceptibility to IBD. *Gastroenterology* 2005;129:1845–53.
- Latiano A, Palmieri O, Cucchiara S, et al. Polymorphism of the IRGM gene might predispose to fistulizing behavior in Crohn's disease. *Am J Gastroenterol* 2009;104:110–6.

16. Armuzzi A, Ahmad T, Ling KL, et al. Genotype-phenotype analysis of the Crohn's disease susceptibility haplotype on chromosome 5q31. *Gut* 2003;52:1133–9.
17. Brant SR, Picco MF, Achkar JP, et al. Defining complex contributions of NOD2/CARD15 gene mutations, age at onset, and tobacco use on Crohn's disease phenotypes. *Inflamm Bowel Dis* 2003;9:281–9.
18. Angelberger S, Reinisch W, Dejaco C, et al. NOD2/CARD15 gene variants are linked to failure of antibiotic treatment in perianal fistulating Crohn's disease. *Am J Gastroenterol* 2008;103:1197–202.
19. Masseret E, Boudeau J, Colombel JF, et al. Genetically related *Escherichia coli* strains associated with Crohn's disease. *Gut* 2001;48:320–5.
20. Chen W, Li D, Wilson I, et al. Detection of *Chlamydia pneumoniae* by polymerase chain reaction-enzyme immunoassay in intestinal mucosal biopsies from patients with inflammatory bowel disease and controls. *J Gastroenterol Hepatol* 2002;17:987–93.
21. Romero C, Hamdi A, Valentine JF, et al. Evaluation of surgical tissue from patients with Crohn's disease for the presence of *Mycobacterium avium* subspecies *paratuberculosis* DNA by in situ hybridization and nested polymerase chain reaction. *Inflamm Bowel Dis* 2005;11:116–25.
22. Seow-Choen F, Hay AJ, Heard S, et al. Bacteriology of anal fistulae. *Br J Surg* 1992;79:27–8.
23. West RL, Van der Woude CJ, Endtz HP, et al. Perianal fistulas in Crohn's disease are predominantly colonized by skin flora: implications for antibiotic treatment? *Dig Dis Sci* 2005;50:1260–3.
24. Tolia V. Perianal Crohn's disease in children and adolescents. *Am J Gastroenterol* 1996;91:922–6.
25. Fields S, Rosainz L, Korelitz BI, et al. Rectal strictures in Crohn's disease and coexisting perirectal complications. *Inflamm Bowel Dis* 2008;14:29–31.
26. Hughes LE. Clinical classification of perianal Crohn's disease. *Dis Colon Rectum* 1992;35:928–32.
27. Francois Y, Vignal J, Descos L. Outcome of perianal fistulae in Crohn's disease—value of Hughes' pathogenic classification. *Int J Colorectal Dis* 1993;8:39–41.
28. Parks AG, Gordon PH, Harcastle JD. A classification of fistula-in-ano. *Br J Surg* 1976;63:1–12.
29. Bell SJ, Williams AB, Wiesel P, et al. The clinical course of fistulating Crohn's disease. *Aliment Pharmacol Ther* 2003;17:1145–51.
30. Pikarsky AJ, Gervaz P, Wexner SD. Perianal Crohn disease: a new scoring system to evaluate and predict outcome of surgical intervention. *Arch Surg* 2002;137:774–7discussion 778.
31. Sandborn WJ, Fazio VW, Feagan BG, et al. AGA technical review on perianal Crohn's disease. *Gastroenterology* 2003;125:1508–30.
32. Schwartz DA, Wiersma MJ, Dudiak KM, et al. A comparison of endoscopic ultrasound, magnetic resonance imaging, and exam under anesthesia for evaluation of Crohn's perianal fistulas. *Gastroenterology* 2001;121:1064–72.
33. Lewis RT, Maron DJ. Anorectal Crohn's disease. *Surg Clin North Am* 2010;90:83–97.
34. Mackalski BA, Bernstein CN. New diagnostic imaging tools for inflammatory bowel disease. *Gut* 2006;55:733–41.
35. Dagia C, Ditchfield M, Kean M, et al. Feasibility of 3-T MRI for the evaluation of Crohn disease in children. *Pediatr Radiol* 2010;40:1615–24.
36. Darbari A, Sena L, Argani P, et al. Gadolinium-enhanced magnetic resonance imaging: a useful radiological tool in diagnosing pediatric IBD. *Inflamm Bowel Dis* 2004;10:67–72.
37. Essary B, Kim J, Anupindi S, et al. Pelvic MRI in children with Crohn disease and suspected perianal involvement. *Pediatr Radiol* 2007;37:201–8.
38. Laghi A, Borrelli O, Paolantonio P, et al. Contrast enhanced magnetic resonance imaging of the terminal ileum in children with Crohn's disease. *Gut* 2003;52:393–7.
39. Magnano G, Granata C, Barabino A, et al. Polyethylene glycol and contrast-enhanced MRI of Crohn's disease in children: preliminary experience. *Pediatr Radiol* 2003;33:385–91.
40. Bartram C, Buchanan G. Imaging anal fistula. *Radiol Clin North Am* 2003;41:443–57.
41. Halligan S, Stoker J. Imaging of fistula in ano. *Radiology* 2006;239:18–33.
42. Horsthuis K, Stoker J. MRI of perianal Crohn's disease. *AJR Am J Roentgenol* 2004;183:1309–15.
43. Morris J, Spencer JA, Ambrose NS. MR imaging classification of perianal fistulas and its implications for patient management. *Radiographics* 2000;20:623–37.
44. Szurowska E, Wypych J, Izycka-Swieszezewska E. Perianal fistulas in Crohn's disease: MRI diagnosis and surgical planning: MRI in fistulizing perianal Crohn's disease. *Abdom Imaging* 2007;32:705–18.
45. Hagggett PJ, Moore NR, Shearman JD, et al. Pelvic and perineal complications of Crohn's disease: assessment using magnetic resonance imaging. *Gut* 1995;36:407–10.
46. Schwartz DA, Loftus EV Jr, Tremaine WJ, et al. The natural history of fistulizing Crohn's disease in Olmsted County, Minnesota. *Gastroenterology* 2002;122:875–80.
47. Caprilli R, Gassull MA, Escher JC, et al. European evidence based consensus on the diagnosis and management of Crohn's disease: special situations. *Gut* 2006;55(suppl 1):i36–58.
48. Liechty R, Soper R. *Fundamentals of Surgery. Anorectum. 6th ed.* St Louis: CV Mosby; 1983:244–50.
49. Stewart LK, McGee J, Wilson SR. Transperineal and transvaginal sonography of perianal inflammatory disease. *AJR Am J Roentgenol* 2001;177:627–32.
50. Cuenod CA, de Parades V, Siauue N, et al. MR imaging of ano-perineal suppurations. *J Radiol* 2003;84:516–28.
51. Vavricka SR, Rogler G. Fistula treatment: the unresolved challenge. *Dig Dis* 2010;28:556–64.
52. Bernstein LH, Frank MS, Brandt LJ, et al. Healing of perineal Crohn's disease with metronidazole. *Gastroenterology* 1980;79:599.
53. Irvine EJ. Usual therapy improves perianal Crohn's disease as measured by a new disease activity index. McMaster IBD Study Group. *J Clin Gastroenterol* 1995;20:27–32.
54. Ng SC, Plamondon S, Gupta A, et al. Prospective evaluation of anti-tumor necrosis factor therapy guided by magnetic resonance imaging for Crohn's perineal fistulas. *Am J Gastroenterol* 2009;104:2973–86.
55. Malchow H, Ewe K, Brandes JW, et al. European Cooperative Crohn's Disease Study (ECCDS): results of drug treatment. *Gastroenterology* 1984;86:249–66.
56. Bernstein LH, Frank MS, Brandt LJ, et al. Healing of perineal Crohn's disease with metronidazole. *Gastroenterology* 1980;79:357–65.
57. Brandt LJ, Bernstein LH, Boley SJ, et al. Metronidazole therapy for perineal Crohn's disease: a follow-up study. *Gastroenterology* 1982;83:383–7.
58. Peppercorn MA. Is there a role for antibiotics as primary therapy in Crohn's ileitis? *J Clin Gastroenterol* 1993;17:235–7.
59. Turunen UFM, Seppala K. Long-term treatment of peri-anal or fistulous Crohn's disease with ciprofloxacin. *Scand J Gastroenterol* 1989;24:144.
60. Thia KT, Mahadevan U, Feagan BG, et al. Ciprofloxacin or metronidazole for the treatment of perianal fistulas in patients with Crohn's disease: a randomized, double-blind, placebo-controlled pilot study. *Inflamm Bowel Dis* 2009;15:17–24.
61. Solomon M, McLeod R, O'Conner B, et al. Combination ciprofloxacin and metronidazole in severe perianal Crohn's disease. *Can J Gastroenterol* 1993;7:571–3.
62. West RL, van der Woude CJ, Hansen BE, et al. Clinical and endosonographic effect of ciprofloxacin on the treatment of perianal fistulae in Crohn's disease with infliximab: a double-blind placebo-controlled study. *Aliment Pharmacol Ther* 2004;20:1329–36.
63. Freire P, Portela F, Donato MM, et al. CARD15 mutations and perianal fistulating Crohn's disease: correlation and predictive value of antibiotic response. *Dig Dis Sci* 2010;56:853–9.
64. Tozer PJ, Burling D, Gupta A, et al. Review article: medical, surgical and radiological management of perianal Crohn's fistulas. *Aliment Pharmacol Ther* 2010;33:5–22.
65. O'Brien JJ, Bayless TM, Bayless JA. Use of azathioprine or 6-mercaptopurine in the treatment of Crohn's disease. *Gastroenterology* 1991;101:39–46.
66. Korelitz BI, Present DH. Favorable effect of 6-mercaptopurine on fistulae of Crohn's disease. *Dig Dis Sci* 1985;30:58–64.
67. Jeshion WC, Larsen KL, Jawad AF, et al. Azathioprine and 6-mercaptopurine for the treatment of perianal Crohn's disease in children. *J Clin Gastroenterol* 2000;30:294–8.

68. Hyams JS, Lerer T, Mack D, et al. Pediatric Inflammatory Bowel Disease Collaborative Research Group R. Outcome following thiopurine use in children with ulcerative colitis: a prospective multicenter registry study. *Am J Gastroenterol* 2011;106:981–7.
69. Kirschner BS. Safety of azathioprine and 6-mercaptopurine in pediatric patients with inflammatory bowel disease. *Gastroenterology* 1998;115:813–21.
70. Mahadevan U, Marion JF, Present DH. Fistula response to methotrexate in Crohn's disease: a case series. *Aliment Pharmacol Ther* 2003;18:1003–8.
71. Schroder O, Blumenstein I, Schulte-Bockholt A, et al. Combining infliximab and methotrexate in fistulizing Crohn's disease resistant or intolerant to azathioprine. *Aliment Pharmacol Ther* 2004;19:295–301.
72. Day AS, Whitten KE, Lemberg DA, et al. Exclusive enteral feeding as primary therapy for Crohn's disease in Australian children and adolescents: a feasible and effective approach. *J Gastroenterol Hepatol* 2006;21:1609–14.
73. Wong S, Lemberg DA, Day AS. Exclusive enteral nutrition in the management of perianal Crohn's disease in children. *J Dig Dis* 2010;11:185–8.
74. Calam J, Crooks PE, Walker RJ. Elemental diets in the management of Crohn's perianal fistulae. *JPEN J Parenter Enteral Nutr* 1980;4:4–8.
75. Teahon K, Bjarnason I, Pearson M, et al. Ten years' experience with an elemental diet in the management of Crohn's disease. *Gut* 1990;31:1133–7.
76. Present DH, Rutgeerts P, Targan S, et al. Infliximab for the treatment of fistulas in patients with Crohn's disease. *N Engl J Med* 1999;340:1398–405.
77. Sands BE, Blank MA, Diamond RH, et al. Maintenance infliximab does not result in increased abscess development in fistulizing Crohn's disease: results from the ACCENT II study. *Aliment Pharmacol Ther* 2006;23:1127–36.
78. Lichtenstein GR, Yan S, Bala M, et al. Infliximab maintenance treatment reduces hospitalizations, surgeries, and procedures in fistulizing Crohn's disease. *Gastroenterology* 2005;128:862–9.
79. Domenech E, Hinojosa J, Nos P, et al. Clinical evolution of luminal and perianal Crohn's disease after inducing remission with infliximab: how long should patients be treated? *Aliment Pharmacol Ther* 2005;22:1107–13.
80. Cezard JP, Nouail N, Talbotec C, et al. A prospective study of the efficacy and tolerance of a chimeric antibody to tumor necrosis factors (remicade) in severe pediatric crohn disease. *J Pediatr Gastroenterol Nutr* 2003;36:632–6.
81. Crandall W, Hyams J, Kugathasan S, et al. Infliximab therapy in children with concurrent perianal Crohn disease: observations from REACH. *J Pediatr Gastroenterol Nutr* 2009;49:183–90.
82. Rummel FM, Lachaux A, Cezard JP, et al. Efficacy of infliximab in pediatric Crohn's disease: a randomized multicenter open-label trial comparing scheduled to on demand maintenance therapy. *Inflamm Bowel Dis* 2009;15:388–94.
83. de Ridder L, Escher JC, Bouquet J, et al. Infliximab therapy in 30 patients with refractory pediatric crohn disease with and without fistulas in The Netherlands. *J Pediatr Gastroenterol Nutr* 2004;39:46–52.
84. Kim MJ, Lee JS, Lee JH, et al. Infliximab therapy in children with Crohn's disease: a one-year evaluation of efficacy comparing 'top-down' and 'step-up' strategies. *Acta Paediatr* 2010;100:451–5.
85. Roumequere P, Bouchard D, Pigot F, et al. Combined approach with infliximab, surgery, and methotrexate in severe fistulizing anoperineal Crohn's disease: results from a prospective study. *Inflamm Bowel Dis* 2010;17:69–76.
86. van der Hagen SJ, Baeten CG, Soeters PB, et al. Anti-TNF-alpha (infliximab) used as induction treatment in case of active proctitis in a multistep strategy followed by definitive surgery of complex anal fistulas in Crohn's disease: a preliminary report. *Dis Colon Rectum* 2005;48:758–67.
87. Higashi D, Futami K, Egawa Y, et al. Infliximab treatment for anal fistula in patients with Crohn's disease. *Anticancer Res* 2009;29:927–33.
88. Talbot C, Sagar PM, Johnston MJ, et al. Infliximab in the surgical management of complex fistulating anal Crohn's disease. *Colorectal Dis* 2005;7:164–8.
89. Schwartz DA, White CM, Wise PE, et al. Use of endoscopic ultrasound to guide combination medical and surgical therapy for patients with Crohn's perianal fistulas. *Inflamm Bowel Dis* 2005;11:727–32.
90. Colombel JF, Sandborn WJ, Rutgeerts P, et al. Adalimumab for maintenance of clinical response and remission in patients with Crohn's disease: the CHARM trial. *Gastroenterology* 2007;132:52–65.
91. Kouklakis G, Efremidou EI, Zazos P, et al. Adalimumab—an effective and promising treatment for patients with fistulizing Crohn's disease: a case series. *J Med Case Rep* 2011;5:109.
92. Colombel JF, Schwartz DA, Sandborn WJ, et al. Adalimumab for the treatment of fistulas in patients with Crohn's disease. *Gut* 2009;58:940–8.
93. Sandborn WJ, Rutgeerts P, Enns R, et al. Adalimumab induction therapy for Crohn disease previously treated with infliximab: a randomized trial. *Ann Intern Med* 2007;146:829–38.
94. Peyrin-Biroulet L, Laclotte C, Bigard MA. Adalimumab maintenance therapy for Crohn's disease with intolerance or lost response to infliximab: an open-label study. *Aliment Pharmacol Ther* 2007;25:675–80.
95. Echarri A, Castro J, Barreiro M, et al. Evaluation of adalimumab therapy in multidisciplinary strategy for perianal Crohn's disease patients with infliximab failure. *J Crohns Colitis* 2010;4:654–60.
96. Tursi A, Papa A, Maiorano M. Onset of severe perianal disease in Crohn's disease under treatment with infliximab: successful treatment with adalimumab and setons drainage. *Inflamm Bowel Dis* 2011;17:676–8.
97. Schreiber S, Lawrance IC, Thomsen OO, et al. Randomised clinical trial: certolizumab pegol for fistulas in Crohn's disease—subgroup results from a placebo-controlled study. *Aliment Pharmacol Ther* 2010;33:185–93.
98. Schoepfer AM, Vavricka SR, Binek J, et al. Efficacy and safety of certolizumab pegol induction therapy in an unselected Crohn's disease population: results of the FACTS survey. *Inflamm Bowel Dis* 2009;16:933–8.
99. Sandborn WJ, Present DH, Isaacs KL, et al. Tacrolimus for the treatment of fistulas in patients with Crohn's disease: a randomized, placebo-controlled trial. *Gastroenterology* 2003;125:380–8.
100. Gonzalez-Lama Y, Abreu L, Vera MI, et al. Long-term oral tacrolimus therapy in refractory to infliximab fistulizing Crohn's disease: a pilot study. *Inflamm Bowel Dis* 2005;11:8–15.
101. Hart AL, Plamondon S, Kamm MA. Topical tacrolimus in the treatment of perianal Crohn's disease: exploratory randomized controlled trial. *Inflamm Bowel Dis* 2007;13:245–53.
102. Casson DH, Eltumi M, Tomlin S, et al. Topical tacrolimus may be effective in the treatment of oral and perineal Crohn's disease. *Gut* 2000;47:436–40.
103. Niyogi A, Agarwal T, Broadhurst J, et al. Management of perianal abscess and fistula-in-ano in children. *Eur J Pediatr Surg* 2009;20:35–9.
104. Bressler B, Sands BE. Review article: medical therapy for fistulizing Crohn's disease. *Aliment Pharmacol Ther* 2006;24:1283–93.
105. Egan LJ, Sandborn WJ, Tremaine WJ. Clinical outcome following treatment of refractory inflammatory and fistulizing Crohn's disease with intravenous cyclosporine. *Am J Gastroenterol* 1998;93:442–8.
106. Present DH, Lichtiger S. Efficacy of cyclosporine in treatment of fistula of Crohn's disease. *Dig Dis Sci* 1994;39:374–80.
107. Ehrenpreis ED, Kane SV, Cohen LB, et al. Thalidomide therapy for patients with refractory Crohn's disease: an open-label trial. *Gastroenterology* 1999;117:1271–7.
108. Mansfield JC, Parkes M, Hawthorne AB, et al. A randomized, double-blind, placebo-controlled trial of lenalidomide in the treatment of moderately severe active Crohn's disease. *Aliment Pharmacol Ther* 2007;26:421–30.
109. Dejaco C, Lichtenberger C, Miehsler W, et al. An open-label pilot study of granulocyte colony-stimulating factor for the treatment of severe endoscopic postoperative recurrence in Crohn's disease. *Digestion* 2003;68:63–70.
110. Korzenik JR, Dieckgraefe BK. An open-labelled study of granulocyte colony-stimulating factor in the treatment of active Crohn's disease. *Aliment Pharmacol Ther* 2005;21:391–400.

111. Strong SA. Perianal Crohn's disease. *Semin Pediatr Surg* 2007; 16:185–93.
112. Steele SR. Operative management of Crohn's disease of the colon including anorectal disease. *Surg Clin North Am* 2007;87: 611–31.
113. Regueiro M, Mardini H. Treatment of perianal fistulizing Crohn's disease with infliximab alone or as an adjunct to exam under anesthesia with seton placement. *Inflamm Bowel Dis* 2003;9:98–103.
114. Singh B, George BD, Mortensen NJ. Surgical therapy of perianal Crohn's disease. *Dig Liver Dis* 2007;39:988–92.
115. Schwandner O, Fuerst A. Preliminary results on efficacy in closure of transsphincteric and rectovaginal fistulas associated with Crohn's disease using new biomaterials. *Surg Innov* 2009; 16:162–8.
116. Vitton V, Gasmi M, Barthet M, et al. Long-term healing of Crohn's anal fistulas with fibrin glue injection. *Aliment Pharmacol Ther* 2005; 21:1453–7.
117. Yamamoto T, Allan RN, Keighley MR. Effect of fecal diversion alone on perianal Crohn's disease. *World J Surg* 2000;24:1258–62discussion 1262–3.
118. Morales MS, Marini M, Caminero M, et al. Perianal Crohn's disease. *Int J Dermatol* 2000;39:616–8.
119. Homan WP, Tang C, Thorgjarnarson B. Anal lesions complicating Crohn disease. *Arch Surg* 1976;111:1333–5.
120. Bonheur JL, Braunstein J, Korelitz BI, et al. Anal skin tags in inflammatory bowel disease: new observations and a clinical review. *Inflamm Bowel Dis* 2008;14:1236–9.
121. Taylor BA, Williams GT, Hughes LE, et al. The histology of anal skin tags in Crohn's disease: an aid to confirmation of the diagnosis. *Int J Colorectal Dis* 1989;4:197–9.
122. Nelson RL, Thomas K, Morgan J, et al. Non surgical therapy for anal fissure. *Cochrane Database Syst Rev* 2012;2:CD003431.
123. Linares L, Moreira LF, Andrews H, et al. Natural history and treatment of anorectal strictures complicating Crohn's disease. *Br J Surg* 1988; 75:653–5.