

# Diagnosis and Management of Primary Sclerosing Cholangitis

Roger Chapman,<sup>1</sup> Johan Fevery,<sup>2</sup> Anthony Kalloo,<sup>3</sup> David M. Nagorney,<sup>4</sup> Kirsten Muri Boberg,<sup>5</sup> Benjamin Shneider,<sup>6</sup> and Gregory J. Gores<sup>7</sup>

## Preamble

This guideline has been approved by the American Association for the Study of Liver Diseases and represents the position of the Association. These recommendations provide a data-supported approach. They are based on the following: (1) formal review and analysis of the recently-published world literature on the topic (Medline search); (2) American College of Physicians Manual for Assessing Health Practices and Designing Practice Guidelines<sup>1</sup>; (3) guideline policies, including the AASLD Policy on the Development and Use of Practice Guidelines and the American Gastroenterological Association Policy Statement on Guidelines<sup>2</sup>; and (4) the experience of the authors in the specified topic.

Intended for use by physicians, these recommendations suggest preferred approaches to the diagnostic, therapeutic and preventative aspects of care. They are intended to be flexible, in contrast to standards of care, which are inflexible policies to be followed in every case. Specific recommendations are based on relevant published information. To more fully characterize the available evidence supporting the recommendations, the AASLD Practice Guidelines Committee has adopted the

classification used by the Grading of Recommendation Assessment, Development, and Evaluation (GRADE) workgroup with minor modifications (Table 1).<sup>3</sup> The strength of recommendations in the GRADE system are classified as strong (class 1) or weak (class 2). The quality of evidence supporting strong or weak recommendations is designated by one of three levels: high (level A), moderate (level B), or low-quality (level C).

## Definition and Diagnosis

**Definitions.** Primary sclerosing cholangitis (PSC) is a chronic, cholestatic liver disease characterized by inflammation and fibrosis of both intrahepatic and extrahepatic bile ducts,<sup>4</sup> leading to the formation of multifocal bile duct strictures. PSC is likely an immune mediated, progressive disorder that eventually develops into cirrhosis, portal hypertension and hepatic decompensation, in the majority of patients.<sup>5</sup>

Small duct PSC is a disease variant which is characterized by typical cholestatic and histological features of PSC but normal bile ducts on cholangiography.<sup>6</sup> PSC overlap syndromes are conditions with diagnostic features of both PSC and other immune mediated liver diseases including autoimmune hepatitis and autoimmune pancreatitis.<sup>7</sup>

Secondary sclerosing cholangitis (SSC) is characterized by a similar multifocal biliary stricturing process due to identifiable causes such as long-term biliary obstruction, infection, and inflammation which in turn leads to destruction of bile ducts and secondary biliary cirrhosis.<sup>8</sup> Immunoglobulin G4 (IgG4)-positive sclerosing cholangitis might represent a separate entity.<sup>9</sup>

**Diagnosis of PSC.** A diagnosis of PSC is made in patients with a cholestatic biochemical profile, when cholangiography (e.g., magnetic resonance cholangiography [MRC], endoscopic retrograde cholangiography [ERC], percutaneous transhepatic cholangiography) shows characteristic bile duct changes with multifocal strictures and segmental dilatations, and secondary causes of sclerosing cholangitis have been excluded.<sup>8</sup> Patients who present with clinical, biochemical and histological features compatible with PSC, but have a normal cholangiogram, are classified as small duct PSC.<sup>6</sup>

**Differential Diagnosis of PSC Versus SSC.** Clinical and cholangiographic findings resembling PSC have been

---

All AASLD Practice Guidelines are updated annually. If you are viewing a Practice Guideline that is more than 12 months old, please visit [www.aasld.org](http://www.aasld.org) for an update in the material.

Abbreviations: AASLD, American Association for the Study of Liver Diseases; AIH, autoimmune hepatitis; CCA, cholangiocarcinoma; ERC, endoscopic retrograde cholangiography; FISH, fluorescent in situ hybridization; IBD, inflammatory bowel disease; IgG, immunoglobulin G; MRC, magnetic resonance cholangiography; OLT, orthotopic liver transplantation; OR, odds ratio; PET, positron emission tomography; PSC, primary sclerosing cholangitis; SSC, secondary sclerosing cholangitis; UC, ulcerative colitis; UDCA, ursodeoxycholic acid.

From the <sup>1</sup>John Radcliffe Hospital, Headington, Oxford, UK; <sup>2</sup>Hepatology, University Hospital Gasthuisberg, Leuven, Belgium; <sup>3</sup>Division of Gastroenterology and Hepatology, The Johns Hopkins Hospital, Baltimore, MD; <sup>4</sup>Division of Gastroenterology and General Surgery, Mayo Clinic, Rochester, MN; <sup>5</sup>Medical Department, Oslo University Hospital, Rikshospitalet, Oslo, Norway; <sup>6</sup>Children's Hospital of Pittsburgh of UPMC, Pittsburgh, PA; <sup>7</sup>Division of Gastroenterology and Hepatology, Mayo Clinic, Rochester, MN.

Received August 31, 2009; accepted August 31, 2009.

Address reprint requests to: Gregory J. Gores, Division of Gastroenterology, Mayo Clinic, Rochester, MN. E-mail: [gores.gregory@mayo.edu](mailto:gores.gregory@mayo.edu).

Copyright © 2009 by the American Association for the Study of Liver Diseases.

Published online in Wiley InterScience ([www.interscience.wiley.com](http://www.interscience.wiley.com)).

DOI 10.1002/hep.23294

Potential conflict of interest: Nothing to report.

**Table 1. Grading of Recommendations, Assessment, Development and Evaluation (GRADE)**

Strength of Recommendation	Criteria
Strong (1)	Factors influencing the strength of the recommendation included the quality of the evidence, presumed patient-important outcomes, and cost Variability in preferences and values, or more uncertainty. Recommendation is made with less certainty, higher cost or resource consumption
Weak (2)	
Quality of Evidence	Criteria
High (A)	Further research is unlikely to change confidence in the estimate of the clinical effect
Moderate (B)	Further research may change confidence in the estimate of the clinical effect Further research is very likely to impact confidence on the estimate of clinical effect
Low (C)	

described in patients with choledocholithiasis, surgical trauma of the biliary tree, intra-arterial chemotherapy, and recurrent pancreatitis.<sup>8</sup> Other conditions reported to mimic PSC are listed in Table 2. Distinguishing primary from SSC may be challenging because PSC patients may have undergone bile duct surgery or have concomitant intraductal stone disease or even cholangiocarcinoma (CCA). The clinical history, distribution of cholangiographic findings, and the presence or absence of inflammatory bowel disease (IBD), have to be taken into consideration when determining if an abnormal cholangiogram is due to PSC or secondary processes.<sup>8</sup>

**Signs and Symptoms.** The clinical presentation is variable; typical symptoms include right upper quadrant

**Table 2. Secondary Causes of Sclerosing Cholangitis**

AIDS cholangiopathy
Cholangiocarcinoma
Choledocholithiasis
Diffuse intrahepatic metastasis
Eosinophilic cholangitis
Hepatic inflammatory pseudotumor
Histocytosis X
IgG4-associated cholangitis
Intra-arterial chemotherapy
Ischemic cholangitis
Mast cell cholangiopathy
Portal hypertensive biliopathy
Recurrent pancreatitis
Recurrent pyogenic cholangitis
Surgical biliary trauma

**Table 3. Serum Autoantibodies in Primary Sclerosing Cholangitis**

Antibody	Prevalence
Anti-neutrophil cytoplasmic antibody	50%-80%
Anti-nuclear antibody	7%-77%
Anti-smooth muscle antibody	13%-20%
Anti-endothelial cell antibody	35%
Anti-cardiolipin antibody	4%-66%
Thyroperoxidase	7%-16%
Thyroglobulin	4%
Rheumatoid factor	15%

abdominal discomfort, fatigue, pruritus, and weight loss.<sup>10</sup> Episodes of cholangitis (i.e., fever and chills) are very uncommon features at presentation, in the absence of prior biliary surgery or instrumentation such as ERC.<sup>11</sup> Physical examination is abnormal in approximately half of symptomatic patients at the time of diagnosis; jaundice, hepatomegaly, and splenomegaly are the most frequent abnormal findings.

Many patients with PSC are asymptomatic with no physical abnormalities at presentation. The diagnosis is made incidentally when persistently cholestatic liver function tests are investigated. Approximately 60%-80% of patients with PSC have concomitant IBD, most often ulcerative colitis (UC).<sup>12</sup>

**Serum Biochemical Tests.** Serum biochemical tests usually indicate cholestasis; elevation of serum alkaline phosphatase is the most common biochemical abnormality in PSC.<sup>5,10,13</sup> However, a normal alkaline phosphatase activity does not exclude the diagnosis. Serum aminotransferase levels are elevated in the majority of patients (2-3 times upper limits of normal), but like the alkaline phosphatase can also be in the normal range. Serum bilirubin levels are normal at diagnosis in the majority of patients. IgG serum levels are modestly elevated in approximately 60% of patients (1.5 times the upper limit of normal).<sup>14</sup>

**Autoantibodies/Serology.** A wide range of autoantibodies can be detected in the serum of patients with PSC indicating an altered state of immune responsiveness or immune regulation.<sup>15</sup> Most are present at low prevalence rates and at relatively low titers (Table 3). They have no role in the routine diagnosis of PSC including the perinuclear antineutrophil cytoplasmic antibody which is non-specific, although it may draw attention to colon involvement in a cholestatic syndrome.

**Imaging Studies.** Transabdominal ultrasound (US) is usually nondiagnostic and may even be normal, although bile duct wall thickening and/or focal bile duct dilatations are often identified. However, gallbladder abnormalities, including wall thickening, gallbladder enlargement,<sup>16</sup>

gallstones, cholecystitis, and mass lesions, are identified in up to 41% of patients with PSC who undergo US examinations.<sup>17</sup>

The findings on computed tomography (CT) cross-sectional or coronal imaging of the upper abdomen are also nonspecific. CT imaging can detect thickening of the bile ducts with contrast enhancement consistent with inflammation, saccular dilatations of the intrahepatic ducts, heterogeneous bile duct dilatation, document the presence of portal hypertension (i.e., varices, splenomegaly, and ascites), and identify mass lesions.<sup>18–22</sup> It should be noted that lymphadenopathy in the abdomen is common in PSC and should not be over interpreted as metastases or a lymphoproliferative disorder.<sup>22</sup> No information exists on the emerging technology of CT cholangiography for the diagnosis or evaluation of PSC.

Traditionally, ERC was regarded as the gold standard in diagnosing PSC.<sup>23,24</sup> However, ERC is an invasive procedure associated with potentially serious complications such as pancreatitis and bacterial cholangitis. Indeed, ERC is associated with hospitalization in up to 10% of PSC patients undergoing the procedure.<sup>25</sup> MRC, which is non-invasive and avoids radiation exposure, has become the diagnostic imaging modality of choice when PSC is suspected. ERC and MRC have comparable diagnostic accuracy, although the visualization of bile ducts may be less than optimal for certain patients with MRC.<sup>26</sup> Sensitivity and specificity of MRC is  $\geq 80\%$  and  $\geq 87\%$ , respectively, for the diagnosis of PSC.<sup>26,27</sup> However, it should be noted that patients with early changes of PSC may be missed by MRC, and ERC still has a useful role in excluding large duct PSC where MRC views may not be optimal.

A cholangiographic assessment of the extrahepatic and intrahepatic biliary tree is required to establish a diagnosis of large duct PSC.<sup>24</sup> The characteristic cholangiographic findings include multifocal, short, annular strictures alternating with normal or slightly dilated segments producing a “beaded” pattern.<sup>23,24</sup> Long, confluent strictures may also be observed although these are worrisome for the development of superimposed cholangiocarcinoma.<sup>23</sup> Both the intra- and extrahepatic bile ducts are usually involved, although a subset of patients (<25%) may only have intrahepatic disease. Conversely, lesions confined to the extrahepatic ducts are quite unusual (usually <5%) and should only be diagnosed in the presence of adequate filling of the intrahepatic ducts. The gallbladder, cystic duct and pancreatic duct may also be involved in PSC patients.<sup>23</sup>

**Role of Liver Biopsy.** Liver histological findings may be compatible with a diagnosis of PSC, but in general the changes at an early stage are non-specific although

usually indicating some form of biliary disease. Periductal concentric (“onion-skin”) fibrosis is a classic histopathologic finding of PSC, but this observation is infrequent in PSC liver biopsy specimens and may also be observed in SSC. A retrospective study in 138 patients with cholangiographic features of PSC suggested that liver biopsy rarely adds useful diagnostic information.<sup>28</sup>

In the presence of an abnormal cholangiogram, a liver biopsy is therefore not required to establish a diagnosis of large duct PSC, although is essential in suspected small duct PSC, and for the assessment of possible overlap syndromes. In PSC patients with disproportionately elevated serum aminotransferase values, especially if the antinuclear antigen and/or smooth muscle antigen is positive and/or serum IgG levels are elevated, a liver biopsy may identify features of a PSC–autoimmune hepatitis (AIH) overlap syndrome.

**PSC-AIH Overlap Syndrome.** PSC-AIH overlap syndrome is a disorder mainly described in children and young adults.<sup>29–37</sup> It is characterized by the clinical, biochemical, and histological features of AIH in the presence of cholangiographic findings identical to PSC.<sup>38,39</sup> Diagnosis of an overlap syndrome by use of the modified AIH score was established in 8% of 113 PSC patients from the Netherlands,<sup>40</sup> in 1.4% of 211 PSC patients from the United States,<sup>41</sup> in 17% of 41 PSC patients from Italy,<sup>42</sup> and in 6.1% of 264 patients with AIH from England.<sup>37</sup>

**Autoimmune Pancreatitis (Immunoglobulin G4–Associated Cholangitis) and PSC.** Autoimmune pancreatitis (AIP) is a clinical entity characterized by stricturing of the pancreatic duct, focal or generalized pancreatic enlargement, a raised serum immunoglobulin G4 (IgG4) level, a lymphoplasmacytic infiltrate on biopsy, and a response to corticosteroid therapy.<sup>43</sup> AIP in association with intrahepatic and extrahepatic bile duct stricturing similar to those present in PSC is termed autoimmune pancreatitis–sclerosing cholangitis (AIP-SC). Pancreatic abnormalities are not universally found, suggesting that IgG4-associated cholangitis (IAC) may be a more appropriate term to describe the condition.<sup>44</sup>

A recent study found an elevated serum IgG4 level (>140 mg/dL) in 9% of a cohort of 127 patients with PSC.<sup>45</sup> In comparison to patients with PSC with normal IgG4 concentrations, the former group had significantly higher levels of alkaline phosphatase and bilirubin, in addition to higher PSC Mayo risk scores. An association with IBD was less likely in those with elevated IgG4 levels, although biliary and pancreatic involvement were similar in both groups.<sup>45</sup> Whether PSC and AIP represent different ends of the same disease spectrum or are separate clinical entities is of debate, although current evidence favors the latter.

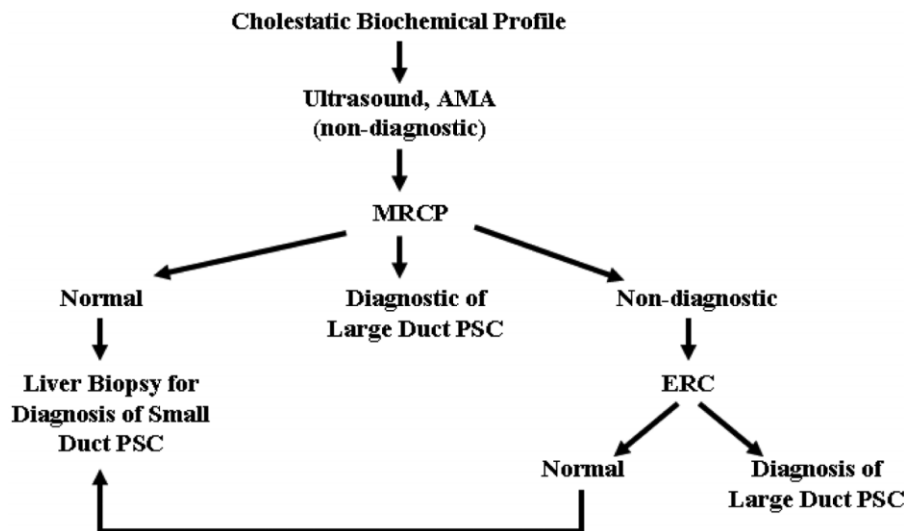


Fig. 1. Algorithm for the diagnosis of PSC.

#### Recommendations (Fig. 1):

1. In patients with cholestatic biochemical profile, we recommend indirect (MRC) or direct cholangiography (ERCP) for making the diagnosis of PSC (1A).

2. We recommend against routine liver biopsy for the diagnosis of PSC in patients with typical cholangiographic findings (1B).

3. In patients with a normal ERC or MRC, we recommend a liver biopsy to diagnose small duct PSC (1B).

4. In patients with disproportionately elevated aminotransferases, we recommend performing a liver biopsy to diagnose or exclude overlap syndrome (1B).

5. In all patients with possible PSC, we suggest measuring serum IgG4 levels to exclude IgG4-associated sclerosing cholangitis (2C).

### Dominant Strictures in PSC

**Definition.** A “dominant stricture” has been defined as a stenosis with a diameter of  $\leq 1.5$  mm in the common bile duct or of  $\leq 1$  mm in the hepatic duct.<sup>46,47</sup> It is a frequent finding and occurs in 45% to 58% of patients during follow up.<sup>5,46,48</sup> It should always raise the suspicion of the presence of a cholangiocarcinoma (CCA), because this malignant complication of PSC occurs frequently as a stenotic ductal lesion in the perihilar region. Although CCA may develop in approximately 10%-15% of PSC patients, stenotic lesions are far more often benign than malignant in nature.<sup>49</sup> The distinction between a dominant stricture and CCA is difficult; the diagnosis of CCA is discussed below in this guideline.

**Endoscopic and Percutaneous Management.** The

goal of an endoscopic or percutaneous therapeutic approach to the management of patients with PSC is to relieve biliary obstruction. The stricturing disease of PSC may cause extrahepatic ductal obstruction and therefore lead to symptoms and decompensation of liver function. Some 15%-20% of patients will experience obstruction from discrete areas of narrowing within the extrahepatic biliary tree.<sup>24,50,51</sup> It is generally agreed that patients with symptoms from dominant strictures such as cholangitis, jaundice, pruritus, right upper quadrant pain or worsening biochemical indices, are appropriate candidates for therapy. The percutaneous approach is associated with increased morbidity but similar efficacy as the endoscopic approach and is reserved for patients who have proximal dominant strictures with a failed endoscopic approach.<sup>52,53</sup>

Before any attempt at endoscopic therapy, brush cytology and/or endoscopic biopsy should be obtained to help exclude a superimposed malignancy. The best therapeutic endoscopic approach is still debated; multiple techniques have been utilized such as sphincterotomy, catheter or balloon dilatation, and stent placement.<sup>51-54</sup> Of these, only endoscopic biliary sphincterotomy and balloon dilatation with or without stent placement have been found to be of value.<sup>51-59</sup> Because injecting contrast agent into an obstructed duct may precipitate cholangitis, perioperative antibiotics should be administered. Sphincterotomy alone has been performed in small subsets of patients, usually when stent placement was unsuccessful. In these small uncontrolled groups, bilirubin and alkaline phosphatase levels did improve.<sup>54</sup> Indeed, the biliary sphincter of Oddi may be involved by the sclerosing process and therefore contribute to biliary obstruction. Nevertheless,

sphincterotomy is rarely used alone, but rather to facilitate balloon dilatation, stent placement or stone extraction.<sup>55</sup>

Stricture dilatation can be accomplished through balloons or coaxial dilators. Balloon dilatation has been shown to be effective alone.<sup>52,56,57</sup> It may be performed periodically with or without stenting. However, biliary stenting has been shown to be associated with increased complications when compared to endoscopic dilatation only and should be reserved for strictures that are refractory to dilatation.<sup>52-57</sup>

At this time there has not been a randomized controlled study to evaluate the effectiveness of endoscopic therapy. Still, much indirect evidence by large retrospective studies, suggest that endoscopic therapy results in clinical improvement and prolonged survival. Baluyut et al. evaluated their population of patients with PSC and dominant strictures who underwent endoscopic balloon dilatation and found that the observed 5-year survival rate was significantly better than that predicted by the Mayo Risk Score (83% versus 65%,  $P = 0.027$ ).<sup>58</sup> This is the first study to suggest that therapy may actually impact the natural history of the disease. More recently, Gluck et al. described a 20 year experience with endoscopic therapy for 84 symptomatic patients with PSC.<sup>59</sup> Similar to the Baluyut study, observed patient survival was higher than expected by the Mayo Risk Score.<sup>59</sup>

All therapeutic endoscopy comes with risk. In the two largest reported series of patients with long follow-up, the risk of complications was 7.3%-20%. The complications were mild without need for surgical intervention.<sup>58,59</sup> The most common complications were pancreatitis, cholangitis, biliary tract perforation and hemorrhage.

**Surgical Management of Dominant Strictures.** Focal biliary tract obstruction, whether benign or malignant, has been the primary indication for the nontransplant surgical management of PSC. Despite limitations of the accuracy of current diagnostic modalities for malignancy in PSC, diagnostic laparotomy has little clinical value. The rationale for surgical management in PSC is bypass of an obstruction caused by a dominant stricture. Non-transplant surgical approaches include biliary bypass by cholangio-enterostomy or resection of the extrahepatic biliary stricture and Roux Y hepaticojejunostomy.<sup>60,61</sup> Biliary bypass alone has been employed infrequently because dominant strictures are typically hilar. Moreover, the intrahepatic ducts are variably involved which limits the access and quality of these ducts for bypass.<sup>60</sup> Biliary bypass has no role in PSC patients with cirrhosis.

Extrahepatic bile duct resection and Roux Y hepaticojejunostomy with or without stenting for dominant strictures is controversial.<sup>53,61</sup> Current evidence suggests

that selected patients with non-cirrhotic stage PSC have an overall survival of 83% at 5 years and 60% at 10 years and a readmission free rate from cholangitis of 57% at 3 years for such an approach.<sup>62</sup> Bilirubin levels  $> 2$  mg/dL and cirrhosis are associated with decreased survival. No data regarding surgical management have shown that either bypass or resection of a dominant stricture affect natural history or disease progression.

**Bacterial Cholangitis.** Most patients, who have not had biliary tree instrumented, have negative microbial bile cultures.<sup>63,64</sup> However, dominant strictures can induce stagnation of bile resulting in bacterial colonization and secondary cholangitis. This can be the first presentation of the disease occurring in 6.1% of PSC patients in one recent study.<sup>65</sup> Furthermore, severe recurrent cholangitis may play a role in the progression of the disease. The relevance of a bile duct stricture was demonstrated by documenting bacterial infection of the bile in 15 out of 37 PSC patients (40.5%) with a dominant stricture but not in the absence of such stenosis; short-course antibiotic treatment proved not very effective in eradicating bacteria from the bile ducts of patients with dominant strictures.<sup>66</sup> However, most patients respond to therapeutic drainage of the obstruction plus antibiotics. Occasional patients with recurrent bacterial cholangitis may benefit from prophylactic long term antibiotics. Rarely, recurrent cholangitis can be so severe as to become the primary indication for OLT.<sup>67</sup>

**Pruritus.** The management of pruritus in PSC patients should prompt consideration of a dominant stricture. In the absence of a dominant stricture, the management of pruritus is similar to that for pruritus in primary biliary cirrhosis. Please see the AASLD Guidelines on the Management of PBC.<sup>68</sup>

#### **Recommendations:**

**6. In patients with increases in serum bilirubin and/or worsening pruritus progressive bile duct dilatation on imaging studies, and/or cholangitis, we recommend performing an ERC promptly to exclude a dominant stricture (1B).**

**7. In patients with dominant strictures from PSC, we recommend initial management with endoscopic dilatation with or without stenting (1B).**

**8. In patients with dominant strictures from PSC in whom an endoscopic approach is unsuccessful, biliary tract dilatation by percutaneous cholangiography with or without stenting should be considered (1B).**

**9. We recommend performing brush cytology and/or endoscopic biopsy to exclude a superimposed malignancy prior to endoscopic therapy for dominant strictures (1B).**

**10. In patients with dominant strictures refractory to endoscopic and/or percutaneous management, we recommend surgical therapy in selected patients without cirrhosis C (1B).**

**11. We recommend antimicrobial therapy with correction of bile duct obstruction in dominant strictures to effectively resolve cholangitis (1A).**

**12. In patients with recurrent bacterial cholangitis, we recommend the use of prophylactic long-term antibiotics (1B).**

**13. In patients with refractory bacterial cholangitis, we recommend evaluation for liver transplantation (1B).**

## Portal Hypertension

When cirrhosis is present in a patient with PSC, portal hypertension (PHT) will gradually develop because it constitutes part of the natural history of all patients with cirrhosis. As is the case with cirrhosis in general, the platelet count is a predictor of the presence of esophageal varices also in PSC. Of 283 PSC patients newly diagnosed at Mayo Clinic (Rochester, MN) 36% (n = 102) had varices, of which 56% had moderate/large varices and 28 had already bled. Independent predictors of esophageal varices and of moderate/large size varices were platelet count, albumin level, and advanced histologic disease. After controlling for the presence of advanced histologic stage and albumin levels, the odds ratios (OR) of platelet count less than  $150 \times 10^3/\text{dL}$  for the presence of esophageal varices was 6.3 (95% CI: 2.6-15.8).<sup>69</sup> Similar conclusions were reached in Mexico in a smaller group.<sup>70</sup>

Portal hypertension may, however, be present in patients with PSC who do not yet have cirrhosis, but this is uncommon. Of 306 liver transplants performed during 1995-2003 for chronic biliary tract disease, 26 (8.5%) underwent OLT in the precirrhotic stage; 18 of them had PSC. Of the 11 patients with portal hypertension as the major indication for OLT, nodular regenerative hyperplasia (NRH) was prominent in 8 (73%) and obliterative portal venopathy in 6 (55%) at histopathological examination. Thus, precirrhotic PHT may contribute as an indication for OLT.<sup>67</sup> The management of portal hypertension in patients with PSC does not differ from non-PSC patients and has been discussed in prior AASLD guidelines.<sup>71</sup>

## Metabolic Bone Disease

Hepatic osteodystrophy is the term used for the metabolic bone disorders associated with chronic liver diseases. The diagnosis is made by bone mineral density measurement whereby osteopenia is characterized by a T-score

between 1 and 2.5 standard deviations below the density observed in young normal individuals, and osteoporosis as a T-score beneath 2.5. The incidence of osteoporosis in PSC is between 4 and 10%. The incidence increases with decreasing body mass index, with increasing duration of the disease, with age, and possibly with severity of the disease,<sup>72</sup> although this was not confirmed.<sup>73</sup>

Hepatic osteodystrophy should thus be looked for in all newly diagnosed patients with PSC. Although information is lacking, it is reasonable to screen for osteopenia thereafter at 2-3 year intervals. Calcium and additional vitamin D to promote calcium absorption is recommended in patients with proven osteopenia, and in case of proven osteoporosis bisphosphonates may be added.<sup>74</sup> Bisphosphonate therapy induces a significant improvement in bone density in PBC patients.<sup>75</sup> Oral bisphosphonates have been associated with esophageal ulcers which could be problematic in patients with esophageal varices; in these patients parenteral bisphosphonate therapy is an alternative approach.

### Recommendations:

**14. We recommend bone density examinations to exclude osteopenia or osteoporosis at diagnosis and, thereafter, at 2-3 year intervals (1B).**

**15. In patients with hepatic osteopenia, we suggest the use of calcium 1.0-1.5 g and vitamin D 1,000 IU daily for therapy (2C).**

**16. In patients with hepatic osteoporosis, we suggest the use of bisphosphonate therapy in addition to calcium and vitamin D supplementation (2C).**

**17. In patients with osteoporosis and esophageal varices, we suggest the use of parenteral forms of bisphosphonate therapy rather than oral formulations (2C).**

## Inflammatory Bowel Disease and PSC

**Epidemiology.** PSC is strongly associated with IBD. In most series of patients from Northern Europe and North America, the prevalence of IBD in PSC has been in the range 60%-80%.<sup>10,13,50,76</sup> The most frequent type of IBD in PSC is UC, which is diagnosed in 48%-86% among the patients with IBD.<sup>76,77</sup> Up to 13% have Crohn disease (CD) which usually involves the colon.<sup>76,77</sup> Conversely, PSC has been diagnosed in between 2.4% and 7.5% of patients with UC<sup>76</sup> and was found in 3.4% among a large group of 262 CD patients.<sup>78</sup> The true prevalence of PSC among IBD patients is difficult to assess, because accurate data require that cholangiography is carried out in unselected groups of patients.

**Diagnosis.** The diagnosis and classification of IBD in PSC are based on ordinary diagnostic criteria, including

**Table 4. Characteristics of Inflammatory Bowel Disease Associated with Primary Sclerosing Cholangitis**

● Extensive colitis (with right-sided predominance of inflammatory activity)
● Rectal sparing
● Backwash ileitis
● Mild or quiescent course
● Increased risk of colorectal neoplasia
● Increased risk of pouchitis in patients undergoing proctocolectomy with IPAA
● Increased risk of peristomal varices in patients undergoing proctocolectomy with ileostomy

findings on colonoscopy with multiple biopsies.<sup>76</sup> Because rectal sparing is a common feature,<sup>77</sup> a full colonoscopy is necessary. Moreover, as IBD in PSC may be present with little or no clinical evidence of bowel disease and a diagnosis of IBD has implications in terms of follow-up, a full colonoscopy with multiple biopsies is recommended in all PSC patients at diagnosis.<sup>76,77,79,80</sup> If the initial colonoscopy with biopsies is negative for IBD, it is unclear if a repeat colonoscopy in the absence of IBD-type symptoms should be repeated over time.

IBD may be diagnosed at any time during the course of PSC. In the majority of cases, the diagnosis of IBD precedes that of PSC, even by several years.<sup>13,77,81</sup> IBD and PSC are sometimes diagnosed concomitantly.<sup>82</sup> Onset of IBD can also occur some years after the diagnosis of PSC, and *de novo* IBD may present after liver transplantation for PSC.<sup>83</sup> PSC may be diagnosed at any time during the course of IBD, and may present several years after proctocolectomy.<sup>13,82</sup>

**IBD in PSC: A Unique Phenotype.** Several clinical and endoscopic features of IBD in PSC differ from those of IBD without evidence of hepatobiliary disease (Table 4). Loftus et al.<sup>77</sup> compared 71 patients with PSC who had IBD with a matched group of 142 patients with UC. Among the PSC patients, 86% had UC, 7% had CD, and 7% had indeterminate colitis. The PSC patients more frequently had pancolitis (87% versus 54%), rectal sparing (52% versus 6%), and “backwash ileitis” (51% versus 7%) than the control group. It is a general experience that the colitis associated with PSC usually is extensive.<sup>13,79,82</sup> This observation also includes CD in PSC, that typically manifests as extensive colitis.<sup>76</sup> CD confined to the small bowel is not associated with PSC.<sup>76,78</sup> Interestingly, it has been noted that the CD colitis may not always have features strongly suggestive of CD.<sup>77,84</sup> A definite classification of the IBD in PSC may be difficult and can vary between centers. The presence of rectal sparing or ileal involvement may for example be interpreted by some centers as CD or indeterminate colitis, rather than UC.<sup>77,84</sup> IBD in children with PSC is also characterized by extensive colitis, often with rectal sparing, and mild clinical symptoms.<sup>84</sup>

Although symptoms of IBD in PSC cannot be distinguished from those of IBD without PSC,<sup>76</sup> the bowel disease in PSC tends to run a more quiescent course.<sup>77,85</sup> The IBD can also have a prolonged subclinical course.<sup>79</sup> In a follow-up study of 27 PSC patients with IBD, 12 patients (44%) reported disease activity during the first time after diagnosis of IBD, followed by a quiescent phase.<sup>81</sup> Seven (26%) patients had intermittent disease activity. Follow-up colonoscopy revealed mild or inactive disease in the majority of cases (16 patients; 76%), however, 16 patients had experienced some complication of IBD during the observation period.

PSC patients who have an ileal pouch anal anastomosis (IPAA) after colectomy have an increased risk of pouchitis compared to patients with UC without PSC.<sup>77,86,87</sup> Predisposing factors for this complication are unknown. Although one report suggests that patients with PSC and IPAA run an increased risk of development of dysplasia in the ileal pouch mucosa compared with UC patients without PSC and that these patients consequently should undergo regular screening,<sup>88</sup> studies in larger cohorts of patients should be carried out to confirm the findings.

**Risk of Malignancy.** UC is associated with an increased risk of colorectal cancer (CRC).<sup>89–93</sup> Indeed, a thorough meta-analysis including 11 studies, indicates that patients with UC and PSC are at an increased risk of CRC and dysplasia compared with patients with UC alone, with OR 4.79 (95% CI 3.58–6.41).<sup>94</sup> In a recent study, PSC patients with IBD and CRC were found to be younger at onset of IBD than patients who had IBD and CRC without PSC (19 versus 29 years;  $P = 0.04$ ).<sup>95</sup> The time interval from onset of colitis until diagnosis of CRC was, however, similar in the two groups (17 versus 20 years;  $P = 0.02$ ).

Given the increased risk of CRC in patients with PSC, surveillance colonoscopy at one to two year intervals from the time of diagnosis of PSC in patients with UC as recommended by several experienced centers.<sup>77,79,96,97</sup> Colorectal neoplasia associated with PSC appears to have a predilection for the proximal colon, with up to 76% having a right-sided distribution.<sup>93</sup> A full colonoscopy is therefore necessary during surveillance. Due to the increased risk of CRC in Crohn colitis, patients with PSC who have CD are recommended to be surveyed similarly to patients with UC.<sup>80,98</sup>

Ursodeoxycholic acid (UDCA) has been suggested to decrease the risk of colorectal dysplasia in patients with PSC and UC.<sup>99,100</sup> Treatment with UDCA was associated with a decreased prevalence of colonic dysplasia (OR 0.18, 95% CI 0.05–0.61) in a cross-sectional study of 59 PSC patients with UC<sup>100</sup> and significantly decreased the risk for developing colorectal dysplasia or cancer (relative

risk, 0.26; 95% CI, 0.06-0.92) in a follow-up of 52 patients with PSC and UC after a randomized, placebo-controlled trial of UDCA.<sup>99</sup> In a study comparing 28 patients with PSC and UC treated with UDCA for at least 6 months with 92 untreated patients, UDCA did not decrease the risk of cancer or dysplasia.<sup>101</sup> All of these studies have been based on retrospective analysis with its inherent limitations. Furthermore, high dose UDCA can be problematic in PSC patients.<sup>102</sup> UDCA use as a chemopreventative agent in PSC patients can not be routinely recommended given the limited information available.

PSC patients who have an ileostomy after proctocolectomy and who develop portal hypertension, are prone to develop peristomal varices.<sup>103</sup> Bleeding from these often is recurrent and difficult to treat.<sup>103</sup> This complication can be controlled with a portosystemic shunt or transjugular intrahepatic portosystemic shunt (TIPS), but liver transplantation may be considered.<sup>79</sup> IPAA is less complicated with variceal formation<sup>86</sup> and PSC patients undergoing IPAA have good functional results.<sup>104</sup>

#### **Recommendations:**

**18. We recommend full colonoscopy with biopsies in patients with a new diagnosis of PSC and no previous history or symptoms of IBD (1A).**

**19. In patients with IBD and PSC, we recommend surveillance colonoscopy with biopsies at 1-year to 2-year intervals from the time of diagnosis of PSC to exclude colorectal neoplasia (1B).**

**20. We recommend against the use of UDCA as chemoprevention for colorectal cancer in patients with ulcerative colitis and PSC (1B).**

**21. We recommend that patients with IBD and PSC should be treated according to guidelines for IBD (1B).**

## **Gallbladder Disease and PSC**

**Stones.** Gallbladder abnormalities are frequently observed in PSC patients. In an early study of 121 cases, 41% had one or more gallbladder abnormalities, including gallstones (26%), probable PSC involving the gallbladder (15%), and benign or malignant neoplasms (4%).<sup>105</sup> Although gallstones as a cause of SSC must be considered, PSC patients seem to be predisposed to gallstone disease, including both the gallbladder and the biliary tract. In a review of the records of 286 PSC patients, gallstones (confirmed by one or more radiological modalities) were found in 25% of the cases.<sup>17</sup> Gallbladder stones were diagnosed at a mean of 5 years ( $\pm 6.4$  years) after the diagnosis of PSC. Treatment with UDCA or the presence of IBD did not influence the frequency of gallstones.

**Polyps and Cancer.** In the above study of 286 patients with PSC, a gallbladder mass lesion (mean size  $21 \pm 9$  mm) was found in 18 (6%) cases.<sup>17</sup> Among these, 10 (56%) proved to be a gallbladder carcinoma. Nine patients without a mass lesion, had epithelial dysplasia of the gallbladder on histological examination. A corresponding high risk of cancer associated with a gallbladder mass lesion was found in a study of 102 PSC patients undergoing cholecystectomy.<sup>106</sup> Fourteen patients (13.7%) had a gallbladder mass lesion, and eight (57%) among these were adenocarcinomas. Furthermore, investigation of 72 gallbladders from PSC patients (6 obtained prior to and 66 removed at liver transplantation) revealed low-grade or high-grade dysplasia in 27 (37%) and adenocarcinoma in 10 (14%).<sup>107</sup> The high risk of malignancy associated with gallbladder polyps in this condition is a reason to follow the patients with regular US investigations and to recommend cholecystectomy, even if a mass lesion is  $< 1$  cm in diameter.<sup>17,107</sup> Gallbladder surveillance should be done annually.

#### **Recommendations:**

**22. We recommend annual ultrasound to detect mass lesions in the gallbladder (1C).**

**23. In patients with gallbladder mass lesions, we recommend cholecystectomy as treatment regardless of lesion size, if the underlying liver disease permits (1C).**

## **Cholangiocarcinoma**

**Diagnosis of CCA.** Patients with PSC are at risk for developing superimposed cholangiocarcinoma.<sup>10,92,108-113</sup> The 10-year cumulative incidence is approximately 7%-9% in recent studies.<sup>109,110</sup> Risk factors for the development of CCA published in the literature include an elevated serum bilirubin, variceal bleeding, proctocolectomy, chronic ulcerative colitis with colorectal cancer or dysplasia, the duration of inflammatory bowel disease, and polymorphisms of the NKG2D gene (encoding a protein involved in NK cell activity).<sup>108,114-116</sup> Of interest, is that the duration of PSC may not be a risk factor for the development of CCA in contradistinction to the risk factor for neoplasia in inflammatory bowel disease.<sup>113</sup> In fact, in approximately half of patients with PSC plus CCA, the malignancy is detected at the time of diagnosis or within the first year suggesting the superimposed CCA may have elicited the symptoms leading to the diagnosis of PSC.<sup>117</sup> Given the risk of CCA in PSC patients, patients with deterioration in their constitutional performance status or liver biochemical-related parameters should undergo an evaluation for CCA.

The distinction between a benign dominant stricture and CCA in a PSC patient is challenging. The best studied CCA associated biomarker in PSC is the serum CA



19-9. However, the CA 19-9 can be elevated in patients with bacterial cholangitis, and is virtually undetectable in 7% of the normal population who are negative for the Lewis antigen.<sup>118</sup> Patients negative for the Lewis antigen, therefore, will not have an elevated serum CA19-9 level despite having CCA. The cut-off for a diagnostic CA 19-9 value for CCA in PSC has been investigated in several studies.<sup>119-123</sup> Using a cut-off of 130 U/mL (normal < 55 U/mL) the sensitivity and specificity is 79% and 98%, respectively.<sup>120</sup> Thus, the determination of a serum CA 19-9 value in symptomatic patients has value in assessing the likelihood the patient has CCA. All these studies examining the utility of a serum CA 19-9 were performed in patients with suspected CCA; no study has demonstrated value for the serum CA 19-9 test as a screening modality in asymptomatic PSC populations.

These cholangiocarcinomas mimic the stricturing process of PSC making the diagnosis extremely difficult. The demonstration of a mass lesion with characteristic imaging features (i.e., malignant appearing mass with delayed venous phase enhancement) has virtually a 100% sensitivity and specificity for the diagnosis of CCA.<sup>122</sup> However, mass lesions are unusual in early stage CCA, and in a large study ultrasonography, computerized tomography and magnetic resonance imaging studies yielded an overall limited positive predictive value of 48%, 38%, and 40%, respectively, in identifying CCA in patients with PSC.<sup>122</sup>

Other than identifying ductal obstruction, direct cholangiography by ERCP and indirect cholangiography by magnetic resonance studies have net overall positive predictive values for CCA of only 23% and 21%, respectively.<sup>122</sup> The ability to more directly visualize the bile duct via cholangioscopy and/or intraductal US are promising technologies for the diagnosis of CCA in PSC,<sup>5,124</sup> but have not yet been tested in large patient populations nor validated by multiple studies.

Unfortunately, conventional brush cytology obtained via endoscopic retrograde or percutaneous cholangiography has a limited sensitivity albeit excellent specificity for the diagnosis of CCA in PSC. The sensitivity in the literature ranges from 18%-40% in large studies.<sup>11,122,123,125,126</sup> The specificity for a positive conventional cytology is virtually 100%. Recently, the demonstration of polysomy (duplication of two or more chromosomes) in  $\geq 5$  cells by fluorescent in situ hybridization (FISH) of cytologic specimens has demonstrated a sensitivity of 41% and a specificity of 98% for the diagnosis of CCA in PSC patients<sup>125</sup>; a positive FISH test doubled the sensitivity of conventional cytology in this report. In a small study of 61 patients, the finding of high grade dysplasia was highly sensitive for

the diagnosis of CCA (sensitivity of 73% and specificity of 95%).<sup>126</sup> The FISH-based and dysplasia-based approaches have yet to be validated by additional centers.

The role of [<sup>18</sup>F]fluoro-2-deoxy-D-glucose (FDG) positron emission tomography (PET) in the diagnosis of CCA in PSC remains controversial.<sup>123,127,128</sup> It should be noted that inflammation can yield false positive PET scans a potential pitfall in PSC.

Many physicians desire guidelines for the surveillance of CCA in PSC patients. Surveillance strategies are predicated on the availability of highly sensitive diagnostic and cost-effective modalities, effective treatment strategies for patients found to have the disease, and patient acceptance of the diagnostic tests and treatment. Once the above criteria have been met, longitudinal studies must demonstrate a decrease in death from the disease. Inadequate information exists regarding the utility of screening for CCA in PSC; in the absence of evidence based information, many clinicians screen patients with an imaging study plus a CA 19-9 at annual intervals.<sup>122</sup>

In summary, the diagnosis of CCA in the setting of PSC remains challenging if a mass lesion is not identified by imaging studies. The most definitive findings for CCA are a mass lesion with characteristic features of CCA and a positive cytology or biopsy. A reasonable algorithm for the diagnosis of CCA in PSC is depicted in Fig. 2.

**Therapy of CCA.** Therapy for cholangiocarcinoma in the setting of PSC is limited, and confounded by several clinical parameters. First, patients often have non remediable cholestasis with jaundice and/or advanced fibrotic stage liver disease with portal hypertension; both conditions impair surgical and chemotherapeutic options. Second, CCA appears to arise from a field defect within the biliary tree and is therefore often multifocal along the biliary tree limiting the utility of surgical resections. Third, there is no established medical therapy for cholangiocarcinoma.<sup>129</sup> Fourth, given the difficulty in making the diagnosis of CCA in this patient population, many patients present with advanced stage cancer. Finally, regional extension and peritoneal metastasis are common, yet difficult to identify noninvasively, making it difficult to reliably stage the disease.

Survival following the diagnosis of CCA in the setting of PSC is dismal with 2-year survival being unusual.<sup>130</sup> Even for surgically resected patients, the 3-year survival rate is <20%.<sup>131,132</sup> Recently, liver transplantation has been advocated for the treatment of early stage CCA (unicentric mass lesion  $\leq 3$  cm in radial diameter and no intrahepatic or extrahepatic metastasis).

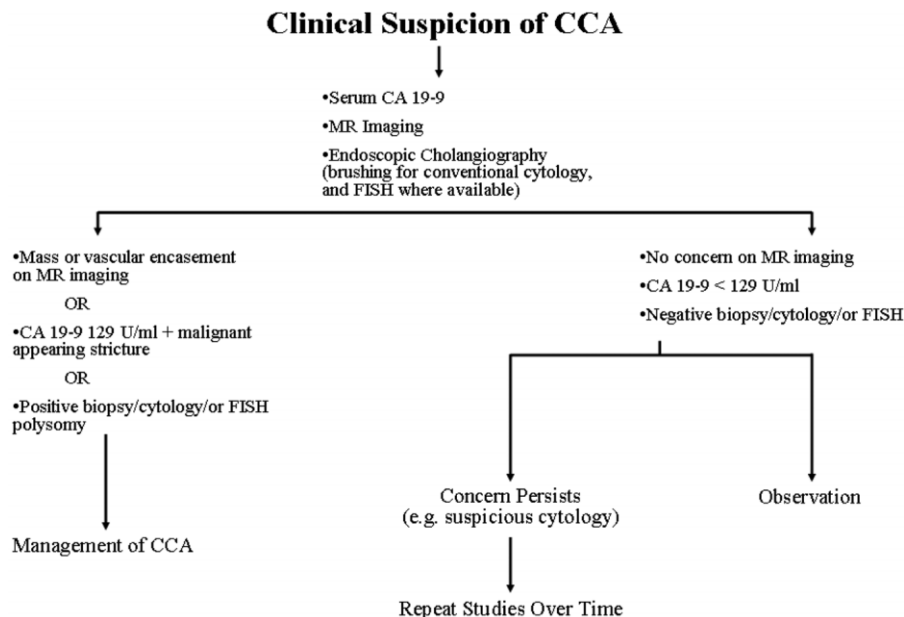


Fig. 2. Diagnostic evaluation of a dominant stricture suspicious for CCA. In patients with clinical suspicion of hilar CCA (e.g., dominant stricture), CA 19-9 serum analysis, endoscopic retrograde cholangiopancreatography, and conventional as well as FISH analysis (where available) of endoscopically obtained biliary brushings of suspicious areas should be performed. In addition, a gadolinium-enhanced magnetic resonance imaging (MRI) of the liver should also be obtained. In cases in which a dominant stricture is identified, CA 19-9 serum levels are >129 U/mL, or biopsy/cytology are positive for carcinoma and/or polysomy, or a mass lesion and/or vascular encasement are identified, management for CCA can be initiated. Bacterial cholangitis should be absent to interpret the serum CA 19-9 level. With a negative MRI scan, CA 19-9 value < 130 U/mL, and negative cytology, a dominant stricture can be assumed to be benign. If the MRI scan is negative but there is significant concern for CCA (e.g., cytology suspicious for adenocarcinoma), the MRI, serum CA 19-9, and ERC with brushings for cytology (including FISH studies where available) should be repeated over time. In some centers, a PET scan may be performed if the clinical suspicion for a CCA is high. If "hot spots" are identified, further management is often directed toward the diagnosis of CCA, although inflammation can result in a false positive PET scan.

sis) following neoadjuvant therapy with external beam and bile duct luminal radiation therapy plus capecitabine.<sup>133</sup> Overall 5-year survival rates are 70% for highly selected patients with perihilar CCA undergoing this complex treatment approach.<sup>134</sup> It should be noted that although endoscopic US-guided fine aspirates of hilar structures have been suggested as a diagnostic approach for CCA,<sup>135</sup> a biopsy of the primary tumor by this technique excludes patients from this protocol, although it is useful for assessing potential lymph node metastasis.<sup>136</sup> This aggressive, multimodality treatment approach has yet to be applied outside of a single center, and, therefore, whether this protocol can be generalized is unclear.

Photodynamic therapy can be palliative for patients with CCA, but its utility in PSC patients has not been reported.<sup>137-139</sup> External beam radiation therapy is fraught with collateral damage to the bile ducts in PSC patients, and its therapeutic efficacy in CCA has never been examined in a randomized trial versus stenting alone; similar comments apply to current medical therapy. Thus, evidence-based therapy for cholangiocarcinoma in patients with PSC is lacking.

#### Recommendations:

**24. We recommend evaluation for CCA in patients with deterioration of their constitutional performance status or liver biochemical-related parameters (1B).**

**25. In patients with CCA and the absence of cirrhosis, we suggest that surgical resection may be performed (2B).**

**26. In patients with early stage CCA not amenable to surgical resection, we recommend that such patients be considered for liver transplantation following neoadjuvant therapy by experienced transplant centers (1B).**

### Natural History and Prognostic Models

The estimated 10-year survival for patients with PSC is approximately 65% in a population based study,<sup>12</sup> but large individual variations exist.<sup>5,140</sup> Because no effective treatment is available outside liver transplantation, prognostic models have been developed to predict the outcome. Although the classical Child-Pugh Class scoring system is informative in regards to outcome,<sup>141</sup> the most recent iteration of the Mayo score suggested that this model provides more valid survival information than the Child-Pugh Class, particularly in patients early in the

course of PSC.<sup>142</sup> This model includes age, bilirubin, serum AST and albumin, and history of variceal bleeding as prognostic parameters. Using this risk score, patients can be divided into the low, intermediate, and high-risk groups. A time-dependent prognostic model for the calculation of short-term survival probability in PSC was also developed with data from five European centers. Bilirubin, albumin, and age at diagnosis of PSC were identified as independent prognostic factors in multivariate analysis.<sup>143</sup> A different approach has been used by Dutch investigators based on the earliest available cholangiographic findings. A combination of age and of intrahepatic and extrahepatic scoring obtained at ERC, as a modification from a previous model was strongly predictive of survival.<sup>144,145</sup> Cholangiographic data were also included in a recent study of 273 German patients with PSC.<sup>5</sup> Also, a recent study indicates that dominant strictures reduce survival free of liver transplantation further supporting a role for cholangiographic information in developing a prognostic model.<sup>146</sup> It should be noted that although prognostic models are useful in predicting outcome in patient cohorts, their ability to precisely predict outcomes in an individual patient may be more limited.

#### **Recommendations:**

**27. In patients with PSC, we recommend against the use of prognostic models for predicting clinical outcomes in an individual patient as no consensus exists regarding the optimal model (1B).**

### **Specific Medical Therapy**

Effective medical management of PSC has been hindered by uncertainty regarding the pathogenesis of the disease and the factors responsible for its progression. Treatments which are efficacious in other cholestatic liver diseases have been tested in PSC with a limited degree of success.<sup>147</sup>

Ursodeoxycholic acid (UDCA) is a hydrophilic, dihydroxy bile acid which is an effective treatment of primary biliary cirrhosis (PBC). UDCA has, therefore, also been investigated as a potential candidate for the treatment of PSC. Small pilot trials of UDCA demonstrated biochemical and histological improvement in PSC patients using doses of 10–15 mg/kg/day.<sup>11,148–150</sup> A more substantial trial was published by Lindor et al. in 1997,<sup>151</sup> recruiting 105 patients in a double blind placebo controlled trial of 13–15mg/kg of UDCA for 2–5 years. The results indicated improvement in serum liver tests but not in symptoms and, most importantly no difference in treatment failure (defined as death; liver transplantation; histologic progression by two stages (of four) or progression to cirrhosis; the development of varices, ascites, or encephalopathy; or quadrupling of the serum bilirubin level for at least three months.<sup>151</sup> Higher doses of

UDCA were then studied on the grounds that larger doses might be necessary to provide sufficient enrichment of the bile acid pool in the context of cholestasis, and that these doses might also enhance a potential immunomodulatory effect of the drug.

The Scandinavian UDCA trial in a group of 219 patients with PSC using a dose of 17–23 mg/kg/day for 5 years demonstrated a trend toward increased survival in the UDCA treated group when compared with placebo,<sup>152</sup> but despite the relatively large number of patients recruited, the study was still insufficiently powered to produce a statistically significant result. Recently, a multicenter study using high doses of 28–30 mg/kg/day of UDCA in 150 patients with PSC over 5 years has been aborted because of an enhanced risk in the UDCA treatment group for death or liver transplantation and serious adverse events particularly in advanced disease whereas biochemical features improved in the whole UDCA group.<sup>153</sup> Thus, the role for UDCA in slowing the progression of PSC-related liver disease is as yet unclear and indeed, high dose UDCA may be harmful.<sup>102</sup>

**Immunosuppressive and Other Agents.** Treatment with corticosteroids and other immunosuppressant agents have not demonstrated any improvement in disease activity or in the outcome of PSC. Small randomized, placebo-controlled or pilot trials have investigated the role of agents with immunosuppressive potency like prednisolone, budesonide, azathioprine, cyclosporin, methotrexate, mycophenolate, and tacrolimus, agents with TNF $\alpha$  antagonizing effects like pentoxifyllin, etanercept and anti-TNF monoclonal antibodies and antifibrotic agents like colchicine, penicillamine, or pirfenidone.<sup>154</sup> There is no evidence that any of these drugs are efficacious and, therefore, none can be recommended for classic PSC. However, these drugs may well have a role in the context of a PSC/AIH overlap syndrome, because pediatric patients and those with evidence of a PSC/AIH overlap syndrome are more likely to respond to immunosuppressive treatment.<sup>36,39,155</sup> A retrospective study in adults also suggested a beneficial role of corticosteroids in a subgroup with AIH overlap features.<sup>156</sup> Corticosteroids may also be indicated as a therapeutic trial following thorough evaluation of suspected immunoglobulin G4-associated cholangitis (IAC)/autoimmune pancreatitis (AIP).<sup>44,157</sup>

#### **Recommendations:**

**28. In adult patients with PSC, we recommend against the use of UDCA as medical therapy (1A).**

**29. In adult patients with PSC and overlap syndrome, we recommend the use of corticosteroids and other immunosuppressive agents for medical therapy (1C).**

## Liver Transplantation

**Indications.** Liver transplant indications for patients with PSC do not differ substantially from those with other forms of chronic liver disease and relate primarily to complications of portal hypertension, impaired quality of life, and chronic liver failure. Indeed, in the United States of America, organ allocation by the Model for End-Stage Liver Disease score is etiology independent.<sup>158,159</sup> Hepatocellular carcinoma occurs in patients with PSC with cirrhosis,<sup>160,161</sup> and the prioritization of these patients for liver transplant is the same as for other patients with hepatocellular carcinoma. Unique liver transplant indications for patients with PSC include intractable pruritus, recurrent bacterial cholangitis, and cholangiocarcinoma. PSC patients with limited stage cholangiocarcinoma can benefit from liver transplantation with careful selection and protocol-driven application of neoadjuvant therapy.<sup>133</sup> Currently, patients with these unique indications may be listed for liver transplantation in the United States via a regional review board appeal process established by the Liver and Intestinal Committee of UNOS (United Network for Organ Sharing). An appealed MELD score may be granted via this process to help prioritize the PSC patient with these complications for liver transplantation.

**Outcome.** Liver transplantation for PSC is highly successful with five-year survival rates of approximately 85% in patients receiving deceased donor allografts<sup>162,163</sup>; long-term survival rates following live donor liver transplantation for PSC patients are unknown but should be similar to the deceased donor allograft survival rates. The preferred biliary anastomosis in these patients is a Roux-Y choledochojejunostomy.<sup>164</sup> The presence of a prior colectomy with or without an ileal pouch-anal anastomosis does not affect liver transplant outcome.<sup>165</sup> PSC liver transplant recipients may be more prone to acute and chronic cellular rejection<sup>162,166</sup>; however, in the era of modern immunosuppression the acute cellular rejection is usually manageable, and chronic rejection is increasingly rare.

Disease recurrence occurs in 20%-25%, after 5-10 years in patients, from the transplant procedure.<sup>162,167,168</sup> Other risk factors for non-anastomotic biliary strictures must be excluded before concluding the patient has recurrent PSC; these non-PSC risk factors for non-anastomotic biliary strictures include donation after cardiac death, prolonged graft ischemic time, ABO blood group incompatibility, hepatic artery thrombosis, CMV infection, chronic rejection, and early onset biliary strictures occurring within 3 months of the transplant procedure.<sup>169</sup> Reported risk factors for recurrent PSC following liver transplantation include active IBD with a need for corti-

steroid therapy, presence of an intact colon, male sex, presence of CCA prior to liver transplantation, and history of acute cellular rejection.<sup>167,170,171</sup> The impact of recurrent PSC on graft survival remains incompletely delineated and controversial; studies either report no effect,<sup>171</sup> or perhaps diminished graft survival.<sup>167,172</sup> There is no established medical therapy for recurrent PSC following liver transplantation.

Management of PSC patients following liver transplantation is similar to management of other liver transplant recipients except for two noted exceptions. PSC patients have an increased metabolic bone disease prevalence which should be managed as discussed elsewhere in this practice guideline.<sup>173</sup> Approximately 60% of patients with IBD before transplantation will experience disease activity despite their immunosuppressive regiment.<sup>83</sup> Management of IBD after transplant has not been well studied and the risk benefit of employing biologic agents in this setting unclear. The rate of proctocolectomy for intractable IBD may be increased in PSC patients following liver transplantation.<sup>174</sup> Patients with PSC plus ulcerative colitis are at increased risk for developing colonic neoplasia which persists after transplantation.<sup>162,175,176</sup> PSC patients with UC should undergo annual surveillance with colonoscopy.

### **Recommendations:**

**30. In patients with advanced liver disease, we recommend the use of liver transplantation as a successful treatment modality (1A).**

**31. We recommend excluding alternate causes of biliary strictures in the posttransplant setting before making a diagnosis of recurrent PSC (1B).**

## Fertility and Pregnancy in PSC

Information on pregnancies in PSC is limited to a few case reports<sup>177</sup> and one series describing 13 pregnancies in 10 patients with PSC.<sup>178</sup> *De novo* pruritus and abdominal pain during pregnancy may occur in PSC patients. The pruritus may be so intense as to warrant early delivery via induction. No serious deterioration of liver function during or after pregnancy has been reported, and outcome has been satisfactory for both patients and children.<sup>178</sup> In a case report, a patient developed a dominant bile duct stricture that required stenting during an ERCP carried out 3 days postpartum.<sup>177</sup> Regarding the effect of pregnancy on the disease course of IBD in general, a large follow-up study of 580 pregnancies in 173 patients with UC and 93 CD patients (177 pregnancies occurring after diagnosis of IBD) concluded that pregnancy did not influence disease phenotype or resection rates, but was associated with a reduction in number of flares in the years afterwards.<sup>179</sup>

PSC patients undergoing pregnancy should be closely monitored with regular blood tests and clinical assessment.<sup>177</sup> In case of suspected bile duct obstruction, ultrasonography can be safely carried out. One should be reluctant to do MRC during the first trimester, but can perform this study in the second and third trimesters. ERC should be reserved for cases in which a need for endoscopic therapy is anticipated. Treatment of intrahepatic cholestasis of pregnancy with UDCA (10-15 mg/kg) has been promising, and no adverse effects in patients or newborns have been noted<sup>180</sup>; however, little information exists regarding the efficacy of UDCA on the pruritus of pregnant PSC patients.

**Recommendations:**

**32. In female patients of childbearing age without portal hypertension, we recommend that pregnancy can be completed safely under close medical supervision (1C).**

## Pediatric PSC

PSC is relatively infrequent in children with a likely incidence less than 20% of that reported in adults.<sup>181</sup> In spite of this, PSC remains an important cause of morbidity and mortality in children, accounting for approximately 2% (223 of 11,322) of the liver transplants performed in children in the United States between 1988 and 2008.<sup>182</sup> The five largest series of pediatric PSC total only 214 cases that were referred over an average of 16 years per center (i.e., two to three cases per year).<sup>33,34,36,183,184</sup> These single-center reports all derive from transplant affiliated programs, so one must assume a bias toward more severe cases. This is especially relevant when considering issues related to prognosis. Development of an evidence based approach to the diagnosis and management of PSC in children is especially problematic given this relatively limited published data and an absence of controlled therapeutic trials. Thus pediatric hepatologists are reliant on data derived from experiences with adult patients, although caution must be exercised in application of these approaches. An urgent need exists for prospective multi-centered studies of PSC in children.

A number of lines of evidence suggest that PSC in children is different and not just an earlier stage in the disease process. Firstly, some inherited diseases and immunologic defects may produce a clinical picture like PSC. These entities usually present clinically during childhood and may have an expanded spectrum of disease, which includes milder variants that when unrecognized are labeled as PSC. For example, mild to moderate defects in the *ABCB4* (*MDR3*) gene are a likely cause of a number of cases of small duct PSC in children.<sup>185,186</sup> Secondly, overlap syndrome of autoimmune hepatitis and PSC appears to be significantly more common in chil-

dren. In some centers evaluation of the biliary system is a standard part of the evaluation of all children with autoimmune hepatitis and those with biliary disease are diagnosed as having autoimmune sclerosing cholangitis (ASC). In these centers ASC is felt to be part of a broad spectrum of autoimmune liver disease in children.<sup>36</sup> The exact criteria for diagnosis of autoimmune overlap in PSC are not well defined nor prospectively correlated with clinical course and/or therapeutic response. Next many reports show that children with PSC have higher serum ALT/AST and gamma glutamyltranspeptidase ( $\gamma$ GTP) levels than their adult counterparts. This has been interpreted to be evidence of a distinct disease process. Finally, many of the important and potentially life-threatening sequelae of PSC, such as cholangiocarcinoma, are rarely observed in childhood.<sup>187</sup> Thus many of the clinical approaches taken in adults related to these issues are of less importance in children.

**Diagnosis.** Measurement of  $\gamma$ GTP is important in identifying potential biliary disease in children, in light of elevated levels of alkaline phosphatase associated with bone growth.<sup>188</sup> Serum aminotransferase elevations may be more significantly elevated in children.<sup>189</sup> MRC is an appropriate first biliary imaging approach in children and often circumvents the need for ERC.<sup>190</sup> Liver biopsy may be of greater relevance in children, especially as it pertains to diagnosis of small duct PSC and in the identification of histologic features of autoimmune or immune-mediated disease.<sup>191</sup> Universal recommendations for measurement of IgG4 and performance of colonoscopy are less clear-cut in children.

**Manifestations of PSC and Their Management.** Dominant strictures are uncommon in children. Their management should be similar to that recommended for adults, although the risk for cholangiocarcinoma is probably less. Bile acid binding resins or rifampin have been used in the management of pruritus related to cholestatic liver disease in children and may be useful in children with PSC.<sup>192,193</sup> Evidence-based approaches to the management of portal hypertension in children are limited, although extrapolations have been made from consensus opinions regarding adults.<sup>194</sup> Hepatic osteodystrophy can occur in children with chronic cholestasis, although approaches to monitoring and management are unclear. Periodic measurement of serum calcium, magnesium, phosphorus, 25-hydroxyvitamin D and PTH levels in children with clinical or biochemical evidence of cholestasis are warranted. Calcium and vitamin D supplementation should be instituted for documented deficiencies. Vitamin E and A status should also be monitored in children with chronic cholestasis with provision of appropriate supplementation. Bisphosphonate therapy in children remains controversial, thus there is no current rationale for

routine monitoring bone mineral density in children with PSC.<sup>195</sup>

**Inflammatory Bowel Disease.** Inflammatory bowel disease was identified in 63% of the children in four major reports of pediatric PSC.<sup>34,36,183,184</sup> More than two thirds of the cases were ulcerative colitis. Prevalence was higher in centers where surveillance colonoscopy was performed and 23% of the cases presented after the diagnosis of PSC. Detailed description of the course of the IBD in these children relative to children without PSC is not available therefore it is difficult to make evidence-based recommendations regarding the management of IBD in the setting of pediatric PSC. It seems reasonable to consider diagnostic full colonoscopy in children who are newly diagnosed with PSC and to have a low threshold for performing this procedure in children who have symptoms consistent with IBD (e.g., diarrhea, growth failure, anemia, etc.). Given the younger age of these patients and their reduced risk of colon cancer, it is more difficult to emphatically recommend on-going surveillance colonoscopy in children, especially in those younger than 16. In those children with IBD who are screened for biochemical evidence of liver disease a  $\gamma$ GTP level should be included in the testing.

**Gallbladder Disease and Cholangiocarcinoma.** Mass lesions of the gallbladder are rarely reported in children, thus annual US imaging of the gallbladder may not be warranted. Similarly CCA is uncommon in childhood.<sup>187</sup> Cross-sectional imaging and measurement of CA 19-9 might be useful in children with stricturing disease who are being considered for possible liver transplantation. Routine surveillance for CCA in children cannot be recommended based on evidence.

**Natural History.** Detailed prognostic models for the course of PSC in children are not available and it is unlikely that one could apply adult models to children. Out of 185 children in the five largest case-series, 39 were reported to require liver transplantation. Certainly these series are biased toward more advanced cases because all of these centers are active liver transplant programs. Common sense suggests that the prognosis is worse in children who present with evidence of cirrhosis or decompensated disease.<sup>34</sup> The impact on natural history of medical therapy or the presence of overlap syndrome is not clear from existing reports.

**Specific Medical Therapy.** In light of the potential differences between pediatric and adult disease, it is difficult to make firm recommendations about the use of UDCA, corticosteroids or immunosuppressants. Caution should be exercised in using UDCA at a dose greater than 20 mg/kg/day. Full disclosure of adult experiences with UDCA to the families of children with PSC is recom-

mended before employing this therapy. Overlapping autoimmune disease has been reported to be more common in children, however the exact diagnostic criteria that indicate the use of corticosteroids and/or immunosuppressants need to be determined. Based on current evidence, it is reasonable to attempt a trial of corticosteroids with or without azathioprine if liver histology shows interface hepatitis, IgG levels are elevated, and autoimmune markers are present.

**Liver Transplantation.** As in adults, liver transplantation is a successful treatment modality for advanced liver disease.<sup>196</sup> Recurrent PSC and/or AIH have been reported after successful liver transplantation for PSC. Heightened monitoring for this phenomenon and for rejection is warranted in children. Enhanced surveillance for colon cancer via annual colonoscopy in adolescents with PSC and IBD is a reasonable approach.

**Recommendations:**

**33. In children liver biopsy should be used to diagnose overlap syndrome with PSC and autoimmune hepatitis (1B).**

**34. In children with overlap syndrome, we recommend the use of immunosuppressive agents for medical therapy (1B).**

**35. We recommend against the use of screening and surveillance procedures for detecting biliary tract cancer in children with PSC; approaches to colorectal cancer screening in children with IBD should not be influenced by the diagnosis of PSC (1B).**

**36. In children with end-stage liver disease from PSC, we recommend the use of liver transplantation as effective therapy (1A).**

**Acknowledgment:** This practice guideline was produced in collaboration with the Practice Guidelines Committee of the American Association for the Study of Liver Diseases. This committee provided extensive peer review of the manuscript. Members of the Practice Guidelines Committee include Jayant A. Talwalkar, M.D., M.P.H. (Chair); Anna Mae Diehl, M.D. (Board Liaison); Jeffrey H. Albrecht, M.D.; Amanda DeVoss, M.M.S., P.A.-C.; José Franco, M.D.; Stephen A. Harrison, M.D.; Kevin Korenblat, M.D.; Simon C. Ling, M.B.Ch.B.; Lawrence U. Liu, M.D.; Paul Martin, M.D.; Kim M. Olthoff, M.D.; Robert S. O'Shea, M.D.; Nancy Reau, M.D.; Adnan Said, M.D.; Margaret C. Shuhart, M.D., M.S.; and Kerry N. Whitt, M.D.

## References

1. Eddy DM. A Manual for Assessing Health Care Practices and Designing Practice Guidelines. Philadelphia, PA: American College of Physicians; 1996:1-126.
2. Position and policy statement: American Gastroenterological Association policy statement on the use of medical practice guidelines by managed

- care organizations and insurance carriers. *Gastroenterology* 1995;108:925-926.
3. Guyatt GH, Oxman AD, Vist GE, Kunz R, Falck-Ytter Y, Alonso-Coello P, et al. GRADE: an emerging consensus on rating quality of evidence and strength of recommendations. *BMJ* 2008;336:924-926.
  4. Maggs JR, Chapman RW. An update on primary sclerosing cholangitis. *Curr Opin Gastroenterol* 2008;24:377-383.
  5. Tischendorf JJ, Hecker H, Kruger M, Manns MP, Meier PN. Characterization, outcome, and prognosis in 273 patients with primary sclerosing cholangitis: A single center study. *Am J Gastroenterol* 2007;102:107-114.
  6. Bjornsson E, Olsson R, Bergquist A, Lindgren S, Braden B, Chapman RW, et al. The natural history of small-duct primary sclerosing cholangitis. *Gastroenterology* 2008;134:975-980.
  7. Gohlke F, Lohse AW, Dienes HP, Lohr H, Marker-Hermann E, Gerken G, et al. Evidence for an overlap syndrome of autoimmune hepatitis and primary sclerosing cholangitis. *J Hepatol* 1996;24:699-705.
  8. Abdalian R, Heathcote EJ. Sclerosing cholangitis: a focus on secondary causes. *HEPATOLOGY* 2006;44:1063-1074.
  9. Webster GJ, Pereira SP, Chapman RW. Autoimmune pancreatitis/IgG4-associated cholangitis and primary sclerosing cholangitis—overlapping or separate diseases? *J Hepatol* 2009;51:398-402.
  10. Broome U, Olsson R, Loof L, Bodemar G, Hultcrantz R, Danielsson A, et al. Natural history and prognostic factors in 305 Swedish patients with primary sclerosing cholangitis. *Gut* 1996;38:610-615.
  11. Beuers U, Spengler U, Kruijs W, Aydemir U, Wiebecke B, Heldwein W, et al. Ursodeoxycholic acid for treatment of primary sclerosing cholangitis: a placebo-controlled trial. *HEPATOLOGY* 1992;16:707-714.
  12. Bambha K, Kim WR, Talwalkar J, Torgerson H, Benson JT, Therneau TM, et al. Incidence, clinical spectrum, and outcomes of primary sclerosing cholangitis in a United States community. *Gastroenterology* 2003;125:1364-1369.
  13. Chapman RW, Arborgh BA, Rhodes JM, Summerfield JA, Dick R, Scheuer PJ, et al. Primary sclerosing cholangitis: a review of its clinical features, cholangiography, and hepatic histology. *Gut* 1980;21:870-877.
  14. Boberg KM, Fausa O, Haaland T, Holter E, Mellbye OJ, Spurkland A, et al. Features of autoimmune hepatitis in primary sclerosing cholangitis: an evaluation of 114 primary sclerosing cholangitis patients according to a scoring system for the diagnosis of autoimmune hepatitis. *HEPATOLOGY* 1996;23:1369-1376.
  15. Hov JR, Boberg KM, Karlsen TH. Autoantibodies in primary sclerosing cholangitis. *World J Gastroenterol* 2008;14:3781-3791.
  16. van de Meeberg PC, Portincasa P, Wolfhagen FH, van Erpecum KJ, VanBerge-Henegouwen GP. Increased gall bladder volume in primary sclerosing cholangitis. *Gut* 1996;39:594-599.
  17. Said K, Glaumann H, Bergquist A. Gallbladder disease in patients with primary sclerosing cholangitis. *J Hepatol* 2008;48:598-605.
  18. Campbell WL, Ferris JV, Holbert BL, Thaete FL, Baron RL. Biliary tract carcinoma complicating primary sclerosing cholangitis: evaluation with CT, cholangiography, US, and MR imaging. *Radiology* 1998;207:41-50.
  19. Ament AE, Haaga JR, Wiedenmann SD, Barkmeier JD, Morrison SC. Primary sclerosing cholangitis: CT findings. *J Comput Assist Tomogr* 1983;7:795-800.
  20. Campbell WL, Peterson MS, Federle MP, Siqueira ES, Slivka A, Grazioli L, et al. Using CT and cholangiography to diagnose biliary tract carcinoma complicating primary sclerosing cholangitis. *AJR Am J Roentgenol* 2001;177:1095-1100.
  21. Dodd GD 3rd, Baron RL, Oliver JH 3rd, Federle MP. End-stage primary sclerosing cholangitis: CT findings of hepatic morphology in 36 patients. *Radiology* 1999;211:357-362.
  22. Johnson KJ, Olliff JF, Olliff SP. The presence and significance of lymphadenopathy detected by CT in primary sclerosing cholangitis. *Br J Radiol* 1998;71:1279-1282.
  23. MacCarty RL, LaRusso NF, Wiesner RH, Ludwig J. Primary sclerosing cholangitis: findings on cholangiography and pancreatography. *Radiology* 1983;149:39-44.
  24. Lee YM, Kaplan MM. Primary sclerosing cholangitis. *N Engl J Med* 1995;332:924-933.
  25. Bangarulingam SY, Gossard AA, Petersen BT, Ott BJ, Lindor KD. Complications of endoscopic retrograde cholangiopancreatography in primary sclerosing cholangitis. *Am J Gastroenterol* 2009;104:855-860.
  26. Berstad AE, Aabakken L, Smith HJ, Aasen S, Boberg KM, Schruppf E. Diagnostic accuracy of magnetic resonance and endoscopic retrograde cholangiography in primary sclerosing cholangitis. *Clin Gastroenterol Hepatol* 2006;4:514-520.
  27. Angulo P, Pearce DH, Johnson CD, Henry JJ, LaRusso NF, Petersen BT, et al. Magnetic resonance cholangiography in patients with biliary disease: its role in primary sclerosing cholangitis. *J Hepatol* 2000;33:520-527.
  28. Burak KW, Angulo P, Lindor KD. Is there a role for liver biopsy in primary sclerosing cholangitis? *Am J Gastroenterol* 2003;98:1155-1158.
  29. el-Shabrawi M, Wilkinson ML, Portmann B, Mieli-Vergani G, Chong SK, Williams R, et al. Primary sclerosing cholangitis in childhood. *Gastroenterology* 1987;92:1226-1235.
  30. Minuk GY, Sutherland LR, Pappas G, Kelly JK, Martin SE. Autoimmune chronic active hepatitis (lupoid hepatitis) and primary sclerosing cholangitis in two young adult females. *Can J Gastroenterol* 1988;2:22-27.
  31. Rabinovitz M, Demetris AJ, Bou-Abboud CF, Van Thiel DH. Simultaneous occurrence of primary sclerosing cholangitis and autoimmune chronic active hepatitis in a patient with ulcerative colitis. *Dig Dis Sci* 1992;37:1606-1611.
  32. Lawrence SP, Sherman KE, Lawson JM, Goodman ZD. A 39 year old man with chronic hepatitis. *Semin Liver Dis* 1994;14:97-105.
  33. Debray D, Pariente D, Urvoas E, Hadchouel M, Bernard O. Sclerosing cholangitis in children. *J Pediatr* 1994;124:49-56.
  34. Wilschanski M, Chait P, Wade JA, Davis L, Corey M, St Louis P, et al. Primary sclerosing cholangitis in 32 children: clinical, laboratory, and radiographic features, with survival analysis. *HEPATOLOGY* 1995;22:1415-1422.
  35. McNair AN, Moloney M, Portmann BC, Williams R, McFarlane IG. Autoimmune hepatitis overlapping with primary sclerosing cholangitis in five cases. *Am J Gastroenterol* 1998;93:777-784.
  36. Gregorio GV, Portmann B, Karani J, Harrison P, Donaldson PT, Vergani D, et al. Autoimmune hepatitis/sclerosing cholangitis overlap syndrome in childhood: a 16-year prospective study. *HEPATOLOGY* 2001;33:544-553.
  37. Al-Chalabi T, Portmann BC, Bernal W, McFarlane IG, Heneghan MA. Autoimmune hepatitis overlap syndromes: an evaluation of treatment response, long-term outcome and survival. *Aliment Pharmacol Ther* 2008;28:209-220.
  38. Alvarez F, Berg PA, Bianchi FB, Bianchi L, Burroughs AK, Cancado EL, et al. International Autoimmune Hepatitis Group Report: review of criteria for diagnosis of autoimmune hepatitis. *J Hepatol* 1999;31:929-938.
  39. Beuers U, Rust C. Overlap syndromes. *Semin Liver Dis* 2005;25:311-320.
  40. van Buuren HR, van Hoogstraten HJE, Terkivatan T, Schalm SW, Vlegaar FP. High prevalence of autoimmune hepatitis among patients with primary sclerosing cholangitis. *J Hepatol* 2000;33:543-548.
  41. Kaya M, Angulo P, Lindor KD. Overlap of autoimmune hepatitis and primary sclerosing cholangitis: an evaluation of a modified scoring system. *J Hepatol* 2000;33:537-542.
  42. Floreani A, Rizzotto ER, Ferrara F, Carderi I, Caroli D, Blasone L, et al. Clinical course and outcome of autoimmune hepatitis/primary sclerosing cholangitis overlap syndrome. *Am J Gastroenterol* 2005;100:1516-1522.
  43. Kamisawa T, Egawa N, Tsuruta K, Okamoto A, Funata N. Primary sclerosing cholangitis may be overestimated in Japan. *J Gastroenterol* 2005;40:318-319.
  44. Bjornsson E, Chari ST, Smyrk TC, Lindor K. Immunoglobulin G4 associated cholangitis: description of an emerging clinical entity based on review of the literature. *HEPATOLOGY* 2007;45:1547-1554.

45. Mendes FD, Jorgensen R, Keach J, Katzmann JA, Smyrk T, Donlinger J, et al. Elevated serum IgG4 concentration in patients with primary sclerosing cholangitis. *Am J Gastroenterol* 2006;101:2070-2075.
46. Stiehl A, Rudolph G, Kloters-Plachky P, Sauer P, Walker S. Development of dominant bile duct stenoses in patients with primary sclerosing cholangitis treated with ursodeoxycholic acid: outcome after endoscopic treatment. *J Hepatol* 2002;36:151-156.
47. Bjornsson E, Lindqvist-Ottosson J, Asztely M, Olsson R. Dominant strictures in patients with primary sclerosing cholangitis. *Am J Gastroenterol* 2004;99:502-508.
48. Okolicsanyi L, Fabris L, Viaggi S, Carulli N, Podda M, Ricci G. Primary sclerosing cholangitis: clinical presentations, natural history and prognostic variables: an Italian multicenter study. *Eur J Gastroenterol Hepatol* 1996;8:685-691.
49. Lindberg B, Arnelo U, Bergquist A, Thorne A, Hjerpe A, Granqvist S, et al. Diagnosis of biliary strictures in conjunction with endoscopic retrograde cholangiopancreatography, with special reference to patients with primary sclerosing cholangitis. *Endoscopy* 2002;34:909-916.
50. Wiesner RH, Grambsch PM, Dickson ER, Ludwig J, MacCarty RL, Hunter EB, et al. Primary sclerosing cholangitis: natural history, prognostic factors and survival analysis. *HEPATOLOGY* 1989;10:430-436.
51. May GR, Bender CE, LaRusso NF, Wiesner RH. Nonoperative dilatation of dominant strictures in primary sclerosing cholangitis. *AJR Am J Roentgenol* 1985;145:1061-1064.
52. Kaya M, Petersen BT, Angulo P, Baron TH, Andrews JC, Gostout CJ, et al. Balloon dilation compared to stenting of dominant strictures in primary sclerosing cholangitis. *Am J Gastroenterol* 2001;96:1059-1066.
53. Ahrendt SA, Pitt HA, Kalloo AN, Venbrux AC, Klein AS, Herlong HF, et al. Primary sclerosing cholangitis: resect, dilate, or transplant? *Ann Surg* 1998;227:412-423.
54. Gaing AA, Geders JM, Cohen SA, Siegel JH. Endoscopic management of primary sclerosing cholangitis: review, and report of an open series. *Am J Gastroenterol* 1993;88:2000-2008.
55. Johnson GK, Geenen JE, Venu RP, Schmalz MJ, Hogan WJ. Endoscopic treatment of biliary tract strictures in sclerosing cholangitis: a larger series and recommendations for treatment. *Gastrointest Endosc* 1991;37:38-43.
56. Gaing AA, Geders JM, Cohen SA, Siegel JH. Endoscopic therapy for primary sclerosing cholangitis: Report of an ongoing series. *Gastrointest Endosc* 1992;38:261-262.
57. Kalloo AN. Primary sclerosing cholangitis: an overview. In: Cameron JL, ed. *Current Surgical Therapy*. 7th ed. St. Louis, MO: Mosby; 2001:474-476.
58. Baluyut AR, Sherman S, Lehman GA, Hoen H, Chalasani N. Impact of endoscopic therapy on the survival of patients with primary sclerosing cholangitis. *Gastrointest Endosc* 2001;53:308-312.
59. Gluck M, Cantone NR, Brandabur JJ, Patterson DJ, Bredfeldt JE, Kozairek RA. A twenty-year experience with endoscopic therapy for symptomatic primary sclerosing cholangitis. *J Clin Gastroenterol* 2008;42:1032-1039.
60. Myburgh JA. Surgical biliary drainage in primary sclerosing cholangitis. The role of the Hepp-Couinaud approach. *Arch Surg* 1994;129:1057-1062.
61. Cameron JL, Pitt HA, Zinner MJ, Herlong HF, Kaufman SL, Boitnott JK, et al. Resection of hepatic duct bifurcation and transhepatic stenting for sclerosing cholangitis. *Ann Surg* 1988;207:614-622.
62. Pawlick TM, Olbrecht VA, Pitt HA, Gleisner AL, Choti MA, Schulick RD, et al. Primary sclerosing cholangitis: role of extrahepatic biliary resection. *J Am Coll Surg* 2008;206:822-830.
63. Bjornsson ES, Kilander AF, Olsson RG. Bile duct bacterial isolates in primary sclerosing cholangitis and certain other forms of cholestasis—a study of bile cultures from ERCP. *HepatoGastroenterology* 2000;47:1504-1508.
64. Boomkens SY, de Rave S, Pot RG, Egberink HF, Penning LC, Rothuizen J, et al. The role of *Helicobacter* spp. in the pathogenesis of primary biliary cirrhosis and primary sclerosing cholangitis. *FEMS Immunol Med Microbiol* 2005;44:221-225.
65. Kaplan GG, Laupland KB, Butzner D, Urbanski SJ, Lee SS. The burden of large and small duct primary sclerosing cholangitis in adults and children: a population-based analysis. *Am J Gastroenterol* 2007;102:1042-1049.
66. Pohl J, Ring A, Stremmel W, Stiehl A. The role of dominant stenoses in bacterial infections of bile ducts in primary sclerosing cholangitis. *Eur J Gastroenterol Hepatol* 2006;18:69-74.
67. Abraham SC, Kamath PS, Eghtesad B, Demetris AJ, Krasinskas AM. Liver transplantation in precirrhotic biliary tract disease: Portal hypertension is frequently associated with nodular regenerative hyperplasia and obliterative portal venopathy. *Am J Surg Pathol* 2006;30:1454-1461.
68. Lindor KD, Gershwin ME, Poupon R, Kaplan M, Bergasa NV, Heathcote EJ. Primary biliary cirrhosis. *HEPATOLOGY* 2009;50:291-308.
69. Zein CO, Lindor KD, Angulo P. Prevalence and predictors of esophageal varices in patients with primary sclerosing cholangitis. *HEPATOLOGY* 2004;39:204-210.
70. Zapata-Colindres JC, Montano-Loza A, Zepeda-Gomez S, Uscanga L. Predictive factors for portal hypertension in patients with primary sclerosing cholangitis [in Spanish]. *Gastroenterol Hepatol* 2006;29:7-10.
71. Garcia-Tsao G, Sanyal AJ, Grace ND, Carey W. Prevention and management of gastroesophageal varices and variceal hemorrhage in cirrhosis. *HEPATOLOGY* 2007;46:922-938.
72. Angulo P, Therneau TM, Jorgensen A, DeSotel CK, Egan KS, Dickson ER, et al. Bone disease in patients with primary sclerosing cholangitis: prevalence, severity and prediction of progression. *J Hepatol* 1998;29:729-735.
73. Campbell MS, Lichtenstein GR, Rhim AD, Pazianas M, Faust T. Severity of liver disease does not predict osteopenia or low bone mineral density in primary sclerosing cholangitis. *Liver Int* 2005;25:311-316.
74. Collier J. Bone disorders in chronic liver disease. *HEPATOLOGY* 2007;46:1271-1278.
75. Zein CO, Jorgensen RA, Clarke B, Wenger DE, Keach JC, Angulo P, et al. Alendronate improves bone mineral density in primary biliary cirrhosis: a randomized placebo-controlled trial. *HEPATOLOGY* 2005;42:762-771.
76. Fausa O, Schrupf E, Elgjo K. Relationship of inflammatory bowel disease and primary sclerosing cholangitis. *Semin Liver Dis* 1991;11:31-39.
77. Loftus EV Jr, Harewood GC, Loftus CG, Tremaine WJ, Harmsen WS, Zinsmeister AR, et al. PSC-IBD: a unique form of inflammatory bowel disease associated with primary sclerosing cholangitis. *Gut* 2005;54:91-96.
78. Rasmussen HH, Fallingborg JF, Mortensen PB, Vyberg M, Tage-Jensen U, Rasmussen SN. Hepatobiliary dysfunction and primary sclerosing cholangitis in patients with Crohn's disease. *Scand J Gastroenterol* 1997;32:604-610.
79. Broome U, Bergquist A. Primary sclerosing cholangitis, inflammatory bowel disease, and colon cancer. *Semin Liver Dis* 2006;26:31-41.
80. Kitiyakara T, Chapman RW. Chemoprevention and screening in primary sclerosing cholangitis. *Postgrad Med J* 2008;84:228-237.
81. Aadland E, Schrupf E, Fausa O, Elgjo K, Heilo A, Aakhus T, et al. Primary sclerosing cholangitis: a long-term follow-up study. *Scand J Gastroenterol* 1987;22:655-664.
82. Schrupf E, Elgjo K, Fausa O, Gjone E, Kolmannskog F, Ritland S. Sclerosing cholangitis in ulcerative colitis. *Scand J Gastroenterol* 1980;15:689-697.
83. Verdonk RC, Dijkstra G, Haagsma EB, Shostrom VK, Van den Berg AP, Kleibeuker JH, et al. Inflammatory bowel disease after liver transplantation: risk factors for recurrence and de novo disease. *Am J Transplant* 2006;6:1422-1429.
84. Faubion WA Jr, Loftus EV, Sandborn WJ, Freese DK, Perrault J. Pediatric "PSC-IBD": a descriptive report of associated inflammatory bowel disease among pediatric patients with psc. *J Pediatr Gastroenterol Nutr* 2001;33:296-300.
85. Lundqvist K, Broome U. Differences in colonic disease activity in patients with ulcerative colitis with and without primary sclerosing cholangitis: a case control study. *Dis Colon Rectum* 1997;40:451-456.



86. Kartheuser AH, Dozois RR, LaRusso NF, Wiesner RH, Ilstrup DM, Schleck CD. Comparison of surgical treatment of ulcerative colitis associated with primary sclerosing cholangitis: ileal pouch-anal anastomosis versus Brooke ileostomy. *Mayo Clin Proc* 1996;71:748-756.
87. Penna C, Dozois R, Tremaine W, Sandborn W, LaRusso N, Schleck C, et al. Pouchitis after ileal pouch-anal anastomosis for ulcerative colitis occurs with increased frequency in patients with associated primary sclerosing cholangitis. *Gut* 1996;38:234-239.
88. Stahlberg D, Veress B, Tribukait B, Broome U. Atrophy and neoplastic transformation of the ileal pouch mucosa in patients with ulcerative colitis and primary sclerosing cholangitis: a case control study. *Dis Colon Rectum* 2003;46:770-778.
89. Eaden JA, Mayberry JF. Guidelines for screening and surveillance of asymptomatic colorectal cancer in patients with inflammatory bowel disease. *Gut* 2002;51(Suppl. 5):V10-V12.
90. Bansal P, Sonnenberg A. Risk factors of colorectal cancer in inflammatory bowel disease. *Am J Gastroenterol* 1996;91:44-48.
91. Brentnall TA, Haggitt RC, Rabinovitch PS, Kimmey MB, Bronner MP, Levine DS, et al. Risk and natural history of colonic neoplasia in patients with primary sclerosing cholangitis and ulcerative colitis. *Gastroenterology* 1996;110:331-338.
92. Kornfeld D, Ekblom A, Ihre T. Is there an excess risk for colorectal cancer in patients with ulcerative colitis and concomitant primary sclerosing cholangitis? A population based study. *Gut* 1997;41:522-525.
93. Shetty K, Rybicki L, Brzezinski A, Carey WD, Lashner BA. The risk for cancer or dysplasia in ulcerative colitis patients with primary sclerosing cholangitis. *Am J Gastroenterol* 1999;94:1643-1649.
94. Soetikno RM, Lin OS, Heidenreich PA, Young HS, Blackstone MO. Increased risk of colorectal neoplasia in patients with primary sclerosing cholangitis and ulcerative colitis: a meta-analysis. *Gastrointest Endosc* 2002;56:48-54.
95. Brackmann S, Andersen SN, Aamodt G, Langmark F, Clausen OP, Aadland E, et al. Relationship between clinical parameters and the colitis-colorectal cancer interval in a cohort of patients with colorectal cancer in inflammatory bowel disease. *Scand J Gastroenterol* 2008;1-10.
96. Jayaram H, Satsangi J, Chapman RW. Increased colorectal neoplasia in chronic ulcerative colitis complicated by primary sclerosing cholangitis: fact or fiction? *Gut* 2001;48:430-434.
97. Vleggaar FP, Lutgens MW, Claessen MM. Review article: The relevance of surveillance endoscopy in long-lasting inflammatory bowel disease. *Aliment Pharmacol Ther* 2007;26(Suppl. 2):47-52.
98. Kaplan GG, Heitman SJ, Hilsden RJ, Urbanski S, Myers RP, Lee SS, et al. Population-based analysis of practices and costs of surveillance for colonic dysplasia in patients with primary sclerosing cholangitis and colitis. *Inflamm Bowel Dis* 2007;13:1401-1407.
99. Pardi DS, Loftus EV Jr, Kremers WK, Keach J, Lindor KD. Ursodeoxycholic acid as a chemopreventive agent in patients with ulcerative colitis and primary sclerosing cholangitis. *Gastroenterology* 2003;124:889-893.
100. Tung BY, Emond MJ, Haggitt RC, Bronner MP, Kimmey MB, Kowdley KV, et al. Ursodiol use is associated with lower prevalence of colonic neoplasia in patients with ulcerative colitis and primary sclerosing cholangitis. *Ann Intern Med* 2001;134:89-95.
101. Wolf JM, Rybicki LA, Lashner BA. The impact of ursodeoxycholic acid on cancer, dysplasia and mortality in ulcerative colitis patients with primary sclerosing cholangitis. *Aliment Pharmacol Ther* 2005;22:783-788.
102. Lindor KD, Kowdley KV, Luketic VA, Harrison ME, McCashland T, Befeler AS, et al. High-dose ursodeoxycholic acid for the treatment of primary sclerosing cholangitis. *HEPATOLOGY* 2009;50:808-814.
103. Wiesner RH, LaRusso NF, Dozois RR, Beaver SJ. Peristomal varices after proctocolectomy in patients with primary sclerosing cholangitis. *Gastroenterology* 1986;90:316-322.
104. Gorgun E, Remzi FH, Manilich E, Preen M, Shen B, Fazio VW. Surgical outcome in patients with primary sclerosing cholangitis undergoing ileal pouch-anal anastomosis: a case-control study. *Surgery* 2005;138:631-637; discussion 637-639.
105. Brandt DJ, MacCarty RL, Charboneau JW, LaRusso NF, Wiesner RH, Ludwig J. Gallbladder disease in patients with primary sclerosing cholangitis. *AJR Am J Roentgenol* 1988;150:571-574.
106. Buckles DC, Lindor KD, Larusso NF, Petrovic LM, Gores GJ. In primary sclerosing cholangitis, gallbladder polyps are frequently malignant. *Am J Gastroenterol* 2002;97:1138-1142.
107. Lewis JT, Talwalkar JA, Rosen CB, Smyrk TC, Abraham SC. Prevalence and risk factors for gallbladder neoplasia in patients with primary sclerosing cholangitis: evidence for a metaplasia-dysplasia-carcinoma sequence. *Am J Surg Pathol* 2007;31:907-913.
108. Bergquist A, Ekblom A, Olsson R, Kornfeldt D, Loof L, Danielsson A, et al. Hepatic and extrahepatic malignancies in primary sclerosing cholangitis. *J Hepatol* 2002;36:321-327.
109. Burak K, Angulo P, Pasha TM, Egan K, Petz J, Lindor KD. Incidence and risk factors for cholangiocarcinoma in primary sclerosing cholangitis. *Am J Gastroenterol* 2004;99:523-526.
110. Claessen MM, Vleggaar FP, Tytgat KM, Siersema PD, van Buuren HR. High lifetime risk of cancer in primary sclerosing cholangitis. *J Hepatol* 2009;50:158-164.
111. Miros M, Kerlin P, Walker N, Harper J, Lynch S, Strong R. Predicting cholangiocarcinoma in patients with primary sclerosing cholangitis before transplantation. *Gut* 1991;32:1369-1373.
112. Farges O, Malassagne B, Sebah M, Bismuth H. Primary sclerosing cholangitis: liver transplantation or biliary surgery. *Surgery* 1995;117:146-155.
113. Lazaridis KN, Gores GJ. Primary sclerosing cholangitis and cholangiocarcinoma. *Semin Liver Dis* 2006;26:42-51.
114. Melum E, Karlsen TH, Schrupp E, Bergquist A, Thorsby E, Boberg KM, et al. Cholangiocarcinoma in primary sclerosing cholangitis is associated with NKG2D polymorphisms. *HEPATOLOGY* 2008;47:90-96.
115. Boberg KM, Bergquist A, Mitchell S, Pares A, Rosina F, Broome U, et al. Cholangiocarcinoma in primary sclerosing cholangitis: risk factors and clinical presentation. *Scand J Gastroenterol* 2002;37:1205-1211.
116. Broome U, Lofberg R, Veress B, Eriksson LS. Primary sclerosing cholangitis and ulcerative colitis: evidence for increased neoplastic potential. *HEPATOLOGY* 1995;22:1404-1408.
117. Fevery J, Verslype C, Lai G, Aerts R, Van Steenberghe W. Incidence, diagnosis, and therapy of cholangiocarcinoma in patients with primary sclerosing cholangitis. *Dig Dis Sci* 2007;52:3123-3135.
118. Steinberg W. The clinical utility of the CA 19-9 tumor-associated antigen. *Am J Gastroenterol* 1990;85:350-355.
119. Nichols JC, Gores GJ, LaRusso NF, Wiesner RH, Nagorney DM, Ritts RE Jr. Diagnostic role of serum CA 19-9 for cholangiocarcinoma in patients with primary sclerosing cholangitis. *Mayo Clin Proc* 1993;68:874-879.
120. Levy C, Lymp J, Angulo P, Gores GJ, Larusso N, Lindor KD. The value of serum CA 19-9 in predicting cholangiocarcinomas in patients with primary sclerosing cholangitis. *Dig Dis Sci* 2005;50:1734-1740.
121. Chalasani N, Baluyut A, Ismail A, Zaman A, Sood G, Ghalib R, et al. Cholangiocarcinoma in patients with primary sclerosing cholangitis: a multicenter case-control study. *HEPATOLOGY* 2000;31:7-11.
122. Charatcharoenwitthaya P, Enders FB, Halling KC, Lindor KD. Utility of serum tumor markers, imaging, and biliary cytology for detecting cholangiocarcinoma in primary sclerosing cholangitis. *HEPATOLOGY* 2008;48:1106-1117.
123. Siqueira E, Schoen RE, Silverman W, Martin J, Rabinovitch M, Weissfeld JL, et al. Detecting cholangiocarcinoma in patients with primary sclerosing cholangitis. *Gastrointest Endosc* 2002;56:40-47.
124. Tischendorf JJ, Kruger M, Trautwein C, Duckstein N, Schneider A, Manns MP, et al. Cholangioscopic characterization of dominant bile duct stenoses in patients with primary sclerosing cholangitis. *Endoscopy* 2006;38:665-669.
125. Moreno Luna LE, Kipp B, Halling KC, Sebo TJ, Kremers WK, Roberts LR, et al. Advanced cytologic techniques for the detection of malignant pancreaticobiliary strictures. *Gastroenterology* 2006;131:1064-1072.

126. Boberg KM, Jepsen P, Clausen OP, Foss A, Aabakken L, Schruppf E. Diagnostic benefit of biliary brush cytology in cholangiocarcinoma in primary sclerosing cholangitis. *J Hepatol* 2006;45:568-574.
127. Keiding S, Hansen SB, Rasmussen HH, Gee A, Kruse A, Roelsgaard K, et al. Detection of cholangiocarcinoma in primary sclerosing cholangitis by positron emission tomography. *HEPATOLOGY* 1998;28:700-706.
128. Fevery J, Buchel O, Nevens F, Verslype C, Stroobants S, Van Steenberghe W. Positron emission tomography is not a reliable method for the early diagnosis of cholangiocarcinoma in patients with primary sclerosing cholangitis. *J Hepatol* 2005;43:358-360.
129. Khan SA, Miras A, Pelling M, Taylor-Robinson SD. Cholangiocarcinoma and its management. *Gut* 2007;56:1755-1756.
130. Kaya M, de Groen PC, Angulo P, Nagorney DM, Gunderson LL, Gores GJ, et al. Treatment of cholangiocarcinoma complicating primary sclerosing cholangitis: the Mayo Clinic experience. *Am J Gastroenterol* 2001;96:1164-1169.
131. Rosen CB, Nagorney DM. Cholangiocarcinoma complicating primary sclerosing cholangitis. *Semin Liver Dis* 1991;11:26-30.
132. Rosen CB, Nagorney DM, Wiesner RH, Coffey RJ Jr, LaRusso NF. Cholangiocarcinoma complicating primary sclerosing cholangitis. *Ann Surg* 1991;213:21-25.
133. Gores GJ, Nagorney DM, Rosen CB. Cholangiocarcinoma: is transplantation an option? For whom? *J Hepatol* 2007;47:455-459.
134. Rea DJ, Heimbach JK, Rosen CB, Haddock MG, Alberts SR, Kremers WK, et al. Liver transplantation with neoadjuvant chemoradiation is more effective than resection for hilar cholangiocarcinoma. *Ann Surg* 2005;242:451-458; discussion 458-461.
135. Fritscher-Ravens A, Broering DC, Knoefel WT, Rogiers X, Swain P, Thonke F, et al. EUS-guided fine-needle aspiration of suspected hilar cholangiocarcinoma in potentially operable patients with negative brush cytology. *Am J Gastroenterol* 2004;99:45-51.
136. Gleeson FC, Rajan E, Levy MJ, Clain JE, Topazian MD, Harewood GC, et al. EUS-guided FNA of regional lymph nodes in patients with unresectable hilar cholangiocarcinoma. *Gastrointest Endosc* 2008;67:438-443.
137. Baron TH. Photodynamic therapy: standard of care for palliation of cholangiocarcinoma? *Clin Gastroenterol Hepatol* 2008;6:266-267.
138. Kahaleh M, Mishra R, Shami VM, Northup PG, Berg CL, Bashlor P, et al. Unresectable cholangiocarcinoma: comparison of survival in biliary stenting alone versus stenting with photodynamic therapy. *Clin Gastroenterol Hepatol* 2008;6:290-297.
139. Ortner MA, Liebetruh J, Schreiber S, Hanft M, Wruck U, Fusco V, et al. Photodynamic therapy of nonresectable cholangiocarcinoma. *Gastroenterology* 1998;114:536-542.
140. Helzberg JH, Petersen JM, Boyer JL. Improved survival with primary sclerosing cholangitis. A review of clinicopathologic features and comparison of symptomatic and asymptomatic patients. *Gastroenterology* 1987;92:1869-1875.
141. Shetty K, Rybicki L, Carey WD. The Child-Pugh classification as a prognostic indicator for survival in primary sclerosing cholangitis. *HEPATOLOGY* 1997;25:1049-1053.
142. Kim WR, Poterucha JJ, Wiesner RH, LaRusso NF, Lindor KD, Petz J, et al. The relative role of the Child-Pugh classification and the Mayo natural history model in the assessment of survival in patients with primary sclerosing cholangitis. *HEPATOLOGY* 1999;29:1643-1648.
143. Boberg KM, Rocca G, Egeland T, Bergquist A, Broome U, Caballeria L, et al. Time-dependent Cox regression model is superior in prediction of prognosis in primary sclerosing cholangitis. *HEPATOLOGY* 2002;35:652-657.
144. Majoie CB, Reeders JW, Sanders JB, Huijbregtse K, Jansen PL. Primary sclerosing cholangitis: a modified classification of cholangiographic findings. *AJR Am J Roentgenol* 1991;157:495-497.
145. Ponsioen CY, Vrouenraets SM, Prawirodirdjo W, Rajaram R, Rauws EA, Mulder CJ, et al. Natural history of primary sclerosing cholangitis and prognostic value of cholangiography in a Dutch population. *Gut* 2002;51:562-566.
146. Rudolph G, Gotthardt D, Kloters-Plachky P, Kulaksiz H, Rost D, Stiehl A. Influence of dominant bile duct stenoses and biliary infections on outcome in primary sclerosing cholangitis. *J Hepatol* 2009;51:149-155.
147. Cullen SN, Chapman RW. The medical management of primary sclerosing cholangitis. *Semin Liver Dis* 2006;26:52-61.
148. Chazouilleres O, Poupon R, Capron JP, Metman EH, Dhumeaux D, Amouretti M, et al. Ursodeoxycholic acid for primary sclerosing cholangitis. *J Hepatol* 1990;11:120-123.
149. O'Brien CB, Senior JR, Arora-Mirchandani R, Batta AK, Salen G. Ursodeoxycholic acid for the treatment of primary sclerosing cholangitis: a 30-month pilot study. *HEPATOLOGY* 1991;14:838-847.
150. Stiehl A. Ursodeoxycholic acid therapy in treatment of primary sclerosing cholangitis. *Scand J Gastroenterol Suppl* 1994;204:59-61.
151. Lindor KD. Ursodiol for primary sclerosing cholangitis. Mayo Primary Sclerosing Cholangitis-Ursodeoxycholic Acid Study Group. *N Engl J Med* 1997;336:691-695.
152. Olsson R, Boberg KM, de Muckadell OS, Lindgren S, Hultcrantz R, Folvik G, et al. High-dose ursodeoxycholic acid in primary sclerosing cholangitis: a 5-year multicenter, randomized, controlled study. *Gastroenterology* 2005;129:1464-1472.
153. Lindor KD, Enders FB, Schmol JA, Hoskin TL, Jorgensen RA, Petz JL, et al. Randomized, double-blind controlled trial of high-dose ursodeoxycholic acid for primary sclerosing cholangitis [Abstract]. *HEPATOLOGY* 2008;48:378A.
154. Cullen SN, Chapman RW. Review article: current management of primary sclerosing cholangitis. *Aliment Pharmacol Ther* 2005;21:933-948.
155. Woodward J, Neuberger J. Autoimmune overlap syndromes. *HEPATOLOGY* 2001;33:994-1002.
156. Boberg KM, Egeland T, Schruppf E. Long-term effect of corticosteroid treatment in primary sclerosing cholangitis patients. *Scand J Gastroenterol* 2003;38:991-995.
157. Ghazale A, Chari ST, Zhang L, Smyrk TC, Takahashi N, Levy MJ, et al. Immunoglobulin G4-associated cholangitis: clinical profile and response to therapy. *Gastroenterology* 2008;134:706-715.
158. Wiesner RH, McDiarmid SV, Kamath PS, Edwards EB, Malinchoc M, Kremers WK, et al. MELD and PELD: application of survival models to liver allocation. *Liver Transpl* 2001;7:567-580.
159. Freeman RB, Edwards EB, Harper AM. Waiting list removal rates among patients with chronic and malignant liver diseases. *Am J Transplant* 2006;6:1416-1421.
160. Bergquist A, Glaumann H, Persson B, Broome U. Risk factors and clinical presentation of hepatobiliary carcinoma in patients with primary sclerosing cholangitis: a case-control study. *HEPATOLOGY* 1998;27:311-316.
161. Leidenius M, Hockersted K, Broome U, Ericzon BG, Friman S, Olausson M, et al. Hepatobiliary carcinoma in primary sclerosing cholangitis: a case control study. *J Hepatol* 2001;34:792-798.
162. Graziadei IW, Wiesner RH, Marotta PJ, Porayko MK, Hay JE, Charlton MR, et al. Long-term results of patients undergoing liver transplantation for primary sclerosing cholangitis. *HEPATOLOGY* 1999;30:1121-1127.
163. Brandsaeter B, Friman S, Broome U, Isoniemi H, Olausson M, Backman L, et al. Outcome following liver transplantation for primary sclerosing cholangitis in the Nordic countries. *Scand J Gastroenterol* 2003;38:1176-1183.
164. Welsh FK, Wigmore SJ. Roux-en-Y Choledochojejunostomy is the method of choice for biliary reconstruction in liver transplantation for primary sclerosing cholangitis. *Transplantation* 2004;77:602-604.
165. Mathis KL, Dozois EJ, Larson DW, Cima RR, Sarmiento JM, Wolff BG, et al. Ileal pouch-anal anastomosis and liver transplantation for ulcerative colitis complicated by primary sclerosing cholangitis. *Br J Surg* 2008;95:882-886.
166. Florman S, Schiano T, Kim L, Maman D, Levay A, Gondolesi G, et al. The incidence and significance of late acute cellular rejection (>1000 days) after liver transplantation. *Clin Transplant* 2004;18:152-155.
167. Campsen J, Zimmerman MA, Trotter JF, Wachs M, Bak T, Steinberg T, et al. Clinically recurrent primary sclerosing cholangitis following liver transplantation: a time course. *Liver Transpl* 2008;14:181-185.

168. Alabraba E, Nightingale P, Gunson B, Hubscher S, Olliff S, Mirza D, et al. A re-evaluation of the risk factors for the recurrence of primary sclerosing cholangitis in liver allografts. *Liver Transpl* 2009;15:330-340.
169. Wojcicki M, Milkiewicz P, Silva M. Biliary tract complications after liver transplantation: a review. *Dig Surg* 2008;25:245-257.
170. Alexander J, Lord JD, Yeh MM, Cuevas C, Bakthavatsalam R, Kowdley KV. Risk factors for recurrence of primary sclerosing cholangitis after liver transplantation. *Liver Transpl* 2008;14:245-251.
171. Cholongitas E, Shusang V, Papatheodoridis GV, Marelli L, Manousou P, Rolando N, et al. Risk factors for recurrence of primary sclerosing cholangitis after liver transplantation. *Liver Transpl* 2008;14:138-143.
172. Rowe IA, Webb K, Gunson BK, Mehta N, Haque S, Neuberger J. The impact of disease recurrence on graft survival following liver transplantation: a single centre experience. *Transpl Int* 2008;21:459-465.
173. Guichelaar MM, Kendall R, Malinchoc M, Hay JE. Bone mineral density before and after OLT: long-term follow-up and predictive factors. *Liver Transpl* 2006;12:1390-1402.
174. Dvorchik I, Subotin M, Demetris AJ, Fung JJ, Starzl TE, Wieand S, et al. Effect of liver transplantation on inflammatory bowel disease in patients with primary sclerosing cholangitis. *HEPATOLOGY* 2002;35:380-384.
175. Vera A, Gunson BK, Ussatoff V, Nightingale P, Candinas D, Radley S, et al. Colorectal cancer in patients with inflammatory bowel disease after liver transplantation for primary sclerosing cholangitis. *Transplantation* 2003;75:1983-1988.
176. Loftus EV Jr, Aguilar HI, Sandborn WJ, Tremaine WJ, Krom RA, Zinsmeister AR, et al. Risk of colorectal neoplasia in patients with primary sclerosing cholangitis and ulcerative colitis following orthotopic liver transplantation. *HEPATOLOGY* 1998;27:685-690.
177. Gossard AA, Lindor KD. Pregnancy in a patient with primary sclerosing cholangitis. *J Clin Gastroenterol* 2002;35:353-355.
178. Janczewska I, Olsson R, Hultcrantz R, Broome U. Pregnancy in patients with primary sclerosing cholangitis. *Liver* 1996;16:326-330.
179. Riis L, Vind I, Politi P, Wolters F, Vermeire S, Tsianos E, et al. Does pregnancy change the disease course? A study in a European cohort of patients with inflammatory bowel disease. *Am J Gastroenterol* 2006;101:1539-1545.
180. Kondrackiene J, Kupcinskas L. Intrahepatic cholestasis of pregnancy-current achievements and unsolved problems. *World J Gastroenterol* 2008;14:5781-5788.
181. Card TR, Solaymani-Dodaran M, West J. Incidence and mortality of primary sclerosing cholangitis in the UK: a population-based cohort study. *J Hepatol* 2008;48:939-944.
182. United Network for Organ Sharing. UNOS Data Report. <http://www.unos.org/data/>. Accessed October 2009.
183. Feldstein AE, Perrault J, El-Youssif M, Lindor KD, Freese DK, Angulo P. Primary sclerosing cholangitis in children: a long-term follow-up study. *HEPATOLOGY* 2003;38:210-217.
184. Miloh T, Arnon R, Shneider B, Suchy F, Kerkar N. A retrospective single-center review of primary sclerosing cholangitis in children. *Clin Gastroenterol Hepatol* 2009;7:239-245.
185. Jacquemin E, De Vree JM, Creteil D, Sokal EM, Sturm E, Dumont M, et al. The wide spectrum of multidrug resistance 3 deficiency: from neonatal cholestasis to cirrhosis of adulthood. *Gastroenterology* 2001;120:1448-1458.
186. Ziol M, Barbu V, Rosmorduc O, Frassati-Biaggi A, Barget N, Hermelin B, et al. ABCB4 heterozygous gene mutations associated with fibrosing cholestatic liver disease in adults. *Gastroenterology* 2008;135:131-141.
187. Bjornsson E, Angulo P. Cholangiocarcinoma in young individuals with and without primary sclerosing cholangitis. *Am J Gastroenterol* 2007;102:1677-1682.
188. Ebbeson RL, Schreiber RA. Diagnosing autoimmune hepatitis in children: is the International Autoimmune Hepatitis Group scoring system useful? *Clin Gastroenterol Hepatol* 2004;2:935-940.
189. Floreani A, Zancan L, Melis A, Baragiotta A, Chiaramonte M. Primary sclerosing cholangitis (PSC): clinical, laboratory and survival analysis in children and adults. *Liver* 1999;19:228-233.
190. Chavhan GB, Roberts E, Moineddin R, Babyn PS, Manson DE. Primary sclerosing cholangitis in children: utility of magnetic resonance cholangiopancreatography. *Pediatr Radiol* 2008;38:868-873.
191. Batres LA, Russo P, Mathews M, Piccoli DA, Chuang E, Ruchelli E. Primary sclerosing cholangitis in children: a histologic follow-up study. *Pediatr Dev Pathol* 2005;8:568-576.
192. Yerushalmi B, Sokol RJ, Narkewicz MR, Smith D, Karrer FM. Use of rifampin for severe pruritus in children with chronic cholestasis. *J Pediatr Gastroenterol Nutr* 1999;29:442-447.
193. Cies JJ, Giamalis JN. Treatment of cholestatic pruritus in children. *Am J Health Syst Pharm* 2007;64:1157-1162.
194. Shneider B, Emre S, Groszmann R, Karani J, McKiernan P, Sarin S, et al. Expert pediatric opinion on the Report of the Baveno IV consensus workshop on methodology of diagnosis and therapy in portal hypertension. *Pediatr Transplant* 2006;10:893-907.
195. Bachrach LK, Ward LM. Clinical review: bisphosphonate use in childhood osteoporosis. *J Clin Endocrinol Metab* 2009;94:400-409.
196. LaRusso NF, Shneider BL, Black D, Gores GJ, James SP, Doo E, et al. Primary sclerosing cholangitis: summary of a workshop. *HEPATOLOGY* 2006;44:746-764.