

AASLD PRACTICE GUIDELINE

Evaluation of the Pediatric Patient for Liver Transplantation: 2014 Practice Guideline by the American Association for the Study of Liver Diseases, American Society of Transplantation and the North American Society for Pediatric Gastroenterology, Hepatology and Nutrition

Robert H. Squires,¹ Vicky Ng,² Rene Romero,³ Udeme Ekong,⁴ Winita Hardikar,⁵ Sukru Emre,⁶ and George V. Mazariegos⁷

This practice guideline has been approved by the American Association for the Study of Liver Diseases, the American Society of Transplantation and the North American Society for Pediatric Gastroenterology, Hepatology and Nutrition.

Abbreviations: ALF, acute liver failure; GRADE, Grading of Recommendation Assessment, Development, and Evaluation; HB, hepatoblastoma; HCC, hepatocellular carcinoma; HPE, hepatoportoenterostomy; LT, liver transplantation; OTPN, Organ Procurement and Transplantation Network; PFIC, progressive familial intrahepatic cholestasis; TIPS, transjugular intrahepatic portosystemic shunt.

From the ¹Department of Pediatrics, University of Pittsburgh School of Medicine; Division of Pediatric Gastroenterology, Hepatology and Nutrition, Children's Hospital of Pittsburgh of UPMC, Pittsburgh, PA; ²Department of Pediatrics, University of Toronto; Division of Pediatric Gastroenterology, Hepatology and Nutrition, SickKids Transplant and Regenerative Medicine Center, Hospital for Sick Children, Toronto, Canada; ³Department of Pediatrics, Division of Pediatric Gastroenterology, Hepatology, and Nutrition, Emory University School of Medicine; Children's Healthcare of Atlanta, Atlanta, GA; ⁴Department of Pediatrics, Division of Pediatric Gastroenterology and Hepatology, Yale School of Medicine, New Haven, CT; ⁵Department of Paediatrics, University of Melbourne; Department of Gastroenterology, Royal Children's Hospital, Melbourne, Australia; ⁶Department of Surgery, Section of Transplantation and Immunology, Yale School of Medicine, New Haven, CT; ⁷Department of Surgery, University of Pittsburgh School of Medicine; Division of Pediatric Transplantation, Hillman Center for Pediatric Transplantation, Children's Hospital of Pittsburgh of UPMC, Pittsburgh, PA.

Financial support to develop this practice guideline was provided by the American Association for the Study of Liver Diseases.

All AASLD Practice Guidelines are updated annually. If you are viewing a Practice Guideline that is more than 12 months old, please visit www.aasld.org for an update in the material.

Received April 22, 2014; accepted April 22, 2014.

Address reprint requests to: Robert H. Squires, M.D., Professor of Pediatrics, University of Pittsburgh, Children's Hospital of Pittsburgh of UPMC, 4401 Penn Ave., Pittsburgh, PA 15224. E-mail: squiresr@upmc.edu

Copyright © 2014 by the American Association for the Study of Liver Diseases.

View this article online at wileyonlinelibrary.com.

DOI 10.1002/hep.27191

Potential conflict of interest: Dr. Romero received grants from Bristol-Myers Squibb.

Preamble

Current American Association for the Study of Liver Diseases (AASLD) liver transplant evaluation guidelines include both adult and pediatric patients.¹ While pediatric liver transplants account for ~7.8% of all liver transplants in the United States, sufficient differences between pediatric and adult patients seeking liver transplantation (LT) now require independent, yet complementary documents. This document will focus on pediatric issues at each level of the evaluation process. Disease categories suitable for referral to a pediatric LT program are similar to adults: acute liver failure, autoimmune, cholestasis, metabolic or genetic, oncologic, vascular, and infectious. However, specific etiologies and outcomes differ widely from adult patients, justifying independent pediatric guidelines. Data supporting our recommendations are based on a Medline search of the English language literature from 1997 to the present.

Intended for use by physicians, these recommendations suggest preferred approaches to the diagnostic, therapeutic, and preventive aspects of care. They are intended to be flexible, in contrast to standards of care, which are inflexible policies to be followed in every case. Specific recommendations are based on relevant published information.

To more fully characterize the available evidence supporting the recommendations, the AASLD Practice Guidelines Committee has adopted the classification used by the Grading of Recommendation Assessment, Development, and Evaluation (GRADE) workgroup with minor modifications (Table 1). The classifications and recommendations are based on three categories: the source of evidence in levels I through III; the

Table 1. Grading of Recommendations, Assessment, Development and Evaluation (GRADE)

Criteria	
Strength of Recommendation	
Strong [1]	Factors influencing the strength of the recommendation included the quality of the evidence, presumed patient-important outcomes, and cost
Weak [2]	Variability in preferences and values, or more uncertainty. Recommendation is made with less certainty, higher cost or resource consumption
Quality of Evidence	
High [A]	Further research is unlikely to change confidence in the estimate of the clinical effect
Moderate [B]	Further research may change confidence in the estimate of the clinical effect
Low [C]	Further research is very likely to impact confidence on the estimate of clinical effect

quality of evidence designated by high (A), moderate (B), or low quality (C); and the strength of recommendations classified as strong or weak.

Literature Review Methods and Analysis

Each Association appointed at least one author to serve on the writing group. The Chair of the writing group was appointed by the AASLD. Members of the writing group were not compensated for their work and served as volunteers throughout the process from concept design through final publication. Writing group members had no financial conflict of interest or financial relationship with commercial entities relevant to the article. Topics relevant to liver transplant evaluation in the pediatric patients were identified through a conference call with all members of the writing group on July 11, 2012 and assignments were distributed among the members based on their particular expertise and interest.

The literature databases and the search strategies are outlined below. The resulting literature database was available to all members of the writing group. They selected references within their field of expertise and experience and graded the references according to the GRADE system. Data supporting our recommendations are based on a MEDLINE search of the English language literature from 1973 to the present. Primary search terms included: liver transplant evaluation, liver transplant, child, pediatric, and liver transplant outcome. In addition, each assessment (e.g., anesthesia, hepatology, renal, etc.); diagnosis (e.g., biliary atresia, organic acidemia, maple syrup urine disease, ductal plate malformation, etc.) and complication (e.g., hepa-

topulmonary syndrome, malignancy, etc.) was searched in the context of the primary search terms as well as individually when relevant clinical background information was needed.

The selection of references for the guideline was based on a validation of the appropriateness of the study design for the stated purpose, a relevant number of patients under study, and confidence in the participating centers and authors. References on original data were preferred and those that were found unsatisfactory in any of these respects were excluded from further evaluation. There may be limitations in this approach when recommendations are needed on rare problems or problems on which scant original data are available. In such cases it may be necessary to rely on less qualified references with a low grading.

Pediatric Liver Transplant Evaluation Team

Children have distinct diseases, clinical susceptibilities, physiological responses, as well as neurocognitive and neurodevelopmental features that distinguish them from adults. In fact, even within the pediatric age group differences can be found between newborns, infants, children, and adolescents. Given the intra-abdominal anatomical variations associated with biliary atresia, the most common indication for pediatric LT, as well as the restricted abdominal cavity and small size of blood vessels in infants and young children, surgical teams with exhaustive pediatric experience will benefit the pediatric recipient of an LT. Members of the pediatric LT team (Table 2) use their expertise to tailor the LT evaluation plan (Table 3) to the unique needs of the child. The end product of the evaluation will ensure the elements for an informed decision to proceed to LT are met.²

Recommendation:

1. A multidisciplinary pediatric LT evaluation team should be skilled in pediatric conditions and properly communicate with the family and the child, when appropriate, the processes, risks, and benefits associated with LT. (2-B)

Timing of Referral for Pediatric Liver Transplant Evaluation

Based on the United States Organ Procurement and Transplantation Network (OTPN) from January 1, 2011, through May 31, 2013, indications for LT include biliary atresia (32%), metabolic/genetic conditions (22%), acute liver failure (11%), cirrhosis (9%), liver tumor (9%), immune-mediated liver and biliary

Table 2. Potential Members of the Pediatric Liver Transplant Team

General	
• Transplant surgeon	
• Hepatologist/gastroenterologist with expertise in pediatric liver disease	
• Infectious disease specialist	
• Critical care specialist	
• Social worker	
• Psychologist/neuropsychologist/child development specialist	
• Dietician	
• Physical/occupational therapist	
• Pharmacist	
• Psychiatrist	
• Transplant coordinator	
• Anesthesiologist	
• Patient educator	
Selected patients	
• Cardiologist	
• Nephrologist	
• Neurologist	
• Genetic/metabolic specialist	
• Pulmonologist	
• Radiologist, diagnostic	
• Radiologist, interventional	
• Ethics specialist	
• Child life specialist	
• Pastoral care	

injury (4%), and other miscellaneous conditions (13%) (Fig. 1). Within these broad categories rest many rare conditions with myriad presentations.

As timing for referral varies depending on the child's clinical circumstances, referral for LT may be emergent, urgent, or anticipatory. Acute liver failure (ALF) or an acute decompensation of an established liver disease may have a rapid and unpredictable course progressing to death or irreversible neurological damage.³ Children

Table 3. Components of the Pediatric Liver Transplantation Evaluation

Secure all prior records to identify relevant diagnostic, management and clinical information
Establish appropriate indications for referral
Construct a patient and disease specific appointment itinerary
Confirm or affirm the diagnosis, associated systemic manifestations, and management plan
Assess disease severity and urgency for liver transplantation
Identify opportunities to maximize current medical therapy
Determine if non-transplant surgical options are available
Identify contraindications for liver transplantation
Consider appropriateness of a live donor option
Confirm immunization status; if incomplete, establish a strategy to complete immunizations
Establish a trusting relationship among the child, family and transplant team
Ensure finances are available
Anticipate potential complications following transplant
Develop a management and communication plan with the local managing physician
Clarify logistics when a potential donor liver is available

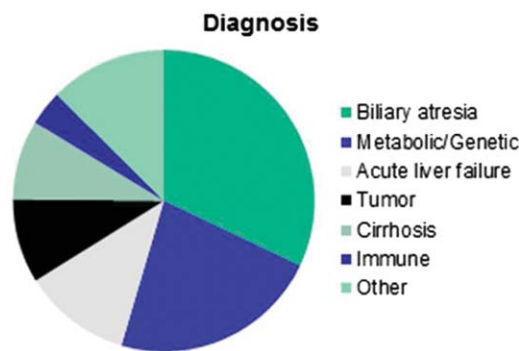


Fig. 1. Indications for pediatric liver transplant.

with metabolic liver disease, such as urea cycle defects or maple syrup urine disease, can suffer significant neurological sequelae as a consequence of metabolic crises.⁴ Primary and secondary liver tumors are rare in children, with hepatoblastoma (HB) and hepatocellular carcinoma (HCC) being the most common. Survival for children with HB is dependent on response to initial chemotherapy and complete surgical resection.⁵ Screening for HCC is imperfect, but an elevated or rising alpha-fetoprotein identifies a heightened risk for HCC.⁶ Only 16% of children with biliary atresia survive to 2 years with their native liver if the total serum bilirubin measured 3 months following hepatoporoenterostomy (Kasai Procedure) is over 6 mg/dL, compared to 84% for those with a total bilirubin less than 2 mg/dL.⁷ For some children with Alagille syndrome and progressive familial intrahepatic cholestasis (PFIC) types 1, 2, and 3, pruritus and/or deforming xanthomas can severely impact the child's quality of life despite relatively preserved liver function.⁸ Sequelae associated with endstage liver disease place children at risk for life-threatening events.

Recommendations:

2. Immediate contact with a pediatric LT center should be initiated for children with acute liver failure or acute decompensation of an established liver disease; emergent referral for LT evaluation may be required. (1-A)

3. Children with liver-based metabolic crises refractory to medical and/or surgical therapy (1-B), unresectable hepatoblastoma (1-B), or evidence of hepatocellular unresectable carcinoma (1-B) should be referred urgently for LT evaluation.

4. Biliary atresia (BA) patients who are post-hepatoporoenterostomy (HPE) should be promptly referred for LT evaluation if the total bilirubin is greater than 6 mg/dL beyond 3 months from HPE

(1-B); liver transplant evaluation should be considered in BA patients whose total bilirubin remains between 2-6 mg/dL. (1-B)

5. Referral for LT evaluation should be anticipated for children with chronic liver disease and evidence of deteriorating liver function characterized by poor weight gain, growth failure, variceal hemorrhage, intractable ascites, recurrent cholangitis, or episodes of spontaneous bacterial peritonitis, pruritus, advancing encephalopathy, and/or uncorrectable coagulopathy. (1-B)

Liver Transplant Evaluation

Affirm Diagnosis and Management

The child's diagnostic evaluation as it relates to their primary disease, associated comorbidities, subspecialty consultations, and management strategies should be documented and provided by the primary pediatric specialist responsible for management of the child's liver disease. These documents should include clinical assessments, results of laboratory and diagnostic studies, medical and nutritional management, surgical procedures, pathology reports and slides, as well as radiographic reports and copies of the radiographs. Personal communication between a member of the LT evaluation team and the child's physician will identify clinical, social, and psychological factors that may not be apparent in the medical record. New or worsening comorbidities may be identified during the LT evaluation.⁹

Recommendations:

6. A review of the local records by the LT team prior to the LT evaluation will inform the evaluation schedule and enable affirmation of the primary diagnosis, assessment of comorbidities, and identify technical challenges related to LT. (2-B)

7. In collaboration with the local primary pediatric specialist, management of the primary disease and comorbidities should be reviewed and optimized. (2-B)

Hepatology Assessment

Complications associated with endstage liver disease include ascites, pruritus, portal hypertension, malnutrition, vitamin deficiencies, and delayed growth and development.¹⁰ In cirrhosis patients, accumulation of ascites is a result of portal hypertension, vasodilatation, and hyperaldosteronism.¹¹ Hypoalbuminemia is an additional risk factor for ascites. Ultrasonography is sensitive enough to detect as little as an ounce of intra-abdominal fluid, while significantly more is required

for it to be detected on physical examination. Decisions to initiate diuretic therapy to manage ascites are ill-defined. Abdominal distension alone does not reliably predict ascites, as organomegaly and vascular congestion of the bowel may also contribute to distension. Fluid that is easily palpated between the abdominal wall and the surface of the liver ("ballotable fluid") would suggest sufficient ascites to warrant therapy; its presence can be used to judge response to therapy. Initial treatment includes spironolactone and a "no-added" salt diet. Loop-diuretics should be used with caution as overaggressive diuresis can precipitate hepatorenal syndrome. For hospitalized patients with significant ascites, intravenous albumin, with or without an accompanying diuretic, can improve diuresis and response to diuretics.¹² Tense ascites can compromise respiratory function and renal perfusion, heighten the risk for infection, and contribute to a poor quality of life.¹³ Large-volume paracentesis¹⁴ and transjugular intrahepatic portosystemic shunt (TIPS)¹⁵ are effective if ascites is compromising the child's respiratory effort and is not responsive to medical therapy. Rapid accumulation of ascites should raise concern for obstruction of the portal or hepatic vein or bacterial peritonitis.

Evaluation and management of esophageal varices in children varies widely among practitioners.^{16,17} In the absence of data supporting primary prophylactic therapy for esophageal varices in children, screening endoscopy for esophageal varices has not been recommended.¹⁸ Inflammatory bowel disease (IBD), particularly ulcerative colitis, is a notable comorbidity of children with primary sclerosing cholangitis (PSC). Following LT, some patients with autoimmune hepatitis and bile salt excretory pump disease are at risk for recurrence of their primary liver disease^{19,20}; those with PSC may also be at increased risk for colon cancer.^{21,22}

Recommendations:

8. Clinically detectable ascites can be managed initially with an aldosterone antagonist (2-B); more aggressive removal of ascitic fluid using paracentesis or transjugular intrahepatic portosystemic shunt or surgical shunt should be reserved for ascites that compromises respiratory effort or severely affects quality of life. (2-B)

9. Patients with conditions such as autoimmune hepatitis, PSC, and bile salt excretory pump disease should be informed that liver disease can recur post-LT. (2-B)

10. Patients at risk for extrahepatic complications such as IBD should be informed of the need for

scheduled monitoring for evidence of IBD, including colonoscopy, for colon cancer surveillance. (2-B)

Nutrition Assessment

Children with chronic liver disease are at risk for malnutrition as they require 20%-80% more calories than normal children to achieve adequate growth.²³⁻²⁵ Increased caloric requirements result from a hypermetabolic state coupled with malabsorption. Aggressive nutritional support prior to LT improves patient and graft survival as well as neurodevelopmental outcome.^{26,27} Serial triceps skin fold and mid-arm circumference are the most reliable anthropometric assessments to judge nutritional status, as reliance on weight alone may overestimate nutritional adequacy in children with chronic liver disease.^{24,25,28} Fat soluble vitamin (FSV) deficiency is common and dosing and monitoring recommendations to prevent FSV deficiency are available.^{24,25,29,30} Enteral formulas that contain medium chain triglycerides (MCT) are preferred in cholestatic patients, but excessive administration of MCT can lead to essential fatty acid deficiency.³¹ Protein intake should not be restricted in the absence of hyperammonemia.³² When oral intake is not sufficient, initiation of nasogastric (NG) tube feeding improves body composition in children with chronic liver disease.³³ Parenteral nutrition may help reverse poor weight gain and growth in malnourished children with BA.³⁴

Less than 15% of children receiving a liver transplant are obese.³⁵ Patients with body mass index (BMI) z-scores ≥ 3 have similar short-term survival as normal-weight counterparts, but had increased late (>12 years) mortality and are more likely to experience posttransplant obesity.³⁶ Metabolic syndrome occurs frequently in obese adult liver transplant recipients, but the rate in obese pediatric recipients is not known.^{37,38}

Recommendations:

11. Complete nutritional assessment should include serial triceps skin fold thickness and mid-arm circumference measurements (2-B); identification of nutritional goals to maximize health; fat soluble vitamin supplementation and monitoring (2-B); and in cholestatic infants, use of medium-chain triglyceride-containing formulas with normal protein administration (2-4 g/kg/day). (2-B)

12. Aggressive nutritional support for children awaiting LT should be initiated to optimize outcomes (1-B); NG tube feedings and parenteral nutrition may be needed in some circumstances. (2-B)

Cardiopulmonary Assessment

Structural cardiac disease can be seen in children with BA and Alagille syndrome.³⁹ Cirrhotic cardiomyopathy (CC), characterized by increased cardiac output, impaired diastolic relaxation, myocardial hypertrophy, and repolarization abnormalities, carries a high risk of post-LT mortality in adults. Evidence of cardiomyopathy, as determined by two-dimensional echocardiography (2-DE), can also be found in children with cirrhosis as well as those with cardiomyopathy associated with glycogen storage disease or systemic mitochondrial disease. In one study, 70% of children with BA had evidence of CC.⁴⁰ While those with CC experienced a longer ICU and hospital stay, there were no differences in the 2-DE between those who died awaiting LT versus those who survived to LT.

Hepatopulmonary syndrome (HPS) and portopulmonary hypertension (PPHN), both described in more detail below, are potentially life-threatening conditions that develop as a consequence of portosystemic shunting regardless of the severity of the liver disease.^{41,42} Nonspecific clinical findings include digital clubbing, facial telangiectasia, dyspnea, wheezing, and syncope. Screening for HPS is performed by pulse oximetry detection of oxygen desaturation when in the sitting or standing position; pulse oximetry less than 97% on room air should be considered for further evaluation.⁴³ HPS is confirmed with 2-DE during infusion of agitated saline with the appearance of saline bubbles in the left atrium within 3-6 cardiac cycles. A ^{99m}Techneium-macroaggregated albumin (MAA) perfusion lung scan can be used to quantify and follow the degree of intrapulmonary shunting; an MAA shunt fraction of 27.8% was highly specific for intrapulmonary shunting associated with hypoxia.^{44,45} Unlike HPS, screening procedures for PPHN are imperfect. While the chest radiograph and electrocardiogram may reveal a prominent pulmonary artery and right ventricular hypertrophy, but both may be normal.⁴⁶ In addition, 2-DE with Doppler may show elevations in right ventricular systolic pressures which should be confirmed by cardiac catheterization to exclude other causes of pulmonary hypertension such as increased central volume and high cardiac output due to a hyperdynamic cardiac physiology.⁴⁷

Patients with cystic fibrosis (CF) referred for LT present a unique challenge. In addition to being at risk for development of HPS and PPHN, the severity of CF-related lung disease can impact outcome. The forced expiratory volume in one second (FEV1) and forced vital capacity (FVC) have been used in a model

to predict survival.⁴⁸ FEV1 was found to be lower in CF patients with liver disease who subsequently receive LT than those who do not undergo LT and is used to monitor improvement following LT.⁴⁹

Recommendations:

13. Screening transcutaneous oxygen saturation with the patient in the upright position should be performed in all patients with possible portosystemic shunting. (2-B)

14. Two-dimensional echocardiography (2-DE) with Doppler should be performed in all patients at the time of liver transplant evaluation (2-B); if the right ventricular systolic pressure is over 50 mmHg by 2-DE, a right-heart cardiac catheterization is necessary to establish the diagnosis of portopulmonary hypertension. (2-B)

15. Pulmonary function tests, including forced expiratory volume in one second and forced vital capacity should be performed in patients with cystic fibrosis evaluated for liver transplant. (2-B)

Renal Assessment

Glomerular filtration rate (GFR) is the most practical measure of kidney function.⁵⁰ Direct measurement of GFR using an exogenous filtration marker, such as iohexol plasma clearance, is impractical in the routine clinical setting.⁵¹ Endogenous filtration markers, such as creatinine clearance, are hampered by the imperfections of timed urinary collections. Static measurements of naturally filtered molecules, such as creatinine, are affected by muscle mass, age, and gender as well as renal tubular absorption and secretion. At best, only an estimate of the GFR can be achieved.

Serum creatinine, while imperfect, is most often used to screen individuals for evidence of renal insufficiency, but cannot be used to estimate GFR independently. The recently revised Schwartz Formula utilizes the serum creatinine (sCr), patient height, and a “constant” to derive an estimated creatinine clearance (eCCL) and is easily used at the bedside.⁵¹ The formula is $0.413 \times [\text{sCr (mg/dL)} / \text{height (cm)}] = \text{GFR (mL/min/1.73 m}^2\text{)}$. Cystatin C is a low molecular weight protein that is almost completely filtered by the glomerulus, is not excreted or absorbed by the renal tubules, and is not affected by muscle mass, age, or gender.⁵² Normal values for cystatin C are high in infants but approach normal adult levels (0.51-0.98 mg/L) by 1 year of age.⁵³ A cystatin C level of 1.06 mg/L predicted a GFR <80 mL/min/1.73 m² with a sensitivity and specificity of 91% and 81%, respectively, in a pediatric cohort of 62 children with a

median age of 3.1 years (range 0.6-18.7 years) that included both pre- and post-LT patients.⁵² For children with acute renal injury, the pediatric modified RIFLE (Risk for renal dysfunction, Injury to the kidney, Failure of the kidney, Loss of kidney function, and Endstage renal disease) criteria utilizes a combination of the eCCL by the Schwartz method and urine output to inform the severity of renal injury.⁵⁴

Renal insufficiency that would necessitate combined liver and kidney transplant (CLKT) is less common in children than adults.⁵⁵ Renal dysfunction among children with chronic liver disease can be quite variable. For example, children with biliary atresia tend to have good renal function prior to and following liver transplant,^{56,57} while those with tyrosinemia may have a glomerular filtration rate of less than 55 mL/min/1.73 m².⁵⁸ Significant renal disease can be associated with primary hyperoxaluria, congenital hepatic fibrosis, and methylmalonic acidemia. Renal dysfunction prior to LT can be exacerbated following LT, particularly in children with inborn errors of metabolism, alpha-1-antitrypsin deficiency (A1ATD), and Alagille syndrome (AGS).⁵⁹⁻⁶² Increased susceptibility to renal toxicity caused by calcineurin inhibitors may be attributed to associated genetic polymorphisms in the ABCB1 gene.⁶³

Recommendations:

16. Renal function should be assessed in all patients, with special emphasis on those with metabolic liver diseases associated with renal dysfunction (1-B) and those at increased risk for calcineurin inhibitor toxicity. (2-B)

17. Serum creatinine alone should not be used to assess renal function (1-B); either cystatin C (2-B) or the revised Schwartz Formula (2-C) should be used to estimate the glomerular filtration rate in children with chronic liver disease.

18. The modified Risk for Renal Dysfunction, Injury, Failure, Loss, and Endstage renal disease could be used to assess the degree of acute renal injury. (2-B)

Dental Assessment

Dental caries due to frequent and prolonged bottle-feeding occur in children with endstage liver disease.^{64,65} A survey of transplant centers in the United States noted that a dental infection prior to transplantation resulted in cancellation or postponement of LT (38% of responding sites) and post-LT sepsis from a suspected dental source (27% of sites).⁶⁶ Preventive oral health care strategies are important in this patient population.^{66,67}

Recommendation:

19. Children with endstage liver disease should receive a careful oral examination looking for evidence of dental caries, gingival disease, or dental abscess; referral to a pediatric dentist should occur if abnormalities are identified. (2-B)

Anesthesiology Assessment

General anesthesiology assessment should include determination of venous access, review of cardiovascular, respiratory, gastrointestinal, renal, central nervous system, hepatic, and hematological systems.⁶⁸ Pathophysiological changes associated with these systems will impact method of induction, intraoperative fluid management, drug dosing, and ventilatory requirements.^{68,69} Risk factors that require careful assessment include patient age and weight, nutritional status, hypoalbuminemia, hepatopulmonary syndrome, and cardiomyopathy associated with cirrhosis.^{69,70} Pediatric conditions and their associated comorbidities that may heighten anesthetic risk include Alagille syndrome (cardiac disease, vascular and renal abnormalities, and moyamoya), biliary atresia with splenic malformation (complex heart disease, interrupted inferior vena cava), and primary hyperoxaluria (renal and cardiac dysfunction).⁶⁹ A specialized LT anesthesia team has been associated with more favorable patient outcomes in adults, although pediatric centers were excluded from this study.⁷¹ The United Network for Organ Sharing (UNOS) has recently modified policy to require liver transplant programs to designate a Director of Liver Transplant Anesthesia who has expertise in the area of perioperative care of liver transplant patients and can serve as an advisor to other members of the team.

Recommendation:

20. An anesthesiologist familiar with pediatric indications for LT and associated comorbidities should ensure the LT evaluation includes appropriate disease-specific assessments to minimize intraoperative and postoperative anesthetic risk. (2-B)

Immunization Status and Assessment of Viral Susceptibilities

Children with chronic liver disease are often not fully immunized prior to LT.^{72,73} Development of a vaccine preventable disease (VPD) either before or after LT will increase morbidity and mortality and heightened the risk of graft injury or loss.^{74,75} Timing of immunization administration in the LT candidate is important, as vaccines are more immunogenic before the development of endstage liver disease and more

immunogenic before than after LT. Humoral immunity to rubella, measles, and varicella vaccines is significantly decreased in children with biliary atresia compared to healthy controls.⁷⁶ VPD can develop in immunized children with chronic liver disease when antibody titers are low.⁷⁷ There is a paucity of data related to influenza vaccine in patients with chronic liver disease.⁷⁸ Hepatic decompensation has been reported with influenza,⁷⁹ and influenza vaccination in adults with cirrhosis significantly reduced the frequency of hepatic decompensation compared to those who did not receive the vaccine.⁸⁰ Guidelines for vaccination of liver transplant candidates and recipients are published periodically by the American Society of Transplantation.⁸¹ Clinical practice guidelines for vaccination of the immunocompromised host were recently published by the Infectious Diseases Society of America.⁸²

Vaccination of household contacts provides additional protection to the child.⁸³ Paralytic polio has been described in household contacts of oral polio vaccine recipients.⁸⁴ Data suggest that administration of live virus vaccines to household contacts, other than oral polio, poses minimal risk to the child.⁸³

Both Epstein-Barr virus (EBV)-associated lymphoproliferative disease and disseminated cytomegalovirus (CMV) are associated with significant morbidity and mortality in children receiving LT. Children are at highest risk for these conditions if they are immunologically naive to EBV and CMV and receive a liver from a serologically positive donor.^{85,86} LT candidates serologically positive for CMV remain at risk for developing post-LT CMV.⁸⁷ Preventive strategies to reduce EBV and CMV disease post-LT include assessment of EBV and CMV status in the recipient and have significantly improved LT outcomes.^{86,87}

Recommendations:

21. Completion of all age-appropriate vaccinations, for the child and family members, should occur prior to transplantation and ideally before the development of endstage liver disease (1-B); children who have not completed the necessary vaccine schedule can receive vaccinations on an accelerated schedule. (1-B)

22. Seasonal inactivated influenza vaccination should be given for listed patients older than 6 months and their family members, and to family members of infants less than 6 months. (1-A)

23. Family members of children evaluated for LT should be fully immunized using both live and attenuated virus vaccines (1-B); the oral polio vaccine should never be used. (1-A)

24. Evidence of a prior Epstein-Barr virus and cytomegalovirus infection, as determined by virus-specific serological measurements, should be performed on all individuals evaluated for liver transplant, recognizing that for children less than 12-18 months of age, antibodies may have been passively transmitted to the child from the mother. (1-A)

Psychosocial Assessment

Successful LT requires lifelong care and presents unique challenges to families dealing with a child with a serious illness.⁸⁸ Feelings of guilt, inadequacy, stress, lack of control, uncertainty, anger, and fear by the primary caregiver can have a negative impact on disease management and family structure unless they are identified and addressed. Lack of parental understanding of the child's condition, of housing, and transportation are deleterious to the management of chronic conditions. Engagement of child protective services may be necessary if the principal impediment to successful disease management is the child's social situation.^{89,90}

Psychosocial factors impact posttransplant outcomes, specifically factors related to treatment adherence.⁹¹⁻⁹³ Risk factors for nonadherence include a history of resistance to taking medications, substance abuse, physical or sexual abuse, school absenteeism, single parent home, and having received public assistance. Psychiatric assessment tools designed for pediatric LT candidates can identify risk factors such as parental psychopathology, substance abuse by the parent/guardian or patient, chaotic family environment, family perceptions, and lack of financial resources suggesting high-risk candidates who would benefit from targeted early intervention, including barriers to adherence.⁹³⁻⁹⁶

Recommendations:

25. Families should be assessed to ensure social services and psychosocial support systems are adequate for LT-candidates in order to optimize posttransplantation outcomes. (1-B)

26. Patients and families at potential risk for nonadherence should be identified and receive focused psychosocial interventions prior to and following transplantation. (1-B)

27. Members of the transplant team, in conjunction with the child's primary care provider, may need to serve as the child's advocate in situations where support systems are inadequate to the degree that the child's transplant candidacy in impaired or a high risk of noncompliance is identified. (1-B)

Neurocognitive and Neurodevelopmental Assessment

Cognitive measures have revealed reduced global cognitive functioning in children following LT,⁹⁷⁻⁹⁹ and specific weaknesses in motor skills and receptive language development following LT.^{100,101} Poorer nutritional status early in life, reduced head circumference, poor weight gain and growth, and low vitamin E levels correlate with poor cognitive functioning before and after transplantation.^{98,102,103} The association of serum bilirubin at transplantation was reported to correlate with adverse neurocognitive outcomes after LT remains controversial.^{100,103}

Children with biliary atresia demonstrate weaknesses in gross motor and expressive language development, with females being more vulnerable. Fine motor, visual problem solving, and receptive language development fell within the average range for age.¹⁰⁴ Age at Kasai correlated inversely with receptive language performance.¹⁰⁵

The presence of a severe intellectual or developmental disability has raised concerns of candidacy for LT. Those concerns center upon compliance with a rigorous and lifelong posttransplant management schedule, potential for increased risk for malignant or infectious complications related to genetic or physical disabilities, and assessment of quality of life. Unfortunately, data to address these concerns are very limited. Results of a survey received from 50 of 88 pediatric solid organ transplant programs suggests a wide variation among centers regarding the importance of neurodevelopmental delay in the decision to list for organ transplantation.¹⁰⁶ Successful renal transplantation with good graft function over a mean observation period of 41 months was possible in a highly selected cohort of 25 multiply handicapped pediatric renal transplant candidates.¹⁰⁷

Recommendations:

28. Neurocognitive testing should be performed in children awaiting LT to identify areas warranting early intervention to minimize later cognitive difficulties (2-B).

29. Aggressive nutritional management and early intervention should be initiated to minimize neurocognitive and developmental deficits (2-B).

Consideration for Living-Related and Living-Donor LT

The numbers of pediatric deaths awaiting LT were dramatically reduced with the introduction of living-related liver transplantation (LRLT).¹⁰⁸ As surgical

techniques for both the donor and recipient improved, the potential donor pool was extended to nonrelatives for living-donor liver transplantation (LDLT) including, in rare instances, anonymous living liver donation.¹⁰⁹⁻¹¹¹ An example of the potential advantage of LDLT over LRLT would be in recipients with genetic hepatopathies (e.g., Alagille syndrome) when the donor may be an asymptomatic relative and not a good candidate if they share common alleles.

To consider LDLT, LT must 1) be the only therapeutic option, or 2) deceased donor LT is not an option, or 3) a deceased donor organ has not become available. Furthermore, for the LDLT to be ethically appropriate, the likelihood the recipient will survive following LDLT should be high, the mortality risk to the donor low, and the donor is well informed of the risks to his/her short- and long-term health.¹⁰⁸ Considerable pressure is placed on the potential donor from both internal and external sources to save the life of a child or relative. These pressures should be addressed throughout the donor evaluation process to ensure the donor's "free will" to proceed with liver donation and have the ability to confidentially remove him or herself from consideration at any time.

Consideration of LDLT for a child with acute liver failure has raised concerns that the emergent clinical environment might be coercive to a potential donor and impede honest informed consent. While coercion is difficult to assess, postoperative evaluation of donors have found positive emotional and psychological outcomes regardless of the outcome for the patient.¹¹² Pediatric patients with acute liver failure who received LDLT had decreased wait times to LT, decreased cold ischemia time, and improved survival compared to a group who received a cadaveric donation.¹¹³

In addition to the standard evaluation requirements to assess general health status, surgical risks, volume of the segments to be removed, and evidence of a transmissible virus, the potential donor will require additional assessments that include psychological assessment and social support systems. If the potential recipient has an inherited metabolic disease, the feasibility of a parent wishing to serve as an LRLT donor should be determined in the context of the child's genetic condition.¹¹⁴ LRLT has been successfully performed using heterozygote donors for conditions such as Crigler-Najjar syndrome type 1,¹¹⁵ Wilson's disease,¹¹⁶ carbamoyl-phosphate synthase 1 deficiency,¹¹⁷ propionic acidemia,¹¹⁸ arginosuccinic aciduria,¹¹⁹ progressive familial intrahepatic cholestasis,¹²⁰ alpha-1 antitrypsin deficiency,¹²¹ tyrosinemia,¹²¹ Alagille syndrome,¹²² and others. In patients with Alagille syn-

drome receiving LRLT, poor recipient outcomes or technical failure due to bile ducts being too small to utilize are reported if the donor has bile duct hypoplasia.¹²² Children receiving an LRLT for arginosuccinic aciduria may still require arginine supplementation during periods of physiological stress or fasting due to persistent deficiency in extrahepatic tissues.¹¹⁹

Recommendations:

30. Living-related liver transplantation (LRLT) can be performed in many inherited genetic conditions (2-B); long-term follow-up is necessary to determine the full impact of LRLT for these rare conditions and to assess potential risk to the donor. (2-B)

31. A first-degree family member may be considered for living donation in Alagille syndrome, but donor evaluation must include careful assessment to rule out bile duct hypoplasia that may include liver biopsy and/or cholangiography (2-B); if the potential donor and recipient share the same mutant Jagged 1 or Notch 2 allele the donor should be carefully evaluated for bile duct hypoplasia and vascular anomalies, but LRLT is not advisable in most circumstances. (2-B)

Indications for Liver Transplantation

Biliary Atresia

Biliary atresia (BA) is universally fatal if untreated and is the single most common cause of liver disease leading to LT in children.^{123,124} Diagnosis of BA and performance of a hepatopertoenterostomy (HPE; Kasai Procedure) by 8 to 10 weeks of age is optimal for transplant-free survival beyond early childhood. Infants with BA with vitamin K nonresponsive coagulopathy, hypoalbuminemia, histologically advanced cirrhosis, ascites, portal hypertension, and poor nutritional status prior to HPE have poor outcomes.¹²⁵ Following HPE, up to 70% of BA patients may have prolonged transplant-free survival if the total serum bilirubin falls below 2 mg/dL within 3 months following the HPE.^{7,124,126} Children with biliary atresia splenic malformation (BASM) may have less favorable rates of transplant-free survival as reported in some studies,^{7,125,127-131} but not others.^{132,133}

Post-HPE complications include ongoing cholestasis, cholangitis, portal hypertension with or without variceal hemorrhage, poor weight gain, fat soluble vitamin deficiencies, hepatopulmonary syndrome, portopulmonary hypertension, and rarely hepatocellular carcinoma. Post-HPE regimens to promote bile flow (i.e.,

ursodeoxycholic acid) in BA patients are not standardized.^{124,126,134-136} Prophylactic antibiotic regimens with either trimethoprim/sufamethaxazole or neomycin reduce recurrent rates of cholangitis and improve survival.^{137,138} High-dose corticosteroid therapy initiated within 72 hours of HPE was not shown to improve bile drainage at 6 months, nor did it enhance transplant-free survival up to 2 years of age.¹³⁹ Aggressive nutritional support to ensure adequate growth and prevention of fat soluble vitamin deficiency can improve neurodevelopmental and transplant outcome.^{27,103,140,141} Management of portal hypertension remains poorly studied in children and use of beta-blocker therapy for primary prophylaxis of variceal hemorrhage is controversial in childhood.¹⁸ Variceal hemorrhage may be the sentinel event that prompts LT evaluation. Anecdotal cases of hepatocellular carcinoma (HCC) in BA patients have been reported, including patients less than 1 year of age, but the risk of HCC in BA is low.¹⁴²⁻¹⁴⁴

LT is recommended for BA patients' post-HPE with complications of chronic liver disease.⁷ Recurrent cholangitis with or without associated decompensation of liver function can be an indication for LT in BA.¹⁴⁵ At least 80% of patients with BA are transplanted by 20 years of age, with the majority transplanted under 4 years of age.^{7,126} Technical variant grafts (i.e., living related, split) are frequently utilized in smaller children with comparable results.¹⁴⁰ In the U.S., the overall 10-year actuarial graft and patient survival for liver transplant in BA is 73% and 86%, respectively.¹⁴⁶

Recommendations:

32. Hepatopertoenterostomy (HPE) is the preferred initial management for biliary atresia (1-B), but liver transplant evaluation should be considered in infants with evidence of decompensated liver disease prior to HPE. (2-B)

33. Aggressive nutritional support prior to LT is needed to improve outcomes in cholestatic children with BA. (1-B)

34. BA patients post-HPE should be promptly referred for LT evaluation if the total bilirubin is greater than 6 mg/dL beyond 3 months from HPE (1-B); liver transplant evaluation should be considered in BA patients whose total bilirubin remains between 2-6 mg/dL (1-B), and for those with lesser bilirubin values who have unmanageable consequences of biliary cirrhosis or portal hypertension. (2-B)

35. High-dose corticosteroid therapy initiated within 72 hours of HPE is not recommended. (1-B)

Alagille Syndrome

Alagille syndrome (AGS) is an autosomal dominant, multisystem disorder which may affect the liver, heart, eyes, and skeleton, kidneys, and cerebro-vascular or peripheral vascular systems with recognizable facial features including triangular facies, hypertelorism, prominent forehead, and pointed chin.¹⁴⁷⁻¹⁵⁰ Liver involvement ranges from minimal liver test abnormalities to biliary cirrhosis. Infants and children with AGS and significant cholestasis may experience well-compensated liver disease with absent or minimal evidence of clinical liver disease later in life.¹⁵¹

An estimated 20% to 30% of patients with AGS will require LT.¹⁵²⁻¹⁵⁵ Impaired synthetic function, uncontrolled portal hypertension, and chronic encephalopathy are uncommon in AGS. Complications of profound cholestasis, intractable pruritus, failure to thrive, severe hypercholesterolemia, and osteodystrophy have prompted consideration for LT.^{62,122,153,155-157} However, partial internal biliary diversion,¹⁵⁸ partial external biliary diversion,¹⁵⁹ and ileal exclusion¹⁶⁰ have improved pruritus, xanthoma burden, and quality of life in some patients. Hypercholesterolemia associated with AGS is predominantly due to elevations in lipoprotein X which may, in fact, protect against atherosclerosis.¹⁶¹ Reduced somatic growth parameters are recognized components of AGS. While cholestasis is resolved by LT, growth parameters may not be completely reversed by LT.

The potential for multisystem involvement seen in AGS adds to the complexity of LT decisions, including vascular anomalies, cerebral aneurysms, narrowing of the internal carotid artery, abdominal coarctation, and renal artery stenosis. There is no consensus on imaging the head and neck for vascular anomalies in the absence of symptoms, as surgical intervention is unlikely under those circumstances. However, repair of a coarctation of the abdominal aorta or renal artery stenosis should be considered prior to LT.¹⁶¹ Comorbidities resulting from multiorgan involvement have a significant impact on the outcome of LT, with structural cardiac disease being the most important contributor to mortality.^{152,162}

Increased intraoperative fluid requirements place a significant burden on cardiac function and pulmonary blood flow. Patients with AGS often have established right ventricular hypertrophy which, coupled with increased pulmonary vascular resistance associated with pulmonary artery stenosis, may increase the risk of diminished cardiac output and poor graft perfusion. Echocardiogram alone may be insufficient to assess the descending aorta and peripheral pulmonary artery

branches.¹⁵¹ Utilization of a dynamic stress test with dobutamine during cardiac catheterization can identify those patients who can successfully increase their cardiac output by over 40%, the necessary cardiac response for successful LT.¹⁶³

Posttransplant survival rates vary between 82.9% and 87% at 1 year, 78.4% and 86% at 5 years,¹⁶⁴ and 80.9% at 10 years.¹⁶⁵ Long-term survival rates between AGS and all other pediatric liver transplant recipients were reported to be similar in a single-center experience.¹⁶⁵ However, a review of the UNOS database revealed 5-year graft and patient survival was worse for AGS compared BA patients, 61.5% versus 70% ($P=0.02$) and 78.4% versus 84% ($P=0.01$), respectively.¹⁶⁴ Risk factors for poor outcome among AGS patients included neurological and cardiac complications. Renal disease associated with AGS will require a renal-sparing immunosuppressive regimen to minimize the risk of renal dysfunction following LT.¹⁶⁶

Recommendations:

36. Patients with AGS should be carefully assessed for evidence of extrabepatic manifestations of this multisystem disorder; decisions regarding liver transplant should be individualized to include potential nontransplant treatment options for nonlife-threatening complications such as intractable pruritus and deforming xanthoma with biliary diversion or ileal exclusion. (1-B).

37. Realistic expectations related to growth potential following LT should be made clear to the family. (1-B)

38. Careful assessment of cardiac and renal function should occur during LT evaluation in all liver transplant candidates. (2-B)

39. Pretransplant vascular imaging of the intra-abdominal vasculature should be performed (2-B); vascular imaging of the head and neck may be considered. (2-C)

Wilson's Disease

Wilson's disease (WD) is a chronic liver condition with a myriad of presentations. WD may be clinically indistinguishable from autoimmune hepatitis, nonalcoholic fatty liver disease, or cryptogenic cirrhosis.¹⁶⁷ The most dramatic presentation is fulminant WD, particularly when encephalopathy is present. A child over 5 years of age with ALF accompanied by a Coombs-negative hemolytic anemia and low or normal serum alkaline phosphatase should heighten the suspicion for WD. WD presenting with an acute hemolytic crisis carries a poor prognosis; short-term clinical and

biochemical improvement following plasma exchange coupled with chelation therapy is noted, but outcomes are variable.¹⁶⁸ The AASLD produced joint adult and pediatric guidelines that include recommendations for liver transplant evaluation.¹⁶⁷

Acute Liver Failure

Pediatric acute liver failure (PALF) is a rapidly evolving condition that differs from adults with ALF in areas of etiology, management, and outcomes.^{169,170} Efforts to define PALF remain challenging, but entry criteria established for the PALF longitudinal research study serve to identify children who require focused diagnostic and management strategies. Those entry criteria include: 1) absence of a known, chronic liver disease; 2) liver-based coagulopathy that is not responsive to parenteral vitamin K; 3) International Normalized Ratio (INR) between 1.5 and 1.9 with clinical evidence of encephalopathy or 2.0 and higher regardless of the presence of clinical encephalopathy.

Children with PALF may experience rapid clinical progression to irreversible brain injury or death.^{3,171} Diagnoses differ between infants, children, and adolescents with some that are potentially treatable, such as herpes simplex,¹⁷² gestational alloimmune liver disease,¹⁷³ autoimmune hepatitis,¹⁷⁴ acute acetaminophen toxicity,¹⁷⁵ and Wilson's disease.^{168,176} As clinical deterioration can occur rapidly and unexpectedly, coordinated management at a pediatric liver transplant center involving a pediatric gastroenterologist with expertise in liver disease, intensive care specialist, and liver transplant surgeon, along with other supportive personnel will optimize patient outcome. Outcomes vary among and between etiologies, patient age groups, and disease severity.¹⁶⁹ However, children with an indeterminate diagnosis are more likely to receive a liver transplant.¹⁷⁷

Decisions to proceed to liver transplant in PALF are complicated by difficulties in predicting outcome. Unfortunately, disease severity scores fall short in predicting the likelihood of death for an individual patient, raising the possibility that some children may have survived without a liver transplant.^{178,179} Equally problematic is the absence of tools or clinical paradigms to predict irreversible brain injury. Contraindications to LT in PALF include severe multisystem mitochondrial disease, particularly those associated with valproic acid toxicity,¹⁸⁰ uncontrolled sepsis, and irreversible cerebral edema with uncal herniation. Children presenting with ALF due to hemophagocytic lymphohistiocytosis are candidates for nonliver transplant therapies which include immunosuppressive therapy or bone marrow transplantation.¹⁸¹

Recommendations:

40. Pediatric acute liver failure (PALF) patients should receive early contact with and/or referral to a pediatric liver transplant center for multidisciplinary care. (1-B)

41. Establish an etiology of PALF in order to identify conditions that are treatable without LT or contraindicated for LT. (1-B)

Hepatic Tumors

Hepatoblastoma. Gold standard treatment of hepatoblastoma (HB) is perioperative chemotherapy followed by complete resection of all viable tumor.^{182,183} The Children's Oncology Group protocol for hepatoblastoma (COG-AHEP0731) suggests that tumors with potential for complete resection can be identified after 2-4 rounds of cisplatin-based chemotherapy. Those who undergo primary LT for unresectable HB have an 82% 10-year survival, while those who receive an LT for recurrence of HB following chemotherapy and resection ("rescue" LT) have a 30% 10-year survival.¹⁸⁴ The PRETEXT (Pretreatment Extent of disease)¹⁸⁵ is used to gauge extent of disease at the time of diagnosis and triage patients for early referral to a program with experience in both pediatric hepatobiliary surgery and liver transplantation. Patients with PRETEXT IV disease (disease involving all four sections of liver), complex PRETEXT III disease (multifocal or presence of venous thrombosis), or centrally located tumors whose location makes a tumor-free excision plane unlikely have poor outcomes with chemotherapy and surgical resection alone.¹⁸⁶ A recent report from a single institution reported 93% survival with aggressive resection in POST-TEXT III and IV patients with hepatoblastoma.¹⁸⁷

Patients with pulmonary metastases (PM) at the time of diagnosis have recurrence-free survival following LT that is similar to those without PM at the time of diagnosis if either of the following occurs following chemotherapy: 1) PM are no longer seen by computerized tomography (CT) or 2) residual PM are completely resected and tumor-free margins are identified.¹⁸⁴ In the absence of significant response to chemotherapy that would allow surgical resection of the liver tumor with clear margins and sufficient functional residual hepatic mass, total hepatectomy with LT has been demonstrated to have satisfactory long-term outcomes.¹⁸⁸⁻¹⁹¹

Recommendations:

42. Children with nonmetastatic and otherwise unresectable hepatoblastoma should be referred for

LT evaluation at the time of diagnosis or no later than after 2 rounds of chemotherapy. (1-B)

43. Patients with HB and pulmonary metastases can be considered for LT if, following chemotherapy, a chest CT is clear of metastases or, if a tumor is identified, the pulmonary wedge resection reveal the margins are free of the tumor. (1-B)

Hepatocellular Carcinoma. Hepatocellular carcinoma (HCC) is associated with chronic viral hepatitis (hepatitis B and hepatitis C), metabolic disease (tyrosinemia, progressive familial intrahepatic cholestasis, alpha-1 antitrypsin deficiency, Wilson's disease, glycogen storage disease, cholesterol ester storage disease), biliary atresia, Alagille syndrome, and parenteral nutrition associated liver disease. The incidence of HCC may be higher for children with vertically transmitted hepatitis B who seroconverted from hepatitis B e-antigen to hepatitis B e-antibody before the age of 3 years.¹⁹² For the majority of adults, HCC is identified in cirrhotic livers; the opposite is true for children, as 60-70% of HCC cases are found in a noncirrhotic liver.¹⁹³ HCC is rare and often advanced and inoperable at the time of diagnosis.¹⁹⁴ Screening procedures for HCC are not uniform, but alpha-fetoprotein is typically elevated over 400 ng/dL, often reaching over 1,000 ng/dL.^{195,196} Cure is accomplished only with complete surgical resection, although chemotherapy may be more effective in children than adults.¹⁹³ High recurrence rates in adults fell when LT was restricted to individuals who met the Milan criteria: a single tumor diameter less than 5 cm, no more than 3 foci with each one not exceeding 3 cm, and absence of vascular invasion, or extrahepatic involvement.¹⁹⁷ However, Milan criteria may not be applicable in children and recommendations must be individualized.^{190,193,195,198} Successful LT outcomes have been achieved even for those children who did not meet the more liberal University of California San Francisco Criteria (single tumor <6.5 cm or maximum of three tumors with none >4.5 cm and cumulative tumor size <8 cm) or the "up-to-seven" criteria (absence of angioinvasion, number of nodules plus the maximum size of the largest nodule equal or lower than 7).¹⁴⁴ Satisfactory LT outcomes have been achieved in some children with large, multifocal tumors, with some having microscopic blood vessel invasion or limited local extrahepatic extension.^{186,190,193}

Recommendations:

44. Prompt referral to a liver transplant center should occur for children with or suspected to have hepatocellular carcinoma. (2-B)

45. As the Milan criteria may not be applicable to children, transplantation for hepatocellular carcinoma must be individualized and should be considered in the absence of radiological evidence of extrahepatic disease or gross vascular invasion, irrespective of size of the lesion or number of lesions. (2-B)

46. Absolute contraindications to transplant include radiological evidence of extrahepatic disease (1-B); relative contraindications to transplant include major venous invasion, or rapid disease progression despite chemotherapy. (2-B)

47. Hepatocellular carcinoma (HCC) is uncommon among children and there are no current data to support general screening for HCC in children; children with bile salt excretory pump disease and tyrosinemia are at higher risk for developing HCC and should undergo periodic screening. (2-B)

Hemangioendothelioma. Infantile hemangioma (IH), the most common pediatric tumor, has three categories: 1) focal lesions, 2) multifocal lesions, and 3) diffuse lesions.¹⁹⁹ All focal and most multifocal lesions are asymptomatic and involute spontaneously. However, some multifocal lesions present with high output cardiac failure and can lead to a fatal outcome in the first year of life. Multifocal and diffuse lesions express GLUT-1, which may biologically distinguish them from focal lesions.²⁰⁰ With diffuse lesions, the liver is almost completely occupied by hemangiomas and symptoms include respiratory insufficiency due to an abdominal mass effect, abdominal compartment syndrome, coagulopathy (Kasabach-Merritt syndrome), multiorgan system failure, and hypothyroidism due to overproduction of type 3 iodothyronine deiodinase which converts thyroid hormone to its inactive form.²⁰¹ Diffuse hemangiomas often do not respond to steroid therapy²⁰² and most require surgical resection or beta-blocker therapy to improve hematologic parameters. Hepatic artery ligation and embolization have limited effect. Other treatment options for diffuse lesions include vincristine,²⁰³ actinomycin, and cyclophosphamide and propranolol.²⁰⁴

Recommendations:

48. Liver transplant evaluation for IH is indicated if the hemangioendothelioma is not responding to treatment or is associated with life-threatening complications. (1-B)

49. Candidates being considered for LT for a hemangioendothelioma should be screened for hypothyroidism. (2-B)

Cystic Fibrosis-Associated Liver Disease

Liver disease is present in up to 35% of cystic fibrosis (CF) patients, but only 5-10% of patients have cirrhosis.^{205,206} Ursodeoxycholic acid therapy is recommended, although its impact on the progression of CFLD is not known.²⁰⁷⁻²⁰⁹ Endstage liver disease is characterized by coagulopathy and hypoalbuminemia and is not attributable to malabsorption. Portal hypertensive-related hemorrhage alone, in the absence of other signs of decompensated liver disease, may not be a sufficient indication for LT in CF patients, as alternative therapies may be equally acceptable.²¹⁰⁻²¹² Optimal timing for isolated LT involves careful assessment of cardiopulmonary function, infections, and nutritional status in CF patients. Currently, Model for Endstage Liver Disease (MELD) / Pediatric Endstage Liver Disease (PELD) exception points are permitted for those patients with CF whose pulmonary function tests (PFTs) are <40% of predicted FEV1.^{213,214}

Five-year posttransplant survival rates for CFLD are lower than for those who underwent transplantation for other etiologies. Compared to those patients remaining on the waiting list, pediatric and adult transplant recipients with CF gained a significant survival benefit.²¹⁵ A different analysis of the UNOS database and various single center reports convey similar patient and graft survival data among patients with CF.^{212,216,217} While LT may improve pulmonary function and nutritional status,^{218,219} CF patients may be at higher relative risk for the development of posttransplant diabetes mellitus and renal impairment.²²⁰⁻²²³

Recommendation:

50. The indications for liver transplantation in CF are guided by the degree of hepatic synthetic failure and the presence of otherwise unmanageable complications of portal hypertension. Optimal timing for isolated liver transplantation involves careful assessment of pulmonary and cardiac function and nutritional status in CF patients. (2-B)

Urea Cycle Defects

Urea cycle disorders (UCDs) are inborn errors of nitrogen detoxification/arginine synthesis caused by defects in the urea cycle enzymes [carbamoylphosphate synthetase 1 (CPS1), ornithine transcarbamylase (OTC), argininosuccinate synthetase (ASS), argininosuccinate lyase (ASL), and arginase 1 (ARG1)], leading to respective deficiencies.²²⁴ The prevalence of UCDs is likely underestimated, as their clinical presentation can be similar to sepsis and death can occur before a diagnosis of UCDs is considered.^{225,226}

OTC deficiency is inherited in an X-linked manner, while the other UCDs are inherited in an autosomal recessive manner. Clinical manifestations occur at any age, but most commonly affect neonates. Typically, infants present within hours to days after birth with a catastrophic illness, starting with poor feeding, lethargy, vomiting, and tachypnea and then progressing rapidly to coma and death.²²⁷ Hyperammonemic crises, which account for the devastating neurological outcomes associated with UCDs, are frequently triggered by catabolic events, protein overload, or certain drugs.

The full complement of the “proximal” urea cycle enzymes (e.g., CPS1, OTC, and ASS) are almost exclusively expressed in the liver, while “distal” enzymes (e.g., ASL, ARG1) also have cerebral expression of uncertain clinical significance. LT essentially serves as an “enzyme replacement” therapy and appears to be curative, allowing for resumption of a normal diet and elimination of hyperammonemic crises.²²⁸⁻²³⁰ LT should be considered early in patients with severe UCDs, as irreversible neurological damage can occur.^{114,231} For patients with severe neurological disease or sequelae, LT may stabilize, but will not improve neurological outcome. Living related donation, after confirmation of the donor phenotype, has the advantage of allowing optimal timing of the procedure.^{114,232,233}

Recommendation:

51. Urgent referral for LT should be considered when patients present in the first year of life with severe UCDs in order to prevent or minimize irreversible neurological damage (1A); living related liver transplantation may be an option for some patients. (1-B)

Crigler-Najjar Type I

Crigler-Najjar syndrome type I (CNI) results from complete deficiency of the hepatocyte enzyme uridine diphosphate glucuronosyl transferase (UGT).²³⁴ CNI becomes apparent during the neonatal period by marked unconjugated hyperbilirubinemia. Treatment consists of initial exchange transfusions and long-term utilization of phototherapy, to prevent kernicterus.²³⁵ While phototherapy can effectively manage hyperbilirubinemia and prevent kernicterus,²³⁶ it is difficult to maintain. Successful phototherapy requires maximal body irradiance for 20-24 hours per day during hyperbilirubinemic crises and a minimum of 8-12 hours every day to maintain an acceptable bilirubin level. LT is the only effective treatment.^{237,238}

Recommendation:

52. Referral for LT evaluation should be considered for CNI patients before the development of brain damage, ideally at the time of diagnosis when the option of LT can be discussed. (1A)

Immune-Mediated Liver Disease

Autoimmune Hepatitis. Autoimmune hepatitis (AIH) is a progressive inflammatory liver disorder characterized by increased aminotransferases, high serum levels of immunoglobulin G (IgG), and the presence of autoantibodies: antinuclear antibody (ANA), antismooth muscle antibody (ASMA), antiliver-kidney microsomal antibody (anti-LKM), with a potentially more aggressive course in children.²³⁹ Type 1, characterized by positive ANA and/or ASMA, is more common,²⁴⁰ although Type 2, characterized by a positive anti-LKM, is more frequently associated with fulminant liver failure.²⁴⁰ In a study of 55 consecutive children with clinical and biochemical evidence of AIH, 27/55 (50%) had cholangiographic findings consistent with autoimmune sclerosing cholangitis (ASC).²⁴⁰ ASC subsequently developed in a patient with AIH and ulcerative colitis. Conventional treatment includes prednisone with or without azathioprine for both AIH and AIH/ASC; ursodeoxycholic acid may be helpful for those with AIH/ASC.²⁴¹ LT is required in 10%-20% of children with AIH.²³⁹ Despite a greater degree of immunosuppression required in the posttransplant period, outcomes are similar to the overall transplanted population in terms of infectious or metabolic complications. The risk of late rejection is higher for those who receive LT for AIH, but this does not result in increased chronic rejection, steroid resistant rejection, or the need for retransplantation,²⁴² which differs from adults.²⁴³ Pediatric patients transplanted for AIH may be at greater risk of developing ulcerative colitis after LT than adult patients.²⁴⁴ The risk of relapse of AIH posttransplant is estimated to be 10%-35%^{19,245,246}; however, criteria for recurrent AIH remain controversial.

Recommendations:

53. LT is considered in patients with autoimmune hepatitis (AIH) who present with acute liver failure associated with encephalopathy and those who develop complications of endstage liver disease not salvageable with medical therapy (2-B).

54. Children with AIH and families being evaluated for LT should be informed they may require more immunosuppression than children transplanted

for other indications and remain at risk for recurrence of AIH. (2-B)

Primary Sclerosing Cholangitis. Primary sclerosing cholangitis (PSC) is characterized by chronic inflammation and obliterative fibrosis of the intra- and/or extrahepatic biliary tree, leading to bile stasis and cirrhosis.^{240,241,247} Children with biliary features consistent with PSC can have isolated biliary tract disease or have histologic characteristics may present prior to, coincident with, or subsequent to histological and biochemical features of autoimmune hepatitis (AIH) type 1.²⁴⁸ Autoimmune sclerosing cholangitis (ASC) is the term used to describe the biliary features present in children with a primary diagnosis of AIH and it is more common in children than adults.²⁴⁰ There is uncertainty whether ASC in children and PSC in adults have similar biological underpinnings or outcomes. In lieu of the phrase “overlap” syndrome, which suggests two separate conditions occurring in the same patient, the International Autoimmune Hepatitis Group posits that patients should be categorized by the predominant condition (e.g., AIH, PSC) and those with “overlapping” features should not be considered to be unique diagnosis.²⁴⁹ Langerhans cell histiocytosis, primary and secondary immunodeficiencies, and cystic fibrosis have histological findings similar to PSC. LT is the only therapeutic option for endstage liver disease resulting from PSC.²⁵⁰

Immunoglobulin G4-associated cholangitis (IAC) is a newly recognized multisystem condition with intra- and extrahepatic biliary strictures that is often, but not always, associated with autoimmune pancreatitis.^{251,252} Strictures disappear with corticosteroid therapy. Evidence of IAC in children is currently limited to case reports with a similar clinical and biochemical presentation and response to corticosteroids that is seen in adults.²⁵³

Patients with PSC are at higher risk of developing inflammatory bowel disease (IBD) than the general population, with ulcerative colitis and Crohn's disease diagnosed before LT in 46% and 3.3% of children, respectively, and IBD diagnosed after LT in another 9.8%.²⁵⁴ Cholangiocarcinoma in children is rare and not all cases are associated with PSC.²⁵⁵ Risks associated with cholangiocarcinoma in PSC are not well defined in children,²⁵⁰ but HCC may be more prevalent among children with Crohn's disease and PSC.²⁵⁵

PSC accounts for 3.5% of pediatric patients listed for LT,²⁵⁶ and 2.6% pediatric transplants.²⁵⁴ LT is effective therapy for endstage liver disease due from PSC.²⁵⁷ Patient and graft survival rates are comparable to those of age-matched children who undergo trans-

plantation for other indications.²⁵⁴ Post-LT complications include intrahepatic biliary strictures, cholangitis, and disease recurrence in the graft.²⁵⁴ Patients with IBD and PSC have a higher recurrence rate post-LT compared to those with PSC alone. Five-year survival following LT for PSC is >80%.^{258,259}

Recommendations:

55. Surveillance for inflammatory bowel disease with a full colonoscopy with biopsy both before and after LT in patients with features of primary sclerosing cholangitis is recommended. (2-B)

56. LT evaluation should be considered for patients with decompensated liver disease, recurrent cholangitis, unmanageable bile duct strictures, and/or concerns for the risk of cholangiocarcinoma. (2-B)

Other Metabolic or Genetic Disorders

Progressive Familial Intrahepatic Cholestasis. Progressive familial intrahepatic cholestasis (PFIC) refers to a group of autosomal recessive cholestatic conditions. The nomenclature for these conditions is evolving as the underlying genetic defects and affected proteins are identified. Diagnosis is based on clinical manifestations, liver histology and genetic testing, as well as on specific tests excluding other causes of childhood cholestasis.²⁶⁰⁻²⁶²

Familial intrahepatic cholestasis 1 (FIC1) disease, formerly PFIC-1, results from a mutation in the *ATP8B1* gene and is a systemic disorder which may affect structural and functional integrity of microvilli.²⁶³ FIC1 disease typically presents in the first year of life with severe cholestasis and a normal serum gamma-glutamyl transferase (GGT). Vitamin D-deficient rickets and intracerebral bleeding as a consequence of vitamin K deficiency may be presenting features of FIC1 disease. Other symptoms include chronic diarrhea, asthma-like symptoms, and sensorineural hearing loss, likely as a result of abnormal microvilli in affected cells in the intestine, lungs, and cochlear hair cells. Ursodeoxycholic acid may improve cholestasis to the degree that other interventions can be delayed or avoided in about 30% of cases.²⁶⁴ Partial external biliary diversion (PEBD) or ileal exclusion (IE), if performed prior to the development of cirrhosis, can significantly slow disease progression with improvements in cholestasis, pruritus, growth, as well as contribute to clinical, biochemical, and histological improvement in FIC1 patients.²⁶⁵ Longer follow-up is needed to determine whether PEBD can obviate the need for LT in FIC1 disease.²⁶⁵ LT for FIC1 disease is an option for patients with advanced liver disease that

would not be amenable to PEBD or IE. Due to ATP8B1 expression in extrahepatic organs, including the small intestine and pancreas, short stature and diarrhea may develop or worsen following LT, which may affect quality of life.²⁶⁴ Progressive steatohepatitis that can lead to cirrhosis in the allograft liver have been described following LT.

Bile salt excretory pump (BSEP) disease, formerly PFIC-2, results from a mutation in the *ABCB11* gene that encodes the adenosine triphosphate (ATP)-dependent BSEP that is the principal bile acid transport protein located on the hepatocyte canalicular membrane. Similar to FIC1 disease, BSEP presents with a normal GGT cholestasis associated with profound fat soluble vitamin deficiency. However, BSEP disease is a more rapidly progressive liver disease associated with a greater degree of liver injury manifested by higher levels of aspartate aminotransferase (AST) and alanine aminotransferase (ALT), giant cell hepatitis, early development of cirrhosis and liver failure, cholelithiasis, and a high risk of developing HCC.²⁶⁴ A favorable clinical response to ursodeoxycholic acid and biliary diversion may be more likely for children with mild mutations, such as missense mutations.²⁶⁴ Unlike FIC1 disease, a successful LT in BSEP disease is curative for most children and is not associated with extrahepatic manifestations. However, there are reports of recurrent low GGT cholestasis following LT for BSEP disease that is associated with significant morbidity and mortality.²⁰

Multidrug resistance protein-3 (MDR-3) disease, formerly PFIC-3, results from a mutation in the *ABCB4* gene that codes for the MDR3 glycoprotein which serves as a phosphatidylcholine flippase, transferring the lipid from the inner to the outer leaflet of the canalicular membrane.²⁶¹ The resultant low levels of phosphatidylcholine likely allow bile acids with a high detergent quality to injure bile ducts resulting in progressive biliary disease. MDR-3 disease is associated with cholelithiasis, intrahepatic cholestasis of pregnancy, transient neonatal cholestasis, drug-induced cholestasis, and an autosomal recessive cholestatic liver disease associated with a high GGT.²⁶⁶ The age at presentation can range from infancy to adulthood. Initial symptoms include jaundice, pruritus, and biochemical evidence of hepatic dysfunction. Treatment with ursodeoxycholic acid can result in complete or partial clinical and biochemical improvement, but the disease can be unresponsive and rapidly progressive in about 15% of cases.²⁶⁶ Among 28 children with MDR3 disease followed by an Italian consortium, one died and five underwent successful LT.²⁶⁶ Those who died or

received an LT had either no response to ursodeoxycholic acid or a partial response that was associated with flares of liver injury and decompensated cirrhosis. In a Japanese cohort of 717 LRLT recipients, only 14 had PFIC: 11 FIC1, 3 BSEP, and 0 MDR3.²⁶⁷

Recommendations:

57. Ursodeoxycholic acid therapy followed by partial external biliary diversion (PEBD) or ileal exclusion (IE) should be an early consideration to improve cholestasis and pruritus for children with FIC1 and BSEP disease. (1-B)

58. Patients with BSEP disease should be monitored regularly for the development of HCC. (2-B)

59. LT in FIC1 disease can be associated with worsening extrahepatic manifestations and should be considered only if PEBD or IE failed or could not be performed. (2-B)

60. Families of children with BSEP disease who require LT should be cautioned that the disease may recur following LT. (2-B)

61. LT evaluation is indicated for patients with MDR3 disease whose disease fails to respond to ursodeoxycholic acid. (2-B)

62. The use of PFIC heterozygote live donor organs from family members remains a viable and feasible option for FIC1 and BSEP patients requiring LT but ongoing follow-up is needed. (2-B)

Alpha-1 Antitrypsin Deficiency. Liver disease associated with alpha-1 antitrypsin deficiency (A-1ATD) in children has protean manifestations.²⁶⁸ Only about 7% of children with the PI*ZZ-associated A-1ATD will have any prolonged obstructive jaundice in the first few months of life, and up to 80% of those children will not have evidence of chronic liver disease by 18 years of age.^{269,270} A-1ATD will rarely present with a rapidly progressive, life-threatening liver disease in infancy necessitating LT in the first few months of life.²⁷¹ Case studies reveal a portion of children will have a slowly progressive course which may either stabilize or continue toward decompensated liver disease.²⁷² Hepatocellular carcinoma can develop in children with cirrhosis and A-1ATD.²⁷³ New medical therapies for A-1ATD are being investigated.²⁷⁴

Bile Acid Synthesis Disorders. Inborn errors resulting in bile acid synthesis disorders (BASD) most commonly present as neonatal cholestasis or neonatal hepatitis, but can present as chronic liver disease in older children.²⁷⁵⁻²⁷⁷ These diseases are characterized by a failure to produce normal bile acids and an accumulation of unusual bile acids and bile acid

intermediaries.²⁷⁸ Unlike most cholestatic diseases, patients with inborn errors of bile acid synthesis generally present with the hallmark features of normal or low serum levels of primary bile acids, normal GGT concentrations, and the absence of pruritus.²⁷⁹ For a definitive diagnosis, fast atom bombardment-mass spectrometry (FAB-MS) and gas chromatography-mass spectrometry (GC-MS) analyses of serum and urine is recommended, but is only available in a few specialized referral laboratories.²⁸⁰ Early diagnosis of some defects of bile acid synthesis can be treated effectively with cholic acid and/or chenodeoxycholic acid, which down-regulate endogenous bile acid synthesis resulting in clinical, biochemical, and histologic improvement if therapy is initiated before significant liver disease is established.^{281,282} LT is indicated for progression to endstage liver disease.²⁸³

Recommendation:

63. Bile acid replacement therapy should be initiated as early as possible in children with a confirmed bile acid synthetic disorder; LT should be considered only in patients with progressive endstage liver disease due to inborn errors of bile acid synthesis or those known to be refractory to medical therapy. (1-B)

Hereditary Tyrosinemia Type 1. Hereditary tyrosinemia type 1 (HT) is a multisystem disorder often presenting in infancy with a profound coagulopathy despite minimally elevated or normal serum aminotransferase levels.²⁸⁴ Older children and even adults can present with features of chronic liver disease. Treatment with NTBC (2-(2-nitro-4-fluoromethylbenzoyl)-1,3-cyclohexanedione) results in rapid clinical and biochemical improvement, manifested by undetectable levels of succinylacetone in the urine within 24 hours, and has reduced early complications as well as the need for LT. There has been an increase in mean age at transplantation from 1.82 ± 2.86 years between 1988-1998 to 3.70 ± 4.42 years between 1999-2008.²⁸⁵ Failure to respond to NTBC within a week may be due to noncompliance or subtherapeutic NTBC, manifested by persistence of succinylacetone in the urine, or a fulminant course despite therapy.

The child that survives initial presentation without LT can experience an extended interval of good health. Hepatic nodules, if present initially, may persist, regress, or disappear on a combination of NTBC therapy and a low tyrosine / low phenylalanine diet. The AFP is elevated at presentation, but will normalize or

fall to levels less than 10 ng/L on NTBC therapy. Even if metabolic stability is achieved with NTBC therapy, compliance with dietary restrictions and NTBC administration can be challenging for some families. Despite best efforts with medical and dietary therapy, hepatocellular cancer may still occur and hence regular surveillance with AFP and liver imaging is recommended.^{286,287}

Recommendations:

64. Initial treatment of hereditary tyrosinemia type 1 is with NTBC when the diagnosis is established. (1-A)

65. Referral for LT evaluation should occur promptly if the child has progressive liver disease despite an adequate dose of and compliance with NTBC, rising AFP while on NTBC, a change in liver imaging with a single nodule exceeding 10 mm or an increase in the number or size of hepatic nodules, or if management with NTBC and diet cannot be adequately maintained. (1-B)

Glycogen Storage Disease. There are now 11 glycogen storage diseases (GSD) described and most have many subtypes.²⁸⁸ GSDs can have hepatic, muscular, cardiac, neurological, immunological, or mixed presentations that are increasingly identified within each class of GSD with the help of advancing metabolic and genetic techniques. The degree to which extrahepatic manifestations of GSD are evident will vary with each patient as enzymes necessary for glycogen metabolism are found in many tissues. Among the family of GSDs, LT has been performed predominantly in patients with GSD I, III, and IV.²⁸⁹

Glycogen storage disease type I (GSDI) is comprised of two major subtypes²⁹⁰: GSD type Ia (glucose-6-phosphatase deficiency) and GSD 1b (glucose-6-phosphate translocase deficiency) that affect the liver, kidney, and intestinal mucosa causing excessive accumulation of glycogen and fat in these organs. With good metabolic control, clinical manifestations such as growth retardation, hepatomegaly, hypoglycemia, lactic acidemia, hyperuricemia, and hyperlipidemia can be managed. Nephrocalcinosis, glomerular hyperfiltration, proteinuria, and endstage renal disease can occur. Hepatic adenomas (HA) are common and the prevalence of HCC increases with age reaching an estimated 50%-80% by the third decade of life.²⁹¹ Histology is the only sure way to differentiate HA from HCC, but may not be possible when numerous HAs are present. GSD type Ib has additional features that include neutropenia and impaired neutrophil

function, resulting in recurrent bacterial infections and oral and intestinal mucosa ulceration that resembles inflammatory bowel disease, particularly Crohn's disease.

The majority of patients with GSD III (debranching deficiency) have a disease that is generalized (type IIIa, 80% of cases) to involve liver, muscle, cardiac muscle, erythrocytes, and fibroblasts and a minority having disease that is restricted to the liver (Type IIIb).²⁹² The presence of fibrosis, ranging from minimal to cirrhosis, occurs in GSD III but not GSD I. Aminotransferase elevations can be marked in childhood,²⁹³ but become less apparent with time. Despite the presence of fibrosis or cirrhosis, synthetic function is typically preserved. Life expectancy for patients with GSD III has improved, such that the development of endstage liver disease and risk for HCC may heighten the need for LT for GSD IIIb patients. LT should be carefully considered in patients with GSD type IIIa as muscle weakness and cardiomyopathy can be slowly progressive and will not be reversed by LT and may progress despite LT.²⁹⁴

GSD IV (glycogen brancher deficiency) is a systemic, yet heterogeneous disorder resulting in accumulation of insoluble amylopectin-like polyglucosan in the liver heart, muscle, nervous system, and skin.²⁹⁵ The most common form in children appears to be predominantly hepatic with relatively rapid progression to cirrhosis and liver failure, with death by 5 years of age. Similar to GSD III, HCC can occur. The majority of reported cases of LT for GSD IV suggest a favorable outcome.^{294,296,297} However, systemic progression of amylopectin-like deposits in the heart and muscle can occur post-LT resulting in cardiac and neuromuscular dysfunction and, in some cases, death. GSD type III and type IV may be associated with hepatocellular carcinoma or hepatic failure.^{6,298}

LT for GSD serves to replace the enzyme deficiency in the liver and significantly improve metabolic control. Long-term survival following LT for GSD I, III, and IV appears to be better than a comparable control population who received an LT for conditions other than GSD.²⁸⁹ However, this study was not able to assess the impact or development of extrahepatic morbidities such as cardiomyopathy, myopathy, infectious complications, or inflammatory bowel disease.

Recommendations:

66. LT evaluation should be considered for patients with: GSD I with poor metabolic control, multiple hepatic adenomas, and/or concern for HCC

(1-B); GSD III and IV with poor metabolic control, complications of cirrhosis, progressive hepatic failure, and/or suspected liver malignancy. (1-B)

67. Disease-specific counseling for post-LT expectations should include, for: GSD Ia and Ib: heightened risk of renal complications; GSD 1b: development of inflammatory bowel disease; GSD IIIa and GSD IV: development of neuromuscular and cardiac complications; GSD I, III, IV: identification of HCC in explanted liver and risk of recurrence if it is present. (2-B)

Fatty Acid Oxidation Defects. Fatty acid β -oxidation is a key metabolic pathway for the maintenance of energy homeostasis for high energy requiring organs such as the heart and skeletal muscle, and provides the main energy supply during prolonged fasting.²⁹⁹ Fatty acid oxidation defects (FAOD) are inherited metabolic diseases with serious life-threatening symptoms such as hypoketotic hypoglycemia,^{300,301} acute encephalopathy, cardiomyopathy,³⁰² rhabdomyolysis,³⁰³ metabolic acidosis, and liver dysfunction.³⁰⁴ Triggering events include febrile illnesses, vomiting, and fasting can lead to severe complications. Hepatic presentation with hypoketotic hypoglycemia and Reye-like syndrome is usually seen in infancy, but can extend into childhood and adolescence.³⁰⁴ Infants born to mothers who develop acute fatty liver of pregnancy and HELLP syndrome (hemolysis, elevated liver enzymes, low platelets) are at risk for having a FAOD.^{305,306} FAOD may present as recurrent episodes of PALF.³⁰⁷

Treatment for FAOD is mostly dietary and involves recommendations with regard to the fat and carbohydrate content of the diet and the maximal length of fasting periods; intravenous glucose infusion of at least 10 mg/kg/min to maintain serum glucose above 100 mg/dL during a crisis. Abnormalities in fatty acid oxidation may predispose to a worse outcome in acute liver failure.³⁰⁴ Prompt dietary intervention may reverse symptoms, including those associated with PALF, and preclude the need for LT. LT is an acceptable therapeutic option for patients with FAOD who present with fulminant liver failure, but fail medical and dietary intervention.³⁰⁸

Recommendations:

68. Management of FAOD with diet and intravenous glucose should be the first line of therapy. (2-B)

69. Patients with FAOD should be considered for LT evaluation if they experience recurrent episodes of PALF or have failed medical therapy. (2-B)

Primary Hyperoxaluria Type 1. Primary hyperoxaluria Type 1 (PH1) is an autosomal recessive inborn error of glyoxylate metabolism, caused by a deficiency of the liver-specific peroxisomal enzyme alanine:glyoxylate aminotransferase (AGT). PH1 results in overproduction and excessive urinary excretion of oxalate, causing recurrent nephrolithiasis, nephrocalcinosis, or endstage kidney disease. Patients experience progressive decline in renal function and death from endstage renal disease. Calcium oxalate deposition extends to blood vessels, retina, heart, peripheral nerves, bone and bone marrow, subcutaneous tissue, and synovial fluid.³⁰⁹

As only the liver can detoxify glyoxylate, LT halts excess oxalate production and arrests further damage to the kidneys and/or other organs.³¹⁰ CLKT is recommended for patients with significant native renal injury.^{311,312} A sequential procedure with isolated LT followed by dialysis and then subsequent kidney transplantation reduces the systemic oxalate load and may be proposed in individual patients with endstage renal disease. While separate deceased donor organs are often used, successful sequential liver and kidney transplantation from a single living donor has been reported.³¹³ An isolated preemptive LT may be considered in patients with reduced renal function not requiring dialysis.³¹⁴

Recommendation:

70. Referral for LT evaluation should be considered at the time of diagnosis to allow all transplant options to be considered (2-B); decisions to proceed with preemptive LT (2-B), or CLKT (2-B), or sequential LT then KT (2-B) will depend on current and anticipated renal function.

Organic Acidemia. Organic acidemias, also known as organic acidurias, are a group of disorders characterized by increased excretion of (nonamino) organic acids in urine.³¹⁵ In aggregate, these diseases are categorized into five groups: branched chain organic acidemias, multiple carboxylase deficiencies, glutaric acidurias, fatty acid oxidation defects, and disorders of energy metabolism. Numerous types of organic acidemias exist, with methylmalonic acidemia (MMA), propionic acidemia, and isovaleric acidemia among the most prevalent forms. Other forms of organic acidemias include maple syrup urine disease (MSUD), homocystinuria, biotin-unresponsive 3-methylcrotonyl-CoA carboxylase deficiency, 3-hydroxy-3-methylglutaryl-CoA (HMG-CoA) lyase deficiency, ketothiolase deficiency, and glutaricacidemia type I

(GA I). The typical clinical presentation is a toxic encephalopathy associated with vomiting, poor feeding, and neurologic symptoms such as seizures, abnormal tone, and lethargy that progresses to coma. In older children, variant forms of organic acidemias present with loss of intellectual function, ataxia or other focal neurologic signs, Reye syndrome, recurrent ketoacidosis, or psychiatric symptoms.

Prolonged fasting, which can occur prior to anesthesia or diagnostic tests, can produce a catabolic state and precipitate a metabolic crisis. Therefore, elective hospitalizations or procedures that require the child with an organic acidemia to be fasted should be carefully planned with proper intravenous glucose support and metabolic monitoring. In particular, children admitted to hospital awaiting LT may experience an unexpectedly prolonged period of fasting while the donor organ is procured and its quality is assessed. Strategies to monitor and manage the metabolic disease during this period should be in place.³¹⁶

LT may be indicated in patients with organic acidemia experiencing frequent episodes of metabolic decompensation, uncontrollable hyperammonemia, restricted growth, or severe impairment of health-related quality of life with conventional medical treatment.^{114,315} A collaborative discussion with specialized metabolic teams is critical. LT may not completely correct the metabolic defect. For example, in the case of MMA, serum levels of MMA and protein tolerance improve following LT but do not normalize. Thus, MMA patients remain at risk for neurological deterioration and/or progressive renal insufficiency following LT.³¹⁷

In classic variant maple syrup urine disease (MSUD), a severe mitochondrial deficiency of the branch chain keto acid dehydrogenase (BCKDH) complex associated with volatile metabolic derangements with impaired brain development or unpredictable risk of neurologic crisis, the level of current metabolic control imparted by strict dietary management does not necessarily indicate protection against further episodes of metabolic decompensation.³¹⁸ Patients with classic variant MSUD defined by clinical phenotype of severe leucine intolerance (<15-30 mg/kg/day) have undergone LT successfully with elimination of dietary protein restriction and stabilization but without reversal of underlying neurocognitive deficits.^{316,319} Due to the ubiquitous presence of BCKDH complex in non-MSUD patients, explanted livers from patients receiving a transplant for MSUD may be transplanted to a non-MSUD patient ("domino" transplant),³²⁰ thereby improving organ utilization.

Recommendations:

71. LT may be indicated in patients with organic acidemia receiving conventional medical therapies who continue to experience frequent episodes of metabolic decompensation, uncontrollable hyperammonemia, restricted growth, or severe impairment of health-related quality of life with conventional medical treatment. (1-B)

72. Evaluation for LT should be considered in any patient with classic variant MSUD manifested by severe leucine intolerance. (2-B)

73. Meticulous management protocols should be in place for the preoperative period prior to LT surgery to prevent and, if necessary, treat metabolic decompensation while the child is fasting prior to LT. (2-B)

74. Domino LT should be considered an option in the setting of LT in MSUD. (2-B)

Familial Hypercholesterolemia. Familial hypercholesterolemia is an autosomal dominant disorder resulting from a mutation in the gene that encodes the low-density lipoprotein receptor. Severe hypercholesterolemia, atherosclerosis, and ischemic cardiac disease in the pediatric age group have been described. Recurrent plasma apheresis and statin medications can lower cholesterol levels and prevent the development of cardiovascular complications.³²¹ Patients require a thorough cardiovascular evaluation prior to transplantation to assess the severity of residual atherosclerotic disease. Coronary artery bypass graft surgery may be indicated prior to transplantation if atherosclerotic disease is severe. Early LT may provide an opportunity to improve management and minimize cardiovascular disease.³²²

Mitochondrial Hepatopathy and Systemic Mitochondrial Disease. Disorders of mitochondrial energy metabolism occur due to dysfunction of the respiratory chain (RC) with resultant cellular ATP deficiency, increased production of reactive oxygen species and toxic metabolites, and cell death.^{323,324} Mutations of nuclear or mitochondrial DNA result in disorders of mitochondrial energy metabolism, and can be inherited as autosomal dominant, autosomal recessive, or maternal inheritance. When a mutation of mtDNA occurs, both normal and mutant mtDNA can coexist in a single cell. However, the resultant phenotype is determined by the proportion of abnormal mtDNA. During cell division, mitochondria are randomly partitioned into daughter cells, resulting in heterogeneous levels of mutated mtDNA, and subsequent mitochondrial dysfunction in various organs and tissues. This likely explains why the disease phenotype may change

with age.³²⁵ While RC defects can involve any organ, those with high-energy requirements such as brain, liver, and muscle are more commonly affected.³²⁶ The three main RC defects associated with liver disease are deficiencies of RC enzymes, mtDNA depletion syndrome, and Alper's syndrome. The natural history of all three disorders is almost always fatal.^{325,327-329}

Mitochondrial diseases can have disparate manifestations ranging from acute liver failure in infancy, to multiorgan disease with significant neuromuscular involvement, to isolated chronic liver disease in the absence of overt neurological findings.^{323,330-332} Magnetic resonance imaging (MRI) of the brain, cerebral spinal fluid analysis, assessment of muscle enzymes, muscle biopsy for mitochondrial and respiratory chain analysis, echocardiogram, and assessment of renal tubular function are important to exclude systemic disease.^{333,334} Next-generation sequencing panels are becoming available to aid in the identification of these disorders.

Outcomes following LT for RC defects are mixed and available reports have limited follow-up.^{330,334,335} If the disease is confined to the liver a favorable outcome is possible, although exclusion of extrahepatic involvement is difficult, especially in the context of acute liver failure.³³⁴ Posttransplant neurological deterioration is possible even if a comprehensive pretransplant assessment for extrahepatic disease was normal.³²⁴ Progression of neurological disease in Alper's syndrome is inevitable after liver transplantation and leads to death.^{331,336} Valproic acid-associated acute liver failure in children less than 8 years of age may represent an "unmasking" of an undiagnosed systemic mitochondrial disease, as 1-year survival following LT is 20% with no survivors beyond 10 years, compared to a 69% 1- and 10-year survival rate for pediatric ALF not due to valproate.¹⁸⁰

A decision to exclude an individual with a mitochondrial hepatopathy from LT is difficult.³³⁷ In general, children with multiorgan mitochondrial disease, usually as evidenced by neuromuscular involvement, are poor candidates for LT, as they have had uniformly poor posttransplant neurological outcomes.^{324,331,336,338} Recently, a mitochondrial depletion syndrome caused by a mutation in the DGUOK gene was noted to present as neonatal hemochromatosis, which should prompt consideration of a systemic mitochondrial disease in patients presenting with ALF in the first weeks of life, hyperferritinemia, and hemosiderosis involving the liver and other organs.³³⁹

Recommendations:

75. Alper's syndrome or valproate-associated liver failure are contraindications to LT. (1-B)

76. Children with severe, life-threatening extrahepatic multiorgan mitochondrial disease are contraindicated for LT evaluation, as they have had uniformly poor posttransplant neurological outcomes. (1-B)

77. Absence of evidence for extrahepatic mitochondrial disease prior to LT does not exclude its development after LT; the family of potential LT candidates should be well informed of this possibility. (1-B)

Other Fibrotic/Cirrhotic Conditions

Ductal Plate Malformations. LT for biliary ductal plate malformations (DPM) associated with autosomal recessive polycystic kidney disease (ARPKD), Caroli's disease, and isolated congenital hepatic fibrosis is not often required in the pediatric age group.³⁴⁰ Progression of kidney and liver diseases are independent, and variability in severity of either liver or kidney disease does not correlate with genotype.³⁴¹ Complications associated with DPM include recurrent cholangitis, biliary sepsis, and portal hypertension complicated by variceal hemorrhage or pulmonary conditions (e.g., hepatopulmonary syndrome, pulmonary hypertension). Non-LT options to control bleeding varices include banding, transjugular intrahepatic portosystemic shunt (TIPS), and surgical portosystemic shunt. Transplant options include isolated LT (iLT), combined liver-kidney transplant (CLKT), and isolated kidney transplant (iKT). Decisions to proceed with iLT can be complicated by the degree of renal dysfunction. A mortality rate of 21% was identified in patients with ARPKD who received an iKT and it was directly related to recurrent cholangitis associated with Caroli's disease.³⁴² When required, LT outcomes are excellent.³⁴³

Recommendations:

78. Early referral of LT evaluation for ductal plate malformations should be considered for patients who develop recurrent cholangitis or complications associated with portal hypertension to further assess renal dysfunction in the context of the patients liver disease. (2-B)

79. General recommendations on when to proceed to iLT, CLKT, or iKT cannot be made, as decisions should be individualized based on morbidity associated with the liver and/or kidney disease and anticipated "tolerance" of the nontransplanted organ to surgical and medical therapies associated with transplantation. (2-B)

80. Patients with endstage renal disease associated with Caroli's disease should be strongly considered for combined liver and kidney transplantation. (1-C)

Parenteral Nutrition-Associated Liver Disease. Patients with parenteral nutrition-associated liver disease (PNALD) are referred for LT in the context of three clinical scenarios: 1) in combination with intestinal or multi-visceral transplantation; 2) isolated LT (iLT) in children with intestinal failure approaching but not achieving enteral autonomy; and 3) isolated LT after enteral autonomy is achieved, but the consequences of endstage liver disease persist and impact longevity.³⁴⁴ Early reports of iLT for selected patients with PNALD were encouraging.³⁴⁵ However, a recent report from Birmingham, UK suggest that it is currently difficult to predict who will achieve enteral autonomy following iLT, with 8/14 surviving at a median of 107.5 months (range 89-153) and 5/8 surviving children able to be weaned from PN to enteral nutrition within a median of 10 months (range 3-32) following iLT.³⁴⁶

PNALD results from myriad factors including prematurity, sepsis, lack of enteral feeding, intestinal failure, abdominal surgery, as well as various component of PN including protein, glucose infusion rate, and in particular lipid administration. Prolonged administration of a soy-based lipid exceeding 1 gm/kg/d in the management of pediatric intestinal failure has been implicated as an important factor in the development of cholestasis.^{347,348}

Strategies that have been used to manage children with PNALD include cycling PN, initiation and advancement of enteral feeds, and minimizing the risk of sepsis with good central line care coupled with appropriate use of antibiotic and/or ethanol lock therapy.³⁴⁹ Alteration of PN management is also beneficial by keeping the glucose infusion rate below 15-16 mg/kg/minute as well as alternative lipid strategies. Reduction of daily infusion of a soy-based lipid to 1 gm/kg/d has resulted in reversal of PNALD.³⁴⁸ Use of lipid that is not soy-based (e.g., fish oil-based) at an infusion rate of 1 gm/kg/d has also resulted in reversal of cholestasis, but it may not reverse progression of fibrosis.^{350,351}

Recommendations:

81. Prior to consideration of LT referral, strategies should be initiated to prevent and reverse PNALD that include lipid-minimization, intravenous lipids that are not soy-based, enteral feeding, PN management, and prevention of infections. (1-B)

82. Referral for isolated LT for PNALD should be considered for children who have achieved enteral autonomy but have developed complications of cirrhosis (2-B); for those who continue to require PN, LT evaluation should take place at a center with an

experienced multidisciplinary intestinal failure and intestinal transplant team (2-B).

Cryptogenic Cirrhosis. Cryptogenic cirrhosis leading to endstage liver disease is relatively rare in children. “Burnt out” nonalcoholic fatty liver disease needs to be considered, particularly because of the associated risk of cardiovascular disease. In patients suspected of having “burnt out” nonalcoholic fatty liver disease, LT evaluation should include careful cardiovascular assessment, particularly impaired flow-mediated vasodilatation and increased carotid artery intimal medial thickness, both of which are markers of subclinical atherosclerosis.³⁵² Rare inborn errors of metabolism, such as bile acid synthetic defects, should be considered, as the diagnosis may inform subsequent pregnancies and an available treatment may alter outcome.

Miscellaneous Conditions

Factor VII Deficiency. Factor VII deficiency is managed with fresh-frozen plasma, plasma-derived factor concentrates, or recombinant factor VIIa.^{353,354} Treatment is typically reserved for bleeding prevention prior to surgical procedures and spontaneous bleeding. Prophylaxis is reserved for newborns who are prone to early and severe gastrointestinal and central nervous system bleeding and others with a history of severe bleeding associated with surgery or menstruation. Affected patients can expect normal longevity if the condition is properly managed. LT is curative, but should be reserved for the most severely affected patients.^{355,356} Children undergoing transplantation will require factor replacement during the surgery and first 1-3 days after transplant surgery.³⁵⁷

Protein C Deficiency. Purpura fulminans in the newborn period is the most dramatic and life-threatening presentation of protein C deficiency.^{358,359} Beyond the newborn period, clinical manifestations are heterogeneous but are associated with an increased risk of vascular thrombosis. Current management of protein C deficiency includes oral anticoagulants, low molecular weight heparin, and intravenous or subcutaneous protein C concentrate.^{359,360} LT is curative, and typically occurs in the setting of multivisceral transplantation following an abdominal catastrophe due to mesenteric vein thrombosis or renal vein thrombosis.³⁶¹

Recommendation:

83. Medical management of Factor VII and Protein C deficiency is preferred; LT should be considered only for those who experience complications or failure of management. (2-B)

Budd-Chiari Syndrome. Budd-Chiari syndrome (BCS) is the result of hepatic venous outflow tract obstruction at any level from any mechanism, exclusive of cardiac disease. An underlying risk factor for thrombosis is identified in up to 87% of adult BCS cases.^{362,363} Whether this prevalence is similar in children with BCS is not known, as evaluation for underlying prothrombotic conditions has not been routinely investigated in this age group. Prognostic scoring systems have not been systematically evaluated in children.^{363,364} Transjugular intrahepatic portosystemic shunts (TIPS) should be considered in the majority of patients not responsive to medical therapy and have been successfully used in children.^{365,366} Well-selected patients with acute liver failure or advanced chronic disease from BCS can benefit from LT with good long-term posttransplant survival. LT is generally thought to be contraindicated for BCS that occurs due to paroxysmal nocturnal hemoglobinuria, as recurrence of intravascular thrombosis in the graft can be expected; however, scheduled treatments with the anti-complement antibody eculizumab, before and after LT, resulted in stable graft function without radiographic recurrence of thrombosis 1.5 years following LT.³⁶⁷ Most patients transplanted for BCS remain on some form of prolonged anticoagulation.³⁶⁸⁻³⁷¹

Recommendation:

84. Patients with progressive endstage liver disease from BCS benefit from LT, where others with less severe disease may benefit from alternative therapy. (2-B)

Noncirrhotic Portal Hypertension. Noncirrhotic portal hypertension (NCPH) is often classified based on the level of the vascular obstruction into suprahepatic, intrahepatic, or prehepatic, and is the result of an obliterative vasculopathy resulting from a variety of insults such as infections, drugs or toxins, immune disorders, or thrombophilic states. Patients of all age groups will typically present with gastrointestinal hemorrhage and splenomegaly, and less commonly with hepatic synthetic failure.³⁷² Endoscopic control of variceal hemorrhage, TIPS, or surgical shunts are usually available as options in the management of patients with NCPH.³⁷³ The meso-Rex bypass is an excellent option if the child has an accessible intrahepatic left portal vein.³⁷³ Increasingly, hepatopulmonary syndrome (HPS) is recognized as a complication of NCPH.^{374,375} If HPS is present prior to initiating a management strategy for portal hypertension associated with NCPH, the clinical features of HPS may worsen

HPS, or if not present, may develop.^{15,373,376} Symptoms of HPS in patients with NCPH can resolve following LT.^{374,377-381}

Recommendation:

85. The role of LT in NCPH should be considered in those patients with cardiopulmonary complications of portal hypertension. (2-B)

Sickle Cell Anemia. LT has been successfully performed in a small number of children and adults with advanced liver disease in the setting of sickle cell anemia, but morbidity from vascular thrombosis including graft thrombosis, stroke or pulmonary embolus, and infections is common.³⁸²⁻³⁸⁴ Vaso-occlusive crises continue after LT.³⁸⁴ Careful patient selection as well as management of the sickle cell disease, including exchange transfusion, is required in order to successfully perform LT in patients with this systemic disorder.

Complications of Portal Hypertension

Hepatopulmonary Syndrome. Hepatopulmonary syndrome (HPS) is a condition in which intrapulmonary vascular dilatations (IPVD) develop in the setting of portal systemic shunting.³⁸⁵ The presence of HPS is associated with increased morbidity and mortality,³⁸⁶ but is generally reversible after transplantation and is not a contraindication for transplantation.³⁸⁷ HPS is present in 4 to 29% chronic liver disease patients of all ages.^{43,388,389} Among patients with biliary atresia, HPS may occur more commonly in children with splenic malformation syndrome.^{125,381} It is important to recognize that HPS can occur in patients without evidence of liver dysfunction (e.g., congenital hepatic fibrosis, portal vein thrombosis, cavernous transformation of the portal vein). The diagnosis of HPS in children is confirmed by the presence of hypoxia and one of the following demonstrating the presence of IPVD: 1) contrast-enhanced transthoracic echocardiography; 2) technetium-labeled macro-aggregated albumin lung perfusion scan demonstrating a shunt fraction of >6%; or 3) cardiac catheterization demonstrating IPVD.⁴⁴ Severe shunting of >20%, as determined by macro-aggregated albumin scan, is associated with increased posttransplantation morbidity and mortality in adults.^{44,386} The median survival in the absence of LT in adults with severe HPS (paO₂ <50 mmHg) is less than 12 months, but is unknown in children.³⁹⁰⁻

³⁹² Patients with HPS may benefit from supplemental oxygen, particularly during periods of increased physical activity.¹² LT is appropriate for the treatment of HPS in children with cirrhotic liver disease and may

be appropriate in some noncirrhotic patients with HPS. Noncirrhotic liver disease or congenital/acquired portosystemic venous communications (e.g., Abernathy syndrome) resulting in HPS may present opportunities for alternative nontransplant approaches to management.^{387,393-396} These approaches include ligation of the shunt or endovascular treatment using an occlusion device placed by an interventional radiologist.

Recommendations:

86. Children with portosystemic shunting associated with cirrhotic or noncirrhotic portal hypertension or congenital/acquired portosystemic shunts should be regularly screened for the development of HPS with room air pulse oximetry in an upright position. (2-B)

87. Closure of a congenital portosystemic shunt should be considered as an alternative to LT. (2-B)

88. Transplantation is indicated in children with HPS and portosystemic shunting resulting from either a congenital or acquired vascular anomaly or liver disease (cirrhotic or noncirrhotic) and portal hypertension who are not candidates for closure of the shunt. (2-B)

Portopulmonary Hypertension. Portopulmonary hypertension (PPH) is a rare, insidious, and devastating complication of portosystemic shunting of any cause.⁴⁶ Presenting symptoms include dyspnea, cough, or syncope, but these cardiopulmonary symptoms may be absent. Cardiomegaly may or may not be present on chest x-ray and an electrocardiogram (EKG) may reveal right ventricular hypertrophy, but is most often normal.^{46,397} A transthoracic echocardiogram (ECHO) with evidence of right ventricular wall thickening, tricuspid valve regurgitation, and a calculated pulmonary artery systolic pressure ≥ 40 mmHg is the best noninvasive screening tool.³⁹⁸ Flattening of the inter-ventricular septum, if present on ECHO, may suggest pulmonary artery pressures are near systemic pressure. Cardiac catheterization to exclude other causes of pulmonary hypertension and measure the mean pulmonary artery pressure (MPAP) is required to establish the diagnosis of PPH. A PPH severity scale is not established for children, but in adults PPH is considered mild, moderate, or severe if the MPAP is >25 to ≤ 35 , >35 to ≤ 45 , and >45 mmHg, respectively.³⁹⁹ The presence of severe PPH with MPAP of >50 mmHg has a high risk of mortality, but long-term survival has been reported in a few patients.³⁹⁹

Experience with PPH in children is limited to case reports and single-site experiences.⁴⁶ Medical therapy

can stabilize and improve PPH in children and lead to successful LT and subsequent resolution of PPH.^{397,400} Case reports suggest that treatment with endothelin receptor antagonists, prostanoids, and sildenafil can lower the pulmonary pressure and enable liver transplantation. Severe, uncorrected PPH with MPAP >45 mmHg remains a contraindication for LTx in adults. However, a child with PPH responsive to aggressive medical management but not achieving a MPAP of <45 mmHg did undergo a successful LT.³⁹⁷ This raises the possibility that MPAP setpoints for adults may not apply to children. Listed patients with severe PPH who are responsive to medical therapy indicated by a reduction of the MPAP to <35mmHg now qualify for a model for endstage liver disease (MELD) score exception to receive a liver transplant. However, a similar algorithm has not been developed for children less than 12 years of age. Pulmonary hypertension not responsive to medical therapy is probably a contraindication for transplantation.⁴⁰¹

Recommendation:

89. Children with evidence of PPH should be promptly referred for LT evaluation. (2-B)

Contraindications to Liver Transplantation

Due to the scarcity of donor organs, transplant professionals must identify those in greatest need for LT as well as identify which patients are truly benefited by listing for and ultimately undergoing liver transplant.^{402,403} Absolute contraindications to LT are those clinical circumstances that consistently lead to poor outcome for the patient and graft. Relative contraindications are those situations which may lead to poor patient and graft outcome, but are potentially correctable (Table 4).

Extrahepatic Malignancy

Given that the need for posttransplant immunosuppression inherently increases the risk of *de novo* and recurrent malignancy, most centers require some period of recurrence-free survival and a low projected rate of recurrence of primary malignancy before listing for LT.⁴⁰⁴ Active, uncontrolled extrahepatic malignancy should be considered an absolute contraindication to LT in children. Patients who have liver metastases from neuroendocrine tumors are a potential exception to this category, a situation rarely encountered in pediatrics.⁴⁰⁵ Specific discussions regarding the evaluation of extrahepatic extension of liver-based tumors in childhood are located in other sections of this guideline.

Table 4. Contraindications to Liver Transplantation

Absolute	
Hepatocellular carcinoma with extrahepatic disease and rapid progression	
Generalized extrahepatic malignancy	
Exception: Hepatoblastoma with isolated pulmonary metastases	
Uncontrolled systemic infection	
Severe multisystem mitochondrial disease	
Valproate induced liver failure	
Niemann-Pick Disease Type C	
Severe portopulmonary hypertension not responsive to medical therapy	
Relative	
Hepatocellular carcinoma with	
Venous invasion	
Rapid progression despite chemotherapy	
High certainty of nonadherence despite multidisciplinary interventions and support	
Hemophagocytic lymphohistiocytosis	
Critical circumstances not amenable to psychosocial intervention.	

Recommendation:

90. Active, uncontrolled extrahepatic malignancy is an absolute contraindication to LT in children. (1-A)

Systemic Infection

Active uncontrolled infection from bacteria, fungus, or virus can lead to high postsurgical mortality and therefore LT in this situation is to be avoided.^{402,403,406} Blood cultures and peritoneal fluid cultures (if applicable) should be negative for at least 48 hours prior to listing for transplant. Isolated case reports of successful LT in PALF associated with herpes simplex despite positive blood cultures have been reported.^{407,408}

Recommendation:

91. Active uncontrolled systemic infection from bacteria, fungus, or virus can lead to high postsurgical mortality, and therefore LT in this situation is to be avoided. (1-B)

Niemann-Pick Disease Type C

Niemann-Pick disease type C (NP-C) is a rare autosomal recessive systemic neuro-visceral disease characterized by progressive disabling neurological symptoms and premature death in most patients.⁴⁰⁹ Clinical presentations of NP-C are heterogeneous and include cholestasis, hepatosplenomegaly, and acute liver failure.⁴⁰⁹⁻⁴¹² Diagnosis requires demonstration of impaired intracellular cholesterol transport by filipin staining in fibroblasts cultured from patient skin biopsies. DNA sequencing should ideally be performed in parallel with filipin staining where possible, but cannot replace filipin staining as the primary diagnostic method.⁴⁰⁹ Bone marrow infiltration with foam cells is a measure of disease burden, but may be minimal

with early disease.⁴⁰⁹ Histological features diagnostic of NP-C are found on liver biopsy in only 50% of cases.⁴¹³ LT has been shown to be ineffective in altering the progression of neurological deterioration.⁴¹⁴

Recommendation:

92. LT is contraindicated in NP-C as it does not alter neurological disease progression. (1-B)

Hemophagocytic Lymphohistiocytosis Presenting as Acute Liver Failure

Hemophagocytic lymphohistiocytosis (HLH) is a rare disorder of cellular immunity characterized by reduced or absent cytotoxic T cell and NK cell activity, which results in loss of control of histiocyte/T-cell proliferation and activation in response to stimuli. Primary (familial) HLH is inherited as an autosomal recessive disorder, while secondary (acquired) HLH occurs following systemic infection or due to immunodeficiency.^{415,416} Although the onset and clinical course of familial HLH is variable, most cases (80%) occur within the first year of age. Familial HLH has been reported in neonates as early as the first days, and even in preterm infants.^{417,418} Symptoms result from the infiltration of various organs by hyperactivated macrophages and lymphocytes, and diffuse intravascular hemophagocytosis. Infantile acute liver failure remains a rare presentation of HLH, but is critically important to recognize, as chemotherapy and bone marrow transplantation (BMT) may reverse an otherwise unfavorable prognosis. At the present time, LT is considered contraindicated given the relapse risk in the transplanted organ.^{417,419}

Recommendation:

93. Recognition of HLH as a potential cause of acute liver failure is important, as more specific medical therapy, such as chemotherapy and bone marrow transplantation, is available (2-B).

Organ Allocation in the USA

The Model for Endstage Liver Disease (MELD) utilizes a formula that includes total serum bilirubin, International Normalized Ratio of prothrombin time (INR), and serum creatinine and is used for adults and children ≥ 12 years of age.⁴²⁰ The Pediatric Endstage Liver Disease (PELD) score was developed from children enrolled in the Studies of Pediatric LT (SPLIT) database. PELD is designed for children under 12 years of age and utilizes total serum bilirubin, INR, height, weight, and albumin.⁴²¹ The PELD system has benefited children in many ways.⁴²² How-

ever, just over 50% of children did not undergo LT with their calculated PELD score.⁴²³ Rather, letters of exception were required to secure additional points or to request Status 1 listing for reasons other than liver failure in order to receive an LT. In addition, regional differences in PELD score utilization are noted.⁴²³ A study using UNOS registry data reached a similar conclusion, indicating that PELD has not resulted in standardization of listing practices in pediatric LT.⁴²⁴

PELD Exceptions

When the PELD score is believed not to reflect the severity of liver disease or its consequences, an appeal letter can be written to the Regional Review Board (RRB). UNOS and the RRBs established conditions in which the PELD score can be adjusted higher; these conditions include failure to thrive, intractable ascites, pathologic bone fractures, refractory pruritus, and hemorrhage due to complications associated with portal hypertension.

A pediatric liver transplant candidate with a urea cycle disorder or organic acidemia shall be assigned a PELD (less than 12 years old) or MELD (12-17 years old) score of 30. If the candidate does not receive a transplant within 30 days of being listed with a MELD/PELD of 30, then the candidate may be listed as a Status 1B. Candidates meeting these criteria will be listed as a MELD/PELD of 30 and subsequent Status 1B without RRB reviews. A similar policy exists for hepatoblastoma, although the 30 days at PELD 30 is no longer required before status 1B. Hospitalization is not a requirement for listing in Status 1B for these candidates. Candidates with other metabolic diseases may apply to the RRB for an appropriate PELD (less than 12 years old) or MELD (12-17 years old) score. RRB will accept or reject the center's requested MELD/PELD score based on guidelines developed by each RRB. A study conducted using UNOS database revealed that widespread regional variations exist.⁴²⁵

International Experiences Liver organ allocation policies vary worldwide. Some individual and collaborating countries, such as the United Kingdom, Brazil, and Eurotransplant,⁴²⁶⁻⁴²⁸ have a national organ registry, while others have regional/provincial or center-based waiting lists in place as seen in Australia, Canada, and others.⁴²⁹⁻⁴³¹

Technical Variants

Technical Variant Grafts

LT in children is optimally performed in centers of excellence with broad experience in pediatric

hepatology and surgical expertise in pediatric hepatobiliary surgery and all applicable liver transplant techniques. The introduction of live donor LT, as well as other technical variant grafts such as deceased donor split grafts, has significantly reduced mortality on the pediatric liver list.⁴³² While comprehensive registry analyses suggest some detrimental impact on long-term graft survival with deceased donor split grafts,⁴³³⁻⁴³⁵ these techniques have been successfully applied in carefully selected cases by experienced practitioners.

Domino Transplantation

The first sequential or domino LT was performed using structurally normal liver from a familial amyloidotic neuropathy (FAP) patient in Portugal.⁴³⁶ Livers removed from patients with maple syrup urine disease (MSUD) have also been utilized for domino transplantation with satisfactory outcome reported in a small number of MSUD-liver recipients.⁴³⁷ Morphologically normal livers from patients with primary hyperoxaluria type 1 (PH1) were used for domino transplant in Europe, but all PH1-liver recipients developed kidney failure within the first 4 weeks after transplantation.⁴³⁸ A PH1-liver was used in a neonate with acute liver failure as a bridge to survival; the patient was retransplanted within 4 months after domino transplant.⁴³⁹ Besides technical challenges, domino transplant also carries ethical dilemma in terms of allocation of a liver allograft with known genetic defect. These issues should be thoroughly discussed with recipients of a domino organ.

Recommendation:

94. Domino LT using a donor liver with a known metabolic defect should be used in selected conditions and requires further analysis on long-term outcomes of recipient cases. (2-B); livers from patients with primary hyperoxaluria type 1 should not serve as domino organs. (2-B).

Liver Cell/Hepatocyte Transplantation

Hepatocyte transplantation (HcT) has been trialed in limited settings in both acute liver failure and metabolic disease.⁴⁴⁰ Currently, results of HcT have been limited by insufficient donor cell engraftment as well as a limited ability to monitor function of the transplanted cells or identify rejection in a timely fashion to alter immunosuppression before the graft is lost.^{441,442} Consideration for hepatocyte transplantation can be considered in the context of approved clinical research trials either as a bridge to solid organ transplantation or in selected cases as definitive therapy.

Acknowledgment: This practice guideline was produced in collaboration with the AASLD Practice Guidelines Committee which provided peer review of the article. Members of the committee include Jayant A. Talwalkar, M.D., MPH (Chair), Keith D. Lindor, M.D. (Board Liaison), Hari S. Conjeevaram, M.D., M.S., David A. Gerber, M.D., Christine Hsu, M.D., Fasiha Kanwal, M.D., MSHS, Marlyn J. Mayo, M.D., Raphael B. Merriman, M.D., Gerald Y. Minuk, M.D., Alexander Monto, M.D., Michael K. Porayko, M.D., Benjamin L. Shneider, M.D., R. Todd Stravitz, M.D., Tram T. Tran, M.D., and Helen S. Yee, Pharm.D. Benjamin L. Shneider, M.D., and Richard A. Schreiber, M.D., served as primary reviewers for the AASLD Practice Guidelines Committee. The guideline was approved by AASLD on February 28, 2014, NASPGHAN on January 2, 2014, and AST on February 18, 2014.

References

- Murray KF, Carithers RL, Jr. AASLD practice guidelines: evaluation of the patient for liver transplantation. *HEPATOLOGY* 2005;41:1407-1432.
- Committee on Bioethics, American Academy of Pediatrics. Informed consent, parental permission, and assent in pediatric practice. *Pediatrics* 1995;95:314-317.
- Rivera-Penera T, Moreno J, Skaff C, McDiarmid S, Vargas J, Ament ME. Delayed encephalopathy in fulminant hepatic failure in the pediatric population and the role of liver transplantation. *J Pediatr Gastroenterol Nutr* 1997;24:128-134.
- Shellmer DA, DeVito Dabbs A, Dew MA, Noll RB, Feldman H, Strauss KA, et al. Cognitive and adaptive functioning after liver transplantation for maple syrup urine disease: a case series. *Pediatr Transpl* 2011;15:58-64.
- Agarwala S. Primary malignant liver tumors in children. *Indian J Pediatr* 2012;79:793-800.
- Arikan C, Kilic M, Nart D, Ozgenc F, Ozkan T, Tokat Y, et al. Hepatocellular carcinoma in children and effect of living-donor liver transplantation on outcome. *Pediatr Transpl* 2006;10:42-47.
- Shneider BL, Brown MB, Haber B, Whittington PF, Schwarz K, Squires R, et al. A multicenter study of the outcome of biliary atresia in the United States, 1997 to 2000. *J Pediatr* 2006;148:467-474.
- Cardona J, Houssin D, Gauthier F, Devictor D, Losay J, Hadchouel M, et al. Liver transplantation in children with Alagille syndrome—a study of twelve cases. *Transplantation* 1995;60:339-342.
- Kamath BM, Olthoff KM. Liver transplantation in children: update 2010. *Pediatr Clin North Am* 2010;57:401-414, table of contents.
- Squires RH. End-stage liver disease in children. *Curr Treat Opt Gastroenterol* 2001;4:409-421.
- Giefer MJ, Murray KF, Colletti RB. Pathophysiology, diagnosis, and management of pediatric ascites. *J Pediatr Gastroenterol Nutr* 2011;52:503-513.
- Gentilini P, Casini-Raggi V, Di Fiore G, Romanelli RG, Buzzelli G, Pinzani M, et al. Albumin improves the response to diuretics in patients with cirrhosis and ascites: results of a randomized, controlled trial. *J Hepatol* 1999;30:639-645.
- Cardenas A, Gines P. Management of refractory ascites. *Clin Gastroenterol Hepatol* 2005;3:1187-1191.
- Kramer RE, Sokol RJ, Yerushalmi B, Liu E, MacKenzie T, Hoffenberg EJ, et al. Large-volume paracentesis in the management of ascites in children. *J Pediatr Gastroenterol Nutr* 2001;33:245-249.
- Di Giorgio A, Agazzi R, Alberti D, Colledan M, D'Antiga L. Feasibility and efficacy of transjugular intrahepatic portosystemic shunt (TIPS) in children. *J Pediatr Gastroenterol Nutr* 2012;54:594-600.

16. Gana JC, Valentino PL, Morinville V, O'Connor C, Ling SC. Variation in care for children with esophageal varices: a study of physicians', patients', and families' approaches and attitudes. *J Pediatr Gastroenterol Nutr* 2011;52:751-755.
17. D'Antiga L. Medical management of esophageal varices and portal hypertension in children. *Semin Pediatr Surg* 2012;21:211-218.
18. Shneider BL, Bosch J, de Franchis R, Emre SH, Groszmann RJ, Ling SC, et al. Portal hypertension in children: expert pediatric opinion on the report of the Baveno v Consensus Workshop on Methodology of Diagnosis and Therapy in Portal Hypertension. *Pediatr Transpl* 2012;16:426-437.
19. Gautam M, Cheruvattath R, Balan V. Recurrence of autoimmune liver disease after liver transplantation: a systematic review. *Liver Transpl* 2006;12:1813-1824.
20. Siebold L, Dick AA, Thompson R, Maggiore G, Jacquemin E, Jaffe R, et al. Recurrent low gamma-glutamyl transpeptidase cholestasis following liver transplantation for bile salt export pump (BSEP) disease (post-transplant recurrent BSEP disease). *Liver Transpl* 2010;16:856-863.
21. Miloh T, Arnon R, Shneider B, Suchy F, Kerker N. A retrospective single-center review of primary sclerosing cholangitis in children. *Clin Gastroenterol Hepatol* 2009;7:239-245.
22. Hanouneh IA, Macaron C, Lopez R, Zein NN, Lashner BA. Risk of colonic neoplasia after liver transplantation for primary sclerosing cholangitis. *Inflamm Bowel Dis* 2012;18:269-274.
23. Greer R, Lehnert M, Lewindon P, Cleghorn GJ, Shepherd RW. Body composition and components of energy expenditure in children with endstage liver disease. *J Pediatr Gastroenterol Nutr* 2003;36:358-363.
24. Nightingale S, Ng VL. Optimizing nutritional management in children with chronic liver disease. *Pediatr Clin North Am* 2009;56:1161-1183.
25. Sultan MI, Leon CD, Biank VF. Role of nutrition in pediatric chronic liver disease. *Nutr Clin Pract* 2011;26:401-408.
26. Carter-Kent C, Radhakrishnan K, Feldstein AE. Increasing calories, decreasing morbidity and mortality: is improved nutrition the answer to better outcomes in patients with biliary atresia? *HEPATOLOGY* 2007;46:1329-1331.
27. DeRusso PA, Ye W, Shepherd R, Haber BA, Shneider BL, Whittington PF, et al. Growth failure and outcomes in infants with biliary atresia: a report from the Biliary Atresia Research Consortium. *HEPATOLOGY* 2007;46:1632-1638.
28. Sokol RJ, Stall C. Anthropometric evaluation of children with chronic liver disease. *Am J Clin Nutr* 1990;52:203-208.
29. Sathe MN, Patel AS. Update in pediatrics: focus on fat-soluble vitamins. *Nutr Clin Pract* 2010;25:340-346.
30. Shneider BL, Magee JC, Bezerra JA, Haber B, Karpen SJ, Raghunathan T, et al. Efficacy of fat-soluble vitamin supplementation in infants with biliary atresia. *Pediatrics* 2012;130:e607-164.
31. Pettei MJ, Daftary S, Levine JJ. Essential fatty acid deficiency associated with the use of a medium-chain-triglyceride infant formula in pediatric hepatobiliary disease. *Am J Clin Nutr* 1991;53:1217-1221.
32. Charlton CP, Buchanan E, Holden CE, Preece MA, Green A, Booth IW, et al. Intensive enteral feeding in advanced cirrhosis: reversal of malnutrition without precipitation of hepatic encephalopathy. *Arch Dis Child* 1992;67:603-607.
33. Holt RI, Miell JP, Jones JS, Mieli-Vergani G, Baker AJ. Nasogastric feeding enhances nutritional status in paediatric liver disease but does not alter circulating levels of IGF-I and IGF binding proteins. *Clin Endocrinol (Oxf)* 2000;52:217-224.
34. Sullivan JS, Sundaram SS, Pan Z, Sokol RJ. Parenteral nutrition supplementation in biliary atresia patients listed for liver transplantation. *Liver Transpl* 2012;18:120-128.
35. Perito ER, Glidden D, Roberts JP, Rosenthal P. Overweight and obesity in pediatric liver transplant recipients: prevalence and predictors before and after transplant, United Network for Organ Sharing Data, 1987-2010. *Pediatr Transpl* 2012;16:41-49.
36. Dick AA, Perkins JD, Spitzer AL, Lao OB, Healey PJ, Reyes JD. Impact of obesity on children undergoing liver transplantation. *Liver Transpl* 2010;16:1296-1302.
37. Pagadala M, Dasarathy S, Egtesad B, McCullough AJ. Posttransplant metabolic syndrome: an epidemic waiting to happen. *Liver Transpl* 2009;15:1662-1670.
38. Rothbaum Perito E, Lau A, Rhee S, Roberts JP, Rosenthal P. Posttransplant metabolic syndrome in children and adolescents after liver transplantation: a systematic review. *Liver Transpl* 2012;18:1009-1028.
39. Madan N, Arnon R. Evaluation of cardiac manifestations in pediatric liver transplant candidates. *Pediatr Transpl* 2012;16:318-328.
40. Desai MS, Zainuer S, Kennedy C, Kearney D, Goss J, Karpen SJ. Cardiac structural and functional alterations in infants and children with biliary atresia, listed for liver transplantation. *Gastroenterology* 2011;141:1264-1272, 72 e1-4.
41. Alves L, Sant'Anna CC, March Mde F, Ferreira S, Marsillac M, Tura M, et al. Preoperative pulmonary assessment of children for liver transplantation. *Pediatr Transpl* 2008;12:536-540.
42. Dehghani SM, Aleyasin S, Honar N, Eshraghian A, Kashef S, Haghighat M, et al. Pulmonary evaluation in pediatric liver transplant candidates. *Indian J Pediatr* 2011;78:171-175.
43. Noli K, Solomon M, Golding F, Charron M, Ling SC. Prevalence of hepatopulmonary syndrome in children. *Pediatrics* 2008;121:e522-527.
44. Arguedas MR, Abrams GA, Krowka MJ, Fallon MB. Prospective evaluation of outcomes and predictors of mortality in patients with hepatopulmonary syndrome undergoing liver transplantation. *HEPATOLOGY* 2003;37:192-197.
45. El-Shabrawi MH, Omran S, Wageeh S, Isa M, Okasha S, Mohsen NA, et al. (99m)Technetium-macroaggregated albumin perfusion lung scan versus contrast enhanced echocardiography in the diagnosis of the hepatopulmonary syndrome in children with chronic liver disease. *Eur J Gastroenterol Hepatol* 2010;22:1006-1012.
46. Condino AA, Ivy DD, O'Connor JA, Narkewicz MR, Mengshol S, Whitworth JR, et al. Portopulmonary hypertension in pediatric patients. *J Pediatr* 2005;147:20-26.
47. Krowka MJ, Swanson KL, Frantz RP, McGoan MD, Wiesner RH. Portopulmonary hypertension: results from a 10-year screening algorithm. *HEPATOLOGY* 2006;44:1502-1510.
48. Hayllar KM, Williams SG, Wise AE, Pouria S, Lombard M, Hodson ME, et al. A prognostic model for the prediction of survival in cystic fibrosis. *Thorax* 1997;52:313-317.
49. Miller MR, Sokol RJ, Narkewicz MR, Sontag MK. Pulmonary function in individuals who underwent liver transplantation: from the US cystic fibrosis foundation registry. *Liver Transpl* 2012;18:585-593.
50. Stevens LA, Coresh J, Greene T, Levey AS. Assessing kidney function—measured and estimated glomerular filtration rate. *N Engl J Med* 2006;354:2473-2483.
51. Schwartz GJ, Munoz A, Schneider MF, Mak RH, Kaskel F, Warady BA, et al. New equations to estimate GFR in children with CKD. *J Am Soc Nephrol* 2009;20:629-637.
52. Samyn M, Cheeseman P, Bevis L, Taylor R, Samaroo B, Buxton-Thomas M, et al. Cystatin C, an easy and reliable marker for assessment of renal dysfunction in children with liver disease and after liver transplantation. *Liver Transpl* 2005;11:344-349.
53. Finney H, Newman DJ, Thakkar H, Fell JM, Price CP. Reference ranges for plasma cystatin C and creatinine measurements in premature infants, neonates, and older children. *Arch Dis Child* 2000;82:71-5.
54. Akcan-Arikan A, Zapitelli M, Loftis LL, Washburn KK, Jefferson LS, Goldstein SL. Modified RIFLE criteria in critically ill children with acute kidney injury. *Kidney Int* 2007;71:1028-1035.
55. Chava SP, Singh B, Pal S, Dhawan A, Heaton ND. Indications for combined liver and kidney transplantation in children. *Pediatr Transpl* 2009;13:661-9.
56. Bartosh SM, Alonso EM, Whittington PF. Renal outcomes in pediatric liver transplantation. *Clin Transplant* 1997;11(5 Pt 1):354-360.
57. Campbell K, Ng V, Martin S, Magee J, Goebel J, Anand R, Martz K, Bucuvalas J, Group SRFW. Glomerular filtration rate following pediatric liver transplantation—the SPLIT experience. *Am J Transpl* 2010;10:2673-2682.

58. Paradis K. Tyrosinemia: the Quebec experience. *Clin Invest Med* 1996; 19:311-316.
59. Berg UB, Ericzon BG, Nemeth A. Renal function before and long after liver transplantation in children. *Transplantation* 2001;72:631-637.
60. Davis ID, Burke B, Freese D, Sharp HL, Kim Y. The pathologic spectrum of the nephropathy associated with alpha 1-antitrypsin deficiency. *Hum Pathol* 1992;23:57-62.
61. Forget S, Patriquin HB, Dubois J, Lafortune M, Merouani A, Paradis K, et al. The kidney in children with tyrosinemia: sonographic, CT and biochemical findings. *Pediatr Radiol* 1999;29:104-108.
62. Kamath BM, Yin W, Miller H, Anand R, Rand EB, Alonso E, et al. Outcomes of liver transplantation for patients with alagille syndrome: The studies of pediatric liver transplantation experience. *Liver Transpl* 2012;18:940-948.
63. Hawwa AF, McKiernan PJ, Shields M, Millership JS, Collier PS, McElnay JC. Influence of ABCB1 polymorphisms and haplotypes on tacrolimus nephrotoxicity and dosage requirements in children with liver transplant. *Br J Clin Pharmacol* 2009;68:413-21.
64. Morisaki I, Abe K, Tong LS, Kato K, Sobue S. Dental findings of children with biliary atresia: report of seven cases. *ASDC J Dent Child* 1990;57:220-223.
65. Seow WK, Shepherd RW, Ong TH. Oral changes associated with end-stage liver disease and liver transplantation: implications for dental management. *ASDC J Dent Child* 1991;58:474-480.
66. Guggenheimer J, Eghtesad B, Close JM, Shay C, Fung JJ. Dental health status of liver transplant candidates. *Liver Transpl* 2007;13:280-286.
67. Shiboski CH, Kawada P, Golinveaux M, Tornabene A, Krishnan S, Mathias R, et al. Oral disease burden and utilization of dental care patterns among pediatric solid organ transplant recipients. *J Public Health Dent* 2009;69:48-55.
68. Yudkowitz FS, Chietero M. Anesthetic issues in pediatric liver transplantation. *Pediatr Transpl* 2005;9:666-72.
69. Uejima T. Anesthetic management of the pediatric patient undergoing solid organ transplantation. *Anesthesiol Clin North Am* 2004;22:809-826.
70. Castaneda-Martinez PD, Alcaide-Ortega RI, Fuentes-Garcia VE, Hernandez-Plata JA, Nieto-Zermeno J, Reyes-Lopez A, et al. Anesthetic risk factors associated with early mortality in pediatric liver transplantation. *Transpl Proc* 2010;42:2383-2386.
71. Walia A, Mandell MS, Mercaldo N, Michaels D, Robertson A, Banerjee A, et al. Anesthesia for liver transplantation in US academic centers: institutional structure and perioperative care. *Liver Transpl* 2012;18:737-743.
72. Campbell AL, Herold BC. Immunization of pediatric solid-organ transplantation candidates: immunizations in transplant candidates. *Pediatr Transpl* 2005;9:652-661.
73. L'Huillier AG, Wildhaber BE, Belli DC, Diana A, Rodriguez M, Siegrist CA, et al. Successful serology-based intervention to increase protection against vaccine-preventable diseases in liver-transplanted children: a 19-yr review of the Swiss national reference center. *Pediatr Transpl* 2012;16:50-57.
74. Keeffe EB. Hepatitis A and B superimposed on chronic liver disease: vaccine-preventable diseases. *Trans Am Clin Climatol Assoc* 2006;117: 227-237; discussion 237-238.
75. Sternfeld T, Spori-Byrtus V, Riediger C, Langer R, Friess H, Schmid RM, et al. Acute measles infection triggering an episode of liver transplant rejection. *Int J Infect Dis* 2010;14:e528-530.
76. Wu JF, Ni YH, Chen HL, Hsu HY, Lai HS, Chang MH. Humoral immunogenicity to measles, rubella, and varicella-zoster vaccines in biliary atresia children. *Vaccine* 2009;27:2812-2815.
77. Kano H, Mizuta K, Sakakihara Y, Kato H, Miki Y, Shibuya N, et al. Efficacy and safety of immunization for pre- and post-liver transplant children. *Transplantation* 2002;74:543-550.
78. Leise MD, Talwalkar JA. Immunizations in chronic liver disease: what should be done and what is the evidence. *Curr Gastroenterol Rep* 2013;15:300.
79. Duchini A, Viernes ME, Nyberg LM, Hendry RM, Pockros PJ. Hepatic decompensation in patients with cirrhosis during infection with influenza A. *Arch Intern Med* 2000;160:113-115.
80. Song JY, Cheong HJ, Ha SH, Hwang IS, Kee SY, Jeong HW, et al. Clinical impact of influenza immunization in patients with liver cirrhosis. *J Clin Virol* 2007;39:159-163.
81. Danzinger-Isakov L, Kumar D, Practice ASTIDCo. Guidelines for vaccination of solid organ transplant candidates and recipients. *Am J Transpl* 2009;9(Suppl 4):S258-262.
82. Rubin LG, Levin MJ, Ljungman P, Davies EG, Avery R, Tomblyn M, et al. 2013 IDSA Clinical Practice Guideline for Vaccination of the Immunocompromised Host. *Clin Infect Dis* 2014;58:309-318.
83. Burroughs M, Moscona A. Immunization of pediatric solid organ transplant candidates and recipients. *Clin Infect Dis* 2000;30:857-869.
84. Nkowane BM, Wassilak SG, Orenstein WA, Bart KJ, Schonberger LB, Hinman AR, et al. Vaccine-associated paralytic poliomyelitis. United States: 1973 through 1984. *JAMA* 1987;257:1335-1340.
85. Allen U, Green M. Prevention and treatment of infectious complications after solid organ transplantation in children. *Pediatr Clin North Am* 2010;57:459-479, table of contents.
86. Narkewicz MR, Green M, Dunn S, Millis M, McDiarmid S, Mazariegos G, et al. Decreasing incidence of symptomatic Epstein-Barr virus disease and posttransplant lymphoproliferative disorder in pediatric liver transplant recipients: report of the studies of pediatric liver transplantation experience. *Liver Transpl* 2013;19:730-740.
87. Kotton CN, Kumar D, Caliendo AM, Asberg A, Chou S, Snyderman DR, et al. International consensus guidelines on the management of cytomegalovirus in solid organ transplantation. *Transplantation* 2010; 89:779-795.
88. Simon NB, Smith D. Living with chronic pediatric liver disease: the parents' experience. *Pediatr Nurs* 1992;18:453-458, 489.
89. Cronin DC, Squires J, Squires R, Mazariegos G, Lantos JD. Parental refusal of a liver transplant for a child with biliary atresia. *Pediatrics* 2013;131:141-146.
90. Hord JD, Rehman W, Hannon P, Anderson-Shaw L, Schmidt ML. Do parents have the right to refuse standard treatment for their child with favorable-prognosis cancer? Ethical and legal concerns. *J Clin Oncol* 2006;24:5454-5456.
91. Kahana SY, Frazier TW, Drotar D. Preliminary quantitative investigation of predictors of treatment non-adherence in pediatric transplantation: a brief report. *Pediatr Transpl* 2008;12:656-660.
92. Lurie S, Shemesh E, Sheiner PA, Emre S, Tindle HL, Melchionna L, et al. Non-adherence in pediatric liver transplant recipients—an assessment of risk factors and natural history. *Pediatr Transpl* 2000;4:200-206.
93. Shaw RJ, Palmer L, Blasey C, Sarwal M. A typology of non-adherence in pediatric renal transplant recipients. *Pediatr Transpl* 2003;7:489-493.
94. Fisher M, Storfer-Isser A, Shaw RJ, Bernard RS, Drury S, Ularntinon S, et al. Inter-rater reliability of the Pediatric Transplant Rating Instrument (P-TRI): challenges to reliably identifying adherence risk factors during pediatric pre-transplant evaluations. *Pediatr Transpl* 2011;15: 142-147.
95. Fung E, Shaw RJ. Pediatric Transplant Rating Instrument — a scale for the pretransplant psychiatric evaluation of pediatric organ transplant recipients. *Pediatr Transpl* 2008;12:57-66.
96. Shaw RJ, Taussig HN. Pediatric psychiatric pretransplant evaluation. *Clin Child Psychol Psychiatry* 1999;4:352-365.
97. Alonso EM, Sorensen LG. Cognitive development following pediatric solid organ transplantation. *Curr Opin Organ Transpl* 2009;14:522-525.
98. Kaller T, Schulz KH, Sander K, Boeck A, Rogiers X, Burdelski M. Cognitive abilities in children after liver transplantation. *Transplantation* 2005;79:1252-1256.
99. Sorensen LG, Neighbors K, Martz K, Zelko F, Bucuvalas JC, Alonso EM. Cognitive and academic outcomes after pediatric liver transplantation: Functional Outcomes Group (FOG) results. *Am J Transpl* 2011; 11:303-311.

100. Krull K, Fuchs C, Yurk H, Boone P, Alonso E. Neurocognitive outcome in pediatric liver transplant recipients. *Pediatr Transpl* 2003;7:111-118.
101. Thevenin DM, Baker A, Kato T, Tzakis A, Fernandez M, Dowling M. Neurodevelopmental outcomes of infant multivisceral transplant recipients: a longitudinal study. *Transpl Proc* 2006;38:1694-1695.
102. Schulz KH, Wein C, Boeck A, Rogiers X, Burdelski M. Cognitive performance of children who have undergone liver transplantation. *Transplantation* 2003;75:1236-1240.
103. Wayman KI, Cox KL, Esquivel CO. Neurodevelopmental outcome of young children with extrahepatic biliary atresia 1 year after liver transplantation. *J Pediatr* 1997;131:894-898.
104. Caudle SE, Katzenstein JM, Karpen S, McLin V. Developmental assessment of infants with biliary atresia: differences between boys and girls. *J Pediatr Gastroenter Nutr* 2012;55:384-389.
105. Caudle SE, Katzenstein JM, Karpen SJ, McLin VA. Language and motor skills are impaired in infants with biliary atresia before transplantation. *J Pediatr* 2010;156:936-940, 40 e1.
106. Richards CT, Crawley LM, Magnus D. Use of neurodevelopmental delay in pediatric solid organ transplant listing decisions: inconsistencies in standards across major pediatric transplant centers. *Pediatr Transpl* 2009;13:843-850.
107. Ohta T, Motoyama O, Takahashi K, Hattori M, Shishido S, Wada N, et al. Kidney transplantation in pediatric recipients with mental retardation: clinical results of a multicenter experience in Japan. *Am J Kidney Dis* 2006;47:518-257.
108. Lacaillie F, Sokal E. Living-related liver transplantation. *J Pediatr Gastroenter Nutr* 2001;33:431-438.
109. Emre S. Living-donor liver transplantation in children. *Pediatr Transpl* 2002;6:43-46.
110. Jean-Bernard O. Good Samaritan liver donor in *Pediatr Transpl* 2009;13:155-159.
111. Wright L, Ross K, Abbey S, Levy G, Grant D. Living anonymous liver donation: case report and ethical justification. *Am J Transpl* 2007;7:1032-1035.
112. Goldman LS. Liver transplantation using living donors. Preliminary donor psychiatric outcomes. *Psychosomatics* 1993;34:235-240.
113. Mack CL, Ferrario M, Abecassis M, Whittington PF, Superina RA, Alonso EM. Living donor liver transplantation for children with liver failure and concurrent multiple organ system failure. *Liver Transpl* 2001;7:890-895.
114. Morioka D, Kasahara M, Takada Y, Corrales JP, Yoshizawa A, Sakamoto S, et al. Living donor liver transplantation for pediatric patients with inheritable metabolic disorders. *Am J Transpl* 2005;5:2754-2763.
115. Ozcay F, Alehan F, Sevmis S, Karakayali H, Moray G, Torgay A, et al. Living related liver transplantation in Crigler-Najjar syndrome type 1. *Transpl Proc* 2009;41:2875-2877.
116. El-Karaksy H, Nomachi S, Esmat G, El-Serafy M, Kamel RR, El-Ansary A, et al. Equal outcome of living-related liver transplantation for Wilson's disease from heterozygote and nonheterozygote donors: a report of a brother and sister. *Indian J Med Sci* 2007;61:286-288.
117. Ishida T, Hiroma T, Hashikura Y, Horiuchi M, Kobayashi K, Nakamura T. Early neonatal onset carbamoyl-phosphate synthase 1 deficiency treated with continuous hemodiafiltration and early living-related liver transplantation. *Pediatr Int* 2009;51:409-410.
118. Yorifuji T, Kawai M, Mamada M, Kurokawa K, Egawa H, Shigematsu Y, et al. Living-donor liver transplantation for propionic acidemia. *J Inher Metabol Dis* 2004;27:205-210.
119. Marble M, McGoey RR, Mannick E, Keats B, Ng SS, Deputy S, et al. Living related liver transplant in a patient with argininosuccinic aciduria and cirrhosis: metabolic follow-up. *J Pediatr Gastroenter Nutr* 2008;46:453-456.
120. Cutillo L, Najimi M, Smets F, Janssen M, Reding R, de Ville de Goyet J, et al. Safety of living-related liver transplantation for progressive familial intrahepatic cholestasis. *Pediatr Transpl* 2006;10:570-574.
121. Tannuri AC, Gibelli NE, Ricardi LR, Santos MM, Maksoud-Filho JG, Pinho-Apezato ML, et al. Living related donor liver transplantation in children. *Transpl Proc* 2011;43:161-164.
122. Kasahara M, Kiuchi T, Inomata Y, Uryuhara K, Sakamoto S, Ito T, et al. Living-related liver transplantation for Alagille syndrome. *Transplantation* 2003;75:2147-2150.
123. Hartley JL, Davenport M, Kelly DA. Biliary atresia. *Lancet* 2009;374:1704-1713.
124. Petersen C, Harder D, Abola Z, Alberti D, Becker T, Chardot C, et al. European biliary atresia registries: summary of a symposium. *Eur J Pediatr Surg* 2008;18:111-116.
125. Davenport M, Puricelli V, Farrant P, Hadzic N, Mieli-Vergani G, Portmann B, et al. The outcome of the older (> or =100 days) infant with biliary atresia. *J Pediatr Surg* 2004;39:575-581.
126. Sokol RJ, Shepherd RW, Superina R, Bezerra JA, Robuck P, Hoofnagle JH. Screening and outcomes in biliary atresia: summary of a National Institutes of Health workshop. *HEPATOLOGY* 2007;46:566-581.
127. Davenport M, Tizzard SA, Underhill J, Mieli-Vergani G, Portmann B, Hadzic N. The biliary atresia splenic malformation syndrome: a 28-year single-center retrospective study. *J Pediatr* 2006;149:393-400.
128. Shneider BL, Brown MB, Haber B, Whittington PF, Schwarz K, Squires R, et al. A multicenter study of the outcome of biliary atresia in the United States, 1997 to 2000. *J Pediatr* 2006;148:467-474.
129. Davenport M, Caponcelli E, Livesey E, Hadzic N, Howard E. Surgical outcome in biliary atresia: etiology affects the influence of age at surgery. *Ann Surg* 2008;247:694-698.
130. Lee H, Lewis J, Schoen BT, Brand T, Ricketts RR. Kasai portoenterostomy: differences related to race. *J Pediatr Surg* 2001;36:1196-1198.
131. Schoen BT, Lee H, Sullivan K, Ricketts RR. The Kasai portoenterostomy: when is it too late? *J Pediatr Surg* 2001;36:97-99.
132. de Vries W, Homan-Van der Veen J, Hulscher JB, Hoekstra-Weebers JE, Houwen RH, Verkade HJ, Netherlands Study Group of Biliary Atresia R. Twenty-year transplant-free survival rate among patients with biliary atresia. *Clin Gastroenterol Hepatol* 2011;9:1086-1091.
133. Jimenez-Rivera C, Jolin-Dahel KS, Fortinsky KJ, Gozdyra P, Benchimol EI. International incidence and outcomes of biliary atresia. *J Pediatr Gastroenter Nutr* 2013;56:344-354.
134. Davenport M, Ure BM, Petersen C, Kobayashi H. Surgery for biliary atresia—is there a European consensus? *Eur J Pediatr Surg* 2007;17:180-183.
135. Kotb MA. Review of historical cohort: ursodeoxycholic acid in extrahepatic biliary atresia. *J Pediatr Surg* 2008;43:1321-1327.
136. Sarkhy A, Schreiber RA, Milner RA, Barker CC. Does adjuvant steroid therapy post-Kasai portoenterostomy improve outcome of biliary atresia? Systematic review and meta-analysis. *Can J Gastroenterol* 2011;25:440-444.
137. Bu LN, Chen HL, Chang CJ, Ni YH, Hsu HY, Lai HS, Hsu WM, Chang MH. Prophylactic oral antibiotics in prevention of recurrent cholangitis after the Kasai portoenterostomy. *J Pediatr Surg* 2003;38:590-593.
138. Luo Y, Zheng S. Current concept about postoperative cholangitis in biliary atresia. *World J Pediatr* 2008;4:14-19.
139. Bezerra JA, Spino C, Magee JC, Shneider BL, Rosenthal P, Wang KS, et al. High-dose corticosteroid therapy following portoenterostomy in infants with biliary atresia does not improve outcome: the multicenter, randomized, double-blind, placebo-controlled START Trial. *HEPATOLOGY* 2013;58:263A.
140. Utterson EC, Shepherd RW, Sokol RJ, Bucuvalas J, Magee JC, McDiarmid SV, et al. Biliary atresia: clinical profiles, risk factors, and outcomes of 755 patients listed for liver transplantation. *J Pediatr* 2005;147:180-185.
141. Barshes NR, Chang IF, Karpen SJ, Carter BA, Goss JA. Impact of pretransplant growth retardation in pediatric liver transplantation. *J Pediatr Gastroenter Nutr* 2006;43:89-94.

142. Brunati A, Feruzi Z, Sokal E, Smets F, Fervaille C, Gosseye S, et al. Early occurrence of hepatocellular carcinoma in biliary atresia treated by liver transplantation. *Pediatr Transpl* 2007;11:117-119.
143. Kim JM, Lee SK, Kwon CH, Joh JW, Choe YH, Park CK. Hepatocellular carcinoma in an infant with biliary atresia younger than 1 year. *J Pediatr Surg* 2012;47:819-821.
144. Romano F, Stroppa P, Bravi M, Casotti V, Lucianetti A, Guizzetti M, et al. Favorable outcome of primary liver transplantation in children with cirrhosis and hepatocellular carcinoma. *Pediatr Transpl* 2011;15:573-579.
145. Inoue Y, Kato Y, Tamura T, Kobayashi H, Ichikawa S, Lane GJ, et al. Prognostic implications of bile lakes after surgery for biliary atresia. *J Pediatr Surg* 2008;43:2165-2168.
146. Barshes NR, Lee TC, Balkrishnan R, Karpen SJ, Carter BA, Goss JA. Orthotopic liver transplantation for biliary atresia: the U.S. experience. *Liver Transpl* 2005;11:1193-1200.
147. Alagille D, Estrada A, Hadchouel M, Gautier M, Odievre M, Dommargues JP. Syndromic paucity of interlobular bile ducts (Alagille syndrome or arteriohepatic dysplasia): review of 80 cases. *J Pediatr* 1987;110:195-200.
148. Li L, Krantz ID, Deng Y, Genin A, Banta AB, Collins CC, et al. Alagille syndrome is caused by mutations in human Jagged1, which encodes a ligand for Notch1. *Nat Genet* 1997;16:243-251.
149. Oda T, Elkahloun AG, Pike BL, Okajima K, Krantz ID, Genin A, et al. Mutations in the human Jagged1 gene are responsible for Alagille syndrome. *Nat Genet* 1997;16:235-242.
150. Watson GH, Miller V. Arteriohepatic dysplasia: familial pulmonary arterial stenosis with neonatal liver disease. *Arch Dis Child* 1973;48:459-466.
151. Kamath BM, Schwarz KB, Hadzic N. Alagille syndrome and liver transplantation. *J Pediatr Gastroenter Nutr* 2010;50:11-15.
152. Emerick KM, Rand EB, Goldmuntz E, Krantz ID, Spinner NB, Piccoli DA. Features of Alagille syndrome in 92 patients: frequency and relation to prognosis. *HEPATOLOGY* 1999;29:822-829.
153. Hoffenberg EJ, Narkewicz MR, Sondheimer JM, Smith DJ, Silverman A, Sokol RJ. Outcome of syndromic paucity of interlobular bile ducts (Alagille syndrome) with onset of cholestasis in infancy. *J Pediatr* 1995;127:220-224.
154. Quiros-Tejeira RE, Ament ME, Heyman MB, Martin MG, Rosenthal P, Hall TR, et al. Variable morbidity in alagille syndrome: a review of 43 cases. *J Pediatr Gastroenter Nutr* 1999;29:431-437.
155. Lykavieris P, Hadchouel M, Chardot C, Bernard O. Outcome of liver disease in children with Alagille syndrome: a study of 163 patients. *Gut* 2001;49:431-435.
156. Englert C, Grabhorn E, Burdelski M, Ganschow R. Liver transplantation in children with Alagille syndrome: indications and outcome. *Pediatr Transpl* 2006;10:154-158.
157. Ovaert C, Germeau C, Barrea C, Moniotte S, Van Obbergh L, Sokal E, et al. Elevated right ventricular pressures are not a contraindication to liver transplantation in Alagille syndrome. *Transplantation* 2001;72:345-347.
158. Sheflin-Findling S, Arnon R, Lee S, Chu J, Henderling F, Kerkar N, et al. Partial internal biliary diversion for Alagille syndrome: case report and review of the literature. *J Pediatr Surg* 2012;47:1453-1456.
159. Yang H, Porte RJ, Verkade HJ, De Langen ZJ, Hulscher JB. Partial external biliary diversion in children with progressive familial intrahepatic cholestasis and Alagille disease. *J Pediatr Gastroenter Nutr* 2009;49:216-221.
160. Modi BP, Suh MY, Jonas MM, Lillehei C, Kim HB. Ileal exclusion for refractory symptomatic cholestasis in Alagille syndrome. *J Pediatr Surg* 2007;42:800-805.
161. Kamath BM, Loomes KM, Piccoli DA. Medical management of Alagille syndrome. *J Pediatr Gastroenter Nutr* 2010;50:580-586.
162. Kamath BM, Spinner NB, Emerick KM, Chudley AE, Booth C, Piccoli DA, et al. Vascular anomalies in Alagille syndrome: a significant cause of morbidity and mortality. *Circulation* 2004;109:1354-1358.
163. Razavi RS, Baker A, Qureshi SA, Rosenthal E, Marsh MJ, Leech SC, et al. Hemodynamic response to continuous infusion of dobutamine in Alagille's syndrome. *Transplantation* 2001;72:823-828.
164. Arnon R, Annunziato R, Miloh T, Suchy F, Sakworawich A, Sogawa H, et al. Orthotopic liver transplantation for children with Alagille syndrome. *Pediatr Transpl* 2010;14:622-628.
165. Hori T, Egawa H, Takada Y, Oike F, Kasahara M, Ogura Y, et al. Harambat J, Ranchin B, Dubourg L, Liutkus A, Hadj-Haissa A, Rivet C, Boillot O, Lachaux A, Cochat P. Renal function in pediatric liver transplantation: a long-term follow-up study. *Transplantation* 2008;86:1028-1034.
166. Roberts EA, Schilsky ML, American Association for Study of Liver D. Diagnosis and treatment of Wilson disease: an update. *HEPATOLOGY* 2008;47:2089-2111.
167. Verma N, Pai G, Hari P, Lodha R. Plasma exchange for hemolytic crisis and acute liver failure in Wilson disease. *Indian J Pediatr* 2013 [Epub ahead of print].
168. Squires RH Jr, Shneider BL, Bucuvalas J, Alonso E, Sokol RJ, Narkewicz MR, et al. Acute liver failure in children: the first 348 patients in the pediatric acute liver failure study group. *J Pediatr* 2006;148:652-658.
169. Squires RH, Dhawan A, Alonso E, Narkewicz MR, Shneider BL, Rodriguez-Baez N, et al. Intravenous N-acetylcysteine in pediatric patients with non-acetaminophen acute liver failure: a placebo-controlled clinical trial. *HEPATOLOGY* 2013;57:1542-1549.
170. Lee WS, McKiernan P, Kelly DA. Etiology, outcome and prognostic indicators of childhood fulminant hepatic failure in the United Kingdom. *J Pediatr Gastroenter Nutr* 2005;40:575-581.
171. Navaneethan U, Lancaster E, Venkatesh PG, Wang J, Neff GW. Herpes simplex virus hepatitis — it's high time we consider empiric treatment. *J Gastrointest Liver Dis* 2011;20:93-96.
172. Rand EB, Karpen SJ, Kelly S, Mack CL, Malatack JJ, Sokol RJ, et al. Treatment of neonatal hemochromatosis with exchange transfusion and intravenous immunoglobulin. *J Pediatr* 2009;155:566-571.
173. Gregorio GV, Portmann B, Reid F, Donaldson PT, Doherty DG, McCartney M, et al. Autoimmune hepatitis in childhood: a 20-year experience. *HEPATOLOGY* 1997;25:541-547.
174. Lee WM, Squires RH Jr, Nyberg SL, Doo E, Hoofnagle JH. Acute liver failure: summary of a workshop. *HEPATOLOGY* 2008;47:1401-1415.
175. Durand F, Bernuau J, Giostra E, Mentha G, Shouval D, Degott C, et al. Wilson's disease with severe hepatic insufficiency: beneficial effects of early administration of D-penicillamine. *Gut* 2001;48:849-852.
176. Narkewicz MR, Dell Olio D, Karpen SJ, Murray KF, Schwarz K, Yazigi N, et al. Pattern of diagnostic evaluation for the causes of pediatric acute liver failure: an opportunity for quality improvement. *J Pediatr* 2009;155:801-806 e1.
177. Lu BR, Zhang S, Narkewicz MR, Belle SH, Squires RH, Sokol RJ. Evaluation of the liver injury unit scoring system to predict survival in a multinational study of pediatric acute liver failure. *J Pediatr* 2013;162:1010-1016.
178. Sundaram V, Shneider BL, Dhawan A, Ng VL, Im K, Belle S, Squires RH. King's College Hospital Criteria for non-acetaminophen induced acute liver failure in an international cohort of children. *J Pediatr* 2013;162:319-323 e1.
179. Mindikoglu AL, King D, Magder LS, Ozolek JA, Mazariegos GV, Shneider BL. Valproic acid-associated acute liver failure in children: case report and analysis of liver transplantation outcomes in the United States. *J Pediatr* 2011;158:802-807.
180. Ryu JM, Kim KM, Oh SH, Koh KN, Im HJ, Park CJ, Chi HS, Seo JJ. Differential clinical characteristics of acute liver failure caused by hemophagocytic lymphohistiocytosis in children. *Pediatr Int* 2013;55:748-752.
181. Hery G, Franchi-Abella S, Habes D, Brugieres L, Martelli H, Fabre M, et al. Initial liver transplantation for unresectable hepatoblastoma after chemotherapy. *Pediatr Blood Canc* 2011;57:1270-1275.

182. Malogolowkin MH, Katzenstein HM, Krailo M, Meyers RL. Treatment of hepatoblastoma: the North American cooperative group experience. *Front Biosci (Elite Ed)* 2012;4:1717-1723.
183. Otte JB, Pritchard J, Aronson DC, Brown J, Czuderna P, Maibach R, et al. Liver transplantation for hepatoblastoma: results from the International Society of Pediatric Oncology (SIOP) study SIOPEL-1 and review of the world experience. *Pediatr Blood Cancer* 2004;42:74-83.
184. Aronson DC, Schnater JM, Staalman CR, Weverling GJ, Plaschkes J, Perilongo G, et al. Predictive value of the pretreatment extent of disease system in hepatoblastoma: results from the International Society of Pediatric Oncology Liver Tumor Study Group SIOPEL-1 study. *J Clin Oncol* 2005;23:1245-1252.
185. Gupta AA, Gerstle JT, Ng V, Wong A, Fecteau A, Malogolowkin MH, et al. Critical review of controversial issues in the management of advanced pediatric liver tumors. *Pediatr Blood Cancer* 2011;56:1013-1018.
186. Lautz TB, Ben-Ami T, Tantemsapya N, Gosiengfiao Y, Superina RA. Successful nontransplant resection of POST-TEXT III and IV hepatoblastoma. *Cancer* 2011;117:1976-1983.
187. Austin MT, Leys CM, Feurer ID, Lovvorn HN 3rd, O'Neill JA Jr, Pinson CW, et al. Liver transplantation for childhood hepatic malignancy: a review of the United Network for Organ Sharing (UNOS) database. *J Pediatr Surg* 2006;41:182-186.
188. Ismail H, Broniszczak D, Kalicinski P, Dembowska-Baginska B, Perek D, Teisseyre J, et al. Changing treatment and outcome of children with hepatoblastoma: analysis of a single center experience over the last 20 years. *J Pediatr Surg* 2012;47:1331-1339.
189. Kosola S, Lauronen J, Sairanen H, Heikinheimo M, Jalanko H, Pakarinen M. High survival rates after liver transplantation for hepatoblastoma and hepatocellular carcinoma. *Pediatr Transpl* 2010;14:646-650.
190. Meyers RL, Tiao GM, Dunn SP, Langham MR Jr. Liver transplantation in the management of unresectable hepatoblastoma in children. *Front Biosci (Elite Ed)* 2012;4:1293-1302.
191. Wen WH, Chang MH, Hsu HY, Ni YH, Chen HL. The development of hepatocellular carcinoma among prospectively followed children with chronic hepatitis B virus infection. *J Pediatr* 2004;144:397-399.
192. Ismail H, Broniszczak D, Kalicinski P, Markiewicz-Kijewska M, Teisseyre J, Stefanowicz M, et al. Liver transplantation in children with hepatocellular carcinoma. Do Milan criteria apply to pediatric patients? *Pediatr Transpl* 2009;13:682-692.
193. Yu SB, Kim HY, Eo H, Won JK, Jung SE, Park KW, et al. Clinical characteristics and prognosis of pediatric hepatocellular carcinoma. *World J Surg* 2006;30:43-50.
194. Malek MM, Shah SR, Atri P, Paredes JL, DiCicco LA, Sindhi R, et al. Review of outcomes of primary liver cancers in children: our institutional experience with resection and transplantation. *Surgery* 2010;148:778-782; discussion 82-84.
195. Spangenberg HC, Thimme R, Blum HE. Serum markers of hepatocellular carcinoma. *Semin Liver Dis* 2006;26:385-390.
196. Mazzaferro V, Bhoori S, Sposito C, Bongini M, Langer M, Miceli R, et al. Milan criteria in liver transplantation for hepatocellular carcinoma: an evidence-based analysis of 15 years of experience. *Liver Transpl* 2011;17(Suppl 2):S44-57.
197. Beauvoys M, Vanatta JM, Ogihara M, Strichartz D, Dahl G, Berquist WE, et al. Outcomes of transplantation in children with primary hepatic malignancy. *Pediatr Transpl* 2007;11:655-660.
198. Christison-Lagay ER, Burrows PE, Alomari A, Dubois J, Kozakewich HP, Lane TS, et al. Hepatic hemangiomas: subtype classification and development of a clinical practice algorithm and registry. *J Pediatr Surg* 2007;42:62-67; discussion 7-8.
199. Kulungowski AM, Alomari AI, Chawla A, Christison-Lagay ER, Fishman SJ. Lessons from a liver hemangioma registry: subtype classification. *J Pediatr Surg* 2012;47:165-170.
200. Huang SA, Tu HM, Harney JW, Venihaki M, Butte AJ, Kozakewich HP, et al. Severe hypothyroidism caused by type 3 iodothyronine deiodinase in infantile hemangiomas. *N Engl J Med* 2000;343:185-189.
201. Kuroda T, Kumagai M, Nosaka S, Nakazawa A, Takimoto T, Hoshino K, et al. Critical infantile hepatic hemangioma: results of a nationwide survey by the Japanese Infantile Hepatic Hemangioma Study Group. *J Pediatr Surg* 2011;46:2239-2243.
202. Taki M, Ohi C, Yamashita A, Kobayashi M, Kobayashi N, Yoda T, et al. Successful treatment with vincristine of an infant with intractable Kasabach-Merritt syndrome. *Pediatr Int* 2006;48:82-84.
203. Hu B, Lachman R, Phillips J, Peng SK, Sieger L. Kasabach-Merritt syndrome associated kaposiform hemangio-endothelioma successfully treated with cyclophosphamide, vincristine, and actinomycin D. *J Pediatr Hematol Oncol* 1998;20:567-569.
204. Debray D, Kelly D, Houwen R, Strandvik B, Colombo C. Best practice guidance for the diagnosis and management of cystic fibrosis-associated liver disease. *J Cystic Fibrosis* 2011;10(Suppl 2):S29-36.
205. Colombo C, Battezzati PM, Crosignani A, Morabito A, Costantini D, Padoan R, et al. Liver disease in cystic fibrosis: A prospective study on incidence, risk factors, and outcome. *HEPATOLOGY* 2002;36:1374-1382.
206. Sokol RJ, Durie PR. Recommendations for management of liver and biliary tract disease in cystic fibrosis. Cystic Fibrosis Foundation Hepatobiliary Disease Consensus Group. *J Pediatr Gastroenter Nutr* 1999;28(Suppl 1):S1-13.
207. Colombo C, Crosignani A, Assaïso M, Battezzati PM, Podda M, Giunta A, et al. Ursodeoxycholic acid therapy in cystic fibrosis-associated liver disease: a dose-response study. *HEPATOLOGY* 1992;16:924-930.
208. Colombo C, Battezzati PM, Podda M, Bertinardi N, Giunta A. Ursodeoxycholic acid for liver disease associated with cystic fibrosis: a double-blind multicenter trial. The Italian Group for the Study of Ursodeoxycholic Acid in Cystic Fibrosis. *HEPATOLOGY* 1996;23:1484-1490.
209. Bhardwaj S, Canlas K, Kahi C, Temkit M, Molleston J, Ober M, et al. Hepatobiliary abnormalities and disease in cystic fibrosis: epidemiology and outcomes through adulthood. *J Clin Gastroenterol* 2009;43:858-864.
210. Gooding I, Dondos V, Gyi KM, Hodson M, Westaby D. Variceal hemorrhage and cystic fibrosis: outcomes and implications for liver transplantation. *Liver Transpl* 2005;11:1522-1526.
211. Molmenti EP, Squires RH, Nagata D, Roden JS, Molmenti H, Fasola CG, et al. Liver transplantation for cholestasis associated with cystic fibrosis in the pediatric population. *Pediatr Transpl* 2003;7:93-97.
212. Horslen S, Sweet S, Gish RG, Shepherd R. Model for endstage liver disease (MELD) exception for cystic fibrosis. *Liver Transpl* 2006;12(12 Suppl 3):S98-99.
213. Gridelli B. Liver: Benefit of liver transplantation in patients with cystic fibrosis. *Nat Rev Gastroenterol Hepatol* 2011;8:187-188.
214. Mendizabal M, Reddy KR, Cassuto J, Olthoff KM, Faust TW, Makar GA, et al. Liver transplantation in patients with cystic fibrosis: analysis of United Network for Organ Sharing data. *Liver Transpl* 2011;17:243-250.
215. Arnon R, Annunziato RA, Miloh T, Padilla M, Sogawa H, Batemarco L, et al. Liver and combined lung and liver transplantation for cystic fibrosis: analysis of the UNOS database. *Pediatr Transpl* 2011;15:254-624.
216. Fridell JA, Bond GJ, Mazariegos GV, Orenstein DM, Jain A, Sindhi R, et al. Liver transplantation in children with cystic fibrosis: a long-term longitudinal review of a single center's experience. *J Pediatr Surg* 2003;38:1152-1156.
217. Colombo C, Costantini D, Rocchi A, Romano G, Rossi G, Bianchi ML, et al. Effects of liver transplantation on the nutritional status of patients with cystic fibrosis. *Transpl Int* 2005;18:246-255.
218. Dowman JK, Watson D, Loganathan S, Gunson BK, Hodson J, Mirza DF, et al. Long-term impact of liver transplantation on respiratory function and nutritional status in children and adults with cystic fibrosis. *Am J Transpl* 2012;12:954-964.
219. Kuo HT, Lau C, Sampaio MS, Bunnapradist S. Pretransplant risk factors for new-onset diabetes mellitus after transplant in pediatric liver transplant recipients. *Liver Transpl* 2010;16:1249-1256.

220. Lefaucheur C, Nochy D, Amrein C, Chevalier P, Guillemin R, Cherif M, et al. Renal histopathological lesions after lung transplantation in patients with cystic fibrosis. *Am J Transpl* 2008;8:1901-1910.
221. Nash EF, Volling C, Gutierrez CA, Tullis E, Coonar A, McRae K, et al. Outcomes of patients with cystic fibrosis undergoing lung transplantation with and without cystic fibrosis-associated liver cirrhosis. *Clin Transpl* 2012;26:34-41.
222. Nash KL, Collier JD, French J, McKeon D, Gimson AE, Jamieson NV, et al. Cystic fibrosis liver disease: to transplant or not to transplant? *Am J Transpl* 2008;8:162-169.
223. Haberle J, Boddaert N, Burlina A, Chakrapani A, Dixon M, Huemer M, et al. Suggested guidelines for the diagnosis and management of urea cycle disorders. *Orphanet J Rare Dis* 2012;7:32.
224. Brusilow SW, Maestri NE. Urea cycle disorders: diagnosis, pathophysiology, and therapy. *Advances in pediatrics*. 1996;43:127-170.
225. Wilcken B. Problems in the management of urea cycle disorders. *Mol Genet Metab* 2004;81(Suppl 1):S86-91.
226. McBride KL, Miller G, Carter S, Karpen S, Goss J, Lee B. Developmental outcomes with early orthotopic liver transplantation for infants with neonatal-onset urea cycle defects and a female patient with late-onset ornithine transcarbamylase deficiency. *Pediatrics* 2004;114:e523-526.
227. Bourdeaux C, Darwish A, Jamart J, Tri TT, Janssen M, Lerut J, et al. Living-related versus deceased donor pediatric liver transplantation: a multivariate analysis of technical and immunological complications in 235 recipients. *Am J Transpl* 2007;7:440-447.
228. Morioka D, Kasahara M, Takada Y, Shirouzu Y, Taira K, Sakamoto S, et al. Current role of liver transplantation for the treatment of urea cycle disorders: a review of the worldwide English literature and 13 cases at Kyoto University. *Liver Transpl* 2005;11:1332-1342.
229. Campeau PM, Pivalizza PJ, Miller G, McBride K, Karpen S, Goss J, et al. Early orthotopic liver transplantation in urea cycle defects: follow up of a developmental outcome study. *Mol Genet Metab* 2010;100(Suppl 1):S84-87.
230. Leonard JV, McKiernan PJ. The role of liver transplantation in urea cycle disorders. *Mol Genet Metab* 2004;81(Suppl 1):S74-78.
231. Morioka D, Takada Y, Kasahara M, Ito T, Uryuhara K, Ogawa K, et al. Living donor liver transplantation for noncirrhotic inheritable metabolic liver diseases: impact of the use of heterozygous donors. *Transplantation* 2005;80:623-628.
232. Wakiya T, Sanada Y, Urahashi T, Ihara Y, Yamada N, Okada N, et al. Living donor liver transplantation from an asymptomatic mother who was a carrier for ornithine transcarbamylase deficiency. *Pediatr Transpl* 2012;16:E196-200.
233. Jansen PL. Diagnosis and management of Crigler-Najjar syndrome. *Eur J Pediatr* 1999;158(Suppl 20):S89-94.
234. O'Reilly C, Dixon R. Crigler-Najjar syndrome: treatment at home with phototherapy. *Scott Med J*. 1988;33:335-336.
235. Strauss KA, Robinson DL, Vreman HJ, Puffenberger EG, Hart G, Morton DH. Management of hyperbilirubinemia and prevention of kernicterus in 20 patients with Crigler-Najjar disease. *Eur J Pediatr* 2006;165:306-319.
236. Mowat AP. Liver disorders in children: the indications for liver replacement in parenchymal and metabolic diseases. *Transplant Proc* 1987;19:3236-3241.
237. van der Veere CN, Sinaasappel M, McDonagh AF, Rosenthal P, Labrune P, Odievre M, et al. Current therapy for Crigler-Najjar syndrome type I: report of a world registry. *HEPATOLOGY* 1996;24:311-315.
238. Mieli-Vergani G, Vergani D. Autoimmune hepatitis in children: what is different from adult AIH? *Semin Liver Dis* 2009;29:297-306.
239. Gregorio GV, Portmann B, Karani J, Harrison P, Donaldson PT, Vergani D, et al. Autoimmune hepatitis/sclerosing cholangitis overlap syndrome in childhood: a 16-year prospective study. *HEPATOLOGY* 2001;33:544-553.
240. Mieli-Vergani G, Heller S, Jara P, Vergani D, Chang MH, Fujisawa T, et al. Autoimmune hepatitis. *J Pediatr Gastroenter Nutr* 2009;49:158-164.
241. Martin SR, Alvarez F, Anand R, Song C, Yin W. Outcomes in children who underwent transplantation for autoimmune hepatitis. *Liver Transpl* 2011;17:393-401.
242. Schramm C, Bubenheim M, Adam R, Karam V, Buckels J, O'Grady JG, et al. Primary liver transplantation for autoimmune hepatitis: a comparative analysis of the European Liver Transplant Registry. *Liver Transpl* 2010;16:461-469.
243. Heffron TG, Smallwood GA, Oakley B, Pillen T, Welch D, Connor K, et al. Adult and pediatric liver transplantation for autoimmune hepatitis. *Transpl Proc* 2003;35:1435-1436.
244. Czaja AJ. Autoimmune hepatitis after liver transplantation and other lessons of self-intolerance. *Liver Transpl* 2002;8:505-513.
245. Molmenti EP, Netto GJ, Murray NG, Smith DM, Molmenti H, Crippin JS, et al. Incidence and recurrence of autoimmune/allimmune hepatitis in liver transplant recipients. *Liver Transpl* 2002;8:519-526.
246. Mieli-Vergani G, Vergani D. Autoimmune paediatric liver disease. *World J Gastroenterol* 2008;14:3360-3367.
247. Liberal R, Grant CR, Mieli-Vergani G, Vergani D. Autoimmune hepatitis: a comprehensive review. *J Autoimmun* 2013;41:126-139.
248. Boberg KM, Chapman RW, Hirschfield GM, Lohse AW, Manns MP, Schrupf E, International Autoimmune Hepatitis G. Overlap syndromes: the International Autoimmune Hepatitis Group (IAIHG) position statement on a controversial issue. *J Hepatol* 2011;54:374-385.
249. LaRusso NF, Shneider BL, Black D, Gores GJ, James SP, Doo E, et al. Primary sclerosing cholangitis: summary of a workshop. *HEPATOLOGY* 2006;44:746-764.
250. Manns MP. Immunoglobulin G4-associated cholangitis: dominating immunoglobulin G4-positive clones within the B-cell receptor repertoire indicate light at the end of a long tunnel. *HEPATOLOGY* 2013;57:2110-2113.
251. Umemura T, Zen Y, Hamano H, Kawa S, Nakanuma Y, Kiyosawa K. Immunoglobulin G4-hepatopathy: association of immunoglobulin G4-bearing plasma cells in liver with autoimmune pancreatitis. *HEPATOLOGY* 2007;46:463-471.
252. Ibrahim SH, Zhang L, Freese DK. A 3-year-old with immunoglobulin G4-associated cholangitis. *J Pediatr Gastroenterol Nutr* 2011;53:109-111.
253. Miloh T, Anand R, Yin W, Vos M, Kerker N, Alonso E. Pediatric liver transplantation for primary sclerosing cholangitis. *Liver Transpl* 2011;17:925-933.
254. Bjornsson E, Angulo P. Cholangiocarcinoma in young individuals with and without primary sclerosing cholangitis. *Am J Gastroenterol* 2007;102:1677-1682.
255. McDiarmid SV, Anand R. Studies of Pediatric Liver Transplantation (SPLIT): a summary of the 2003 Annual Report. *Clin Transpl* 2003:119-130.
256. Chapman R, Fevery J, Kalloo A, Nagorney DM, Boberg KM, Shneider B, et al. Diagnosis and management of primary sclerosing cholangitis. *HEPATOLOGY* 2010;51:660-678.
257. Bambha K, Kim WR, Talwalkar J, Torgerson H, Benson JT, Therneau TM, et al. Incidence, clinical spectrum, and outcomes of primary sclerosing cholangitis in a United States community. *Gastroenterology*. 2003;125:1364-1369.
258. Chai PF, Lee WS, Brown RM, McPartland JL, Foster K, McKiernan PJ, et al. Childhood autoimmune liver disease: indications and outcome of liver transplantation. *J Pediatr Gastroenter Nutr* 2010;50:295-302.
259. Kubitz R, Bode J, Erhardt A, Graf D, Kircheis G, Muller-Stover I, et al. Cholestatic liver diseases from child to adult: the diversity of MDR3 disease. *Z Gastroenterol* 2011;49:728-736.
260. Alissa FT, Jaffe R, Shneider BL. Update on progressive familial intrahepatic cholestasis. *J Pediatr Gastroenter Nutr* 2008;46:241-252.
261. Liu C, Aronow BJ, Jegga AG, Wang N, Miethke A, Mourya R, et al. Novel resequencing chip customized to diagnose mutations in patients with inherited syndromes of intrahepatic cholestasis. *Gastroenterology* 2007;132:119-126.

262. Verhulst PM, van der Velden LM, Oorschot V, van Faassen EE, Klumperman J, Houwen RH, et al. A flippase-independent function of ATP8B1, the protein affected in familial intrahepatic cholestasis type 1, is required for apical protein expression and microvillus formation in polarized epithelial cells. *HEPATOLOGY* 2010;51:2049-2060.
263. Davit-Spraul A, Fabre M, Branchereau S, Baussan C, Gonzales E, Stieger B, et al. ATP8B1 and ABCB11 analysis in 62 children with normal gamma-glutamyl transferase progressive familial intrahepatic cholestasis (PFIC): phenotypic differences between PFIC1 and PFIC2 and natural history. *HEPATOLOGY* 2010;51:1645-1655.
264. Schukfeh N, Metzelder ML, Petersen C, Reismann M, Pfister ED, Ure BM, et al. Normalization of serum bile acids after partial external biliary diversion indicates an excellent long-term outcome in children with progressive familial intrahepatic cholestasis. *J Pediatr Surg* 2012;47:501-505.
265. Colombo C, Vajro P, Degiorgio D, Coviello DA, Costantino L, Tornillo L, et al. Clinical features and genotype-phenotype correlations in children with progressive familial intrahepatic cholestasis type 3 related to ABCB4 mutations. *J Pediatr Gastroenterol Nutr* 2011;52:73-83.
266. Hori T, Egawa H, Takada Y, Ueda M, Oike F, Ogura Y, et al. Liver disease in alpha-1 antitrypsin deficiency: current understanding and future therapy. *COPD* 2013;10(Suppl 1):35-43.
267. Sveger T. Liver disease in alpha-1-antitrypsin deficiency detected by screening of 200,000 infants. *N Engl J Med* 1976;294:1316-1321.
268. Sveger T, Eriksson S. The liver in adolescents with alpha 1-antitrypsin deficiency. *HEPATOLOGY* 1995;22:514-517.
269. Ibarguen E, Gross CR, Savik SK, Sharp HL. Liver disease in alpha-1-antitrypsin deficiency: prognostic indicators. *J Pediatr* 1990;117:864-870.
270. Volpert D, Molleston JP, Perlmutter DH. Alpha1-antitrypsin deficiency-associated liver disease progresses slowly in some children. *J Pediatr Gastroenterol Nutr* 2000;31:258-263.
271. Hadzic N, Quaglia A, Mieli-Vergani G. Hepatocellular carcinoma in a 12-year-old child with PiZZ alpha-1-antitrypsin deficiency. *HEPATOLOGY* 2006;43:194.
272. Hidvegi T, Ewing M, Hale P, Dippold C, Beckett C, Kemp C, et al. An autophagy-enhancing drug promotes degradation of mutant alpha-1-antitrypsin Z and reduces hepatic fibrosis. *Science* 2010;329:229-232.
273. Jankowska I, Socha P. Progressive familial intrahepatic cholestasis and inborn errors of bile acid synthesis. *Clin Res Hepatol Gastroenterol* 2012;36:271-274.
274. Bove KE, Heubi JE, Balistreri WF, Setchell KD. Bile acid synthetic defects and liver disease: a comprehensive review. *Pediatr Dev Pathol* 2004;7:315-334.
275. Clayton PT. Disorders of bile acid synthesis. *J Inher Metab Dis* 2011;34:593-604.
276. Setchell KD, Heubi JE. Defects in bile acid biosynthesis—diagnosis and treatment. *J Pediatr Gastroenterol Nutr* 2006;43(Suppl 1):S17-22.
277. Sundaram SS, Bove KE, Lovell MA, Sokol RJ. Mechanisms of disease: Inborn errors of bile acid synthesis. *Nat Clin Pract Gastroenterol Hepatol* 2008;5:456-468.
278. Haas D, Gan-Schreier H, Langhans CD, Rohrer T, Engelmann G, Heverin M, et al. Differential diagnosis in patients with suspected bile acid synthesis defects. *World J Gastroenterol* 2012;18:1067-1076.
279. Gonzales E, Gerhardt MF, Fabre M, Setchell KD, Davit-Spraul A, Vincent I, et al. Oral cholic acid for hereditary defects of primary bile acid synthesis: a safe and effective long-term therapy. *Gastroenterology* 2009;137:1310-1320 e1-3.
280. Mizuochi T, Kimura A, Ueki I, Takahashi T, Hashimoto T, Takao A, et al. Molecular genetic and bile acid profiles in two Japanese patients with 3beta-hydroxy-DELTA5-C27-steroid dehydrogenase/isomerase deficiency. *Pediatr Res* 2010;68:258-263.
281. Subramaniam P, Clayton PT, Portmann BC, Mieli-Vergani G, Hadzic N. Variable clinical spectrum of the most common inborn error of bile acid metabolism—3beta-hydroxy-Delta 5-C27-steroid dehydrogenase deficiency. *J Pediatr Gastroenterol Nutr* 2010;50:61-66.
282. Croffie JM, Gupta SK, Chong SK, Fitzgerald JF. Tyrosinemia type 1 should be suspected in infants with severe coagulopathy even in the absence of other signs of liver failure. *Pediatrics* 1999;103:675-678.
283. Arnon R, Annunziato R, Miloh T, Wasserstein M, Sogawa H, Wilson M, et al. Liver transplantation for hereditary tyrosinemia type I: analysis of the UNOS database. *Pediatr Transpl* 2011;15:400-405.
284. Koelink CJ, van Hasselt P, van der Ploeg A, van den Heuvel-Eibrink MM, Wijburg FA, Bijleveld CM, et al. Tyrosinemia type I treated by NTBC: how does AFP predict liver cancer? *Mol Genet Metab* 2006;89:310-315.
285. de Laet C, Dionisi-Vici C, Leonard JV, McKiernan P, Mitchell G, Monti L, et al. Recommendations for the management of tyrosinaemia type 1. *Orphanet J Rare Dis* 2013;8:8.
286. Shin YS. Glycogen storage disease: clinical, biochemical, and molecular heterogeneity. *Semin Pediatr Neurol* 2006;13:115-120.
287. Maheshwari A, Rankin R, Segev DL, Thuluvath PJ. Outcomes of liver transplantation for glycogen storage disease: a matched-control study and a review of literature. *Clin Transplant* 2012;26:432-436.
288. Froissart R, Piraud M, Boudjemline AM, Vianey-Saban C, Petit F, Hubert-Buron A, et al. Glucose-6-phosphatase deficiency. *Orphanet J Rare Dis* 2011;6:27.
289. Lerut JB, Ciccarelli O, Sempoux C, Danse E, deFlandre J, Horsmans Y, et al. Glycogenesis storage type I diseases and evolutive adenomatosis: an indication for liver transplantation. *Transpl Int* 2003;16:879-884.
290. Kishnani PS, Austin SL, Arn P, Bali DS, Boney A, Case LE, et al. Glycogen storage disease type III diagnosis and management guidelines. *Genet Med* 2010;12:446-463.
291. Karwowski C, Galambos C, Finegold D, Shneider BL. Markedly elevated serum transaminases in glycogen storage disease type III. *J Pediatr Gastroenterol Nutr* 2011;52:621-623.
292. Matern D, Starzl TE, Arnaout W, Barnard J, Bynon JS, Dhawan A, et al. Liver transplantation for glycogen storage disease types I, III, and IV. *Eur J Pediatr* 1999;158(Suppl 2):S43-48.
293. Willot S, Marchand V, Rasquin A, Alvarez F, Martin SR. Systemic progression of type IV glycogen storage disease after liver transplantation. *J Pediatr Gastroenterol Nutr* 2010;51:661-664.
294. Ban HR, Kim KM, Jang JY, Kim GH, You HW, Kim K, et al. Living donor liver transplantation in a Korean child with glycogen storage disease type IV and a GBE1 mutation. *Gut Liver* 2009;3:60-63.
295. Selby R, Starzl TE, Yunis E, Todo S, Tzakis AG, Brown BI, et al. Liver transplantation for type I and type IV glycogen storage disease. *Eur J Pediatr* 1993;152(Suppl 1):S71-76.
296. Davis MK, Weinstein DA. Liver transplantation in children with glycogen storage disease: controversies and evaluation of the risk/benefit of this procedure. *Pediatr Transpl* 2008;12:137-145.
297. Rinaldo P, Matern D, Bennett MJ. Fatty acid oxidation disorders. *Annu Rev Physiol* 2002;64:477-502.
298. Herrema H, Derks TG, van Dijk TH, Bloks VW, Gerding A, Havinga R, et al. Disturbed hepatic carbohydrate management during high metabolic demand in medium-chain acyl-CoA dehydrogenase (MCAD)-deficient mice. *HEPATOLOGY* 2008;47:1894-1904.
299. Baruteau J, Levade T, Redonnet-Vernhet I, Mesli S, Bloom MC, Broue P. Hypoketotic hypoglycemia with myolysis and hypoparathyroidism: an unusual association in medium chain acyl-CoA deshydrogenase deficiency (MCADD). *J Pediatr Endocrinol Metab* 2009;22:1175-1177.
300. Bonnet D, Martin D, Pascale De L, Villain E, Jouve P, Rabier D, et al. Arrhythmias and conduction defects as presenting symptoms of fatty acid oxidation disorders in children. *Circulation* 1999;100:2248-2253.
301. van Adel BA, Tarnopolsky MA. Metabolic myopathies: update 2009. *J Clin Neuromusc Dis* 2009;10:97-121.
302. Shneider BL, Rinaldo P, Emre S, Bucuvalas J, Squires R, Narkewicz M, et al. Abnormal concentrations of esterified carnitine in bile: a

- feature of pediatric acute liver failure with poor prognosis. *HEPATOLOGY* 2005;41:717-721.
303. Rinaldo P. Fatty acid transport and mitochondrial oxidation disorders. *Semin Liver Dis* 2001;21:489-500.
 304. Ibdah JA, Bennett MJ, Rinaldo P, Zhao Y, Gibson B, Sims HF, et al. A fetal fatty-acid oxidation disorder as a cause of liver disease in pregnant women. *N Engl J Med* 1999;340:1723-1731.
 305. Tyni T, Palotie A, Viinikka L, Valanne L, Salo MK, von Döbeln U, et al. Long-chain 3-hydroxyacyl-coenzyme A dehydrogenase deficiency with the G1528C mutation: clinical presentation of thirteen patients. *J Pediatr* 1997;130:67-76.
 306. Sze YK, Dhawan A, Taylor RM, Bansal S, Mieli-Vergani G, Rela M, et al. Pediatric liver transplantation for metabolic liver disease: experience at King's College Hospital. *Transplantation* 2009;87:87-93.
 307. Watts RW. The clinical spectrum of the primary hyperoxalurias and their treatment. *J Nephrol* 1998;11(Suppl 1):4-7.
 308. Bobrowski AE, Langman CB. The primary hyperoxalurias. *Semin Nephrol* 2008;28:152-162.
 309. Cochat P, Hulton SA, Acquaviva C, Danpure CJ, Daudon M, De Marchi M, et al. Primary hyperoxaluria Type 1: indications for screening and guidance for diagnosis and treatment. *Nephrol Dial Transpl* 2012;27:1729-1736.
 310. Cochat P, Liutkus A, Fargue S, Basmaison O, Ranchin B, Rolland MO. Primary hyperoxaluria type 1: still challenging! *Pediatr Nephrol* 2006;21:1075-1081.
 311. Mor E, Neshet E, Ben-Ari Z, Weissman I, Shaharabani E, Eizner S, et al. Sequential liver and kidney transplantation from a single living donor in two young adults with primary hyperoxaluria type 1. *Liver Transpl* 2013;19:646-648.
 312. Kemper MJ. The role of preemptive liver transplantation in primary hyperoxaluria type 1. *Urol Res* 2005;33:376-379.
 313. Seashore MR. The organic acidemias: an overview. In: Pagon RA, Bird TD, Dolan CR, Stephens K, Adam MP, editors. *GeneReviews*. Seattle, WA. 2009.
 314. Strauss KA, Mazariegos GV, Sindhi R, Squires R, Finegold DN, Vockley G, et al. Elective liver transplantation for the treatment of classical maple syrup urine disease. *Am J Transpl* 2006;6:557-564.
 315. Chen PW, Hwu WL, Ho MC, Lee NC, Chien YH, Ni YH, et al. Stabilization of blood methylmalonic acid level in methylmalonic acidemia after liver transplantation. *Pediatr Transpl* 2010;14:337-341.
 316. Strauss KA, Wardley B, Robinson D, Hendrickson C, Rider NL, Puffenberger EG, et al. Classical maple syrup urine disease and brain development: principles of management and formula design. *Mol Genet Metab* 2010;99:333-345.
 317. Mazariegos GV, Morton DH, Sindhi R, Soltys K, Nayyar N, Bond G, et al. Liver transplantation for classical maple syrup urine disease: long-term follow-up in 37 patients and comparative United Network for Organ Sharing experience. *J Pediatr* 2012;160:116-121 e1.
 318. Khanna A, Hart M, Nyhan WL, Hassanein T, Panyard-Davis J, Barshop BA. Domino liver transplantation in maple syrup urine disease. *Liver Transpl* 2006;12:876-882.
 319. Schuff-Werner P, Fenger S, Kohlschein P. Role of lipid apheresis in changing times. *Clin Res Cardiol Suppl* 2012;7(Suppl 1):7-14.
 320. Maiorana A, Nobili V, Calandra S, Francalanci P, Bernabei S, El Hachem M, et al. Preemptive liver transplantation in a child with familial hypercholesterolemia. *Pediatr Transpl* 2011;15:E25-29.
 321. Lee WS, Sokol RJ. Mitochondrial hepatopathies: advances in genetics and pathogenesis. *HEPATOLOGY* 2007;45:1555-1565.
 322. Lee WS, Sokol RJ. Liver disease in mitochondrial disorders. *Semin Liver Dis* 2007;27:259-273.
 323. Darwish AA, McKiernan P, Chardot C. Paediatric liver transplantation for metabolic disorders. Part 2: Metabolic disorders with liver lesions. *Clin Res Hepatol Gastroenterol* 2011;35:271-280.
 324. Munnich A, Rustin P. Clinical spectrum and diagnosis of mitochondrial disorders. *Am J Med Genet* 2001;106:4-17.
 325. Ferrari G, Lamantea E, Donati A, Filosto M, Briem E, Carrara F, et al. Infantile hepatocerebral syndromes associated with mutations in the mitochondrial DNA polymerase-gammaA. *Brain* 2005;128(Pt 4):723-731.
 326. Milone M, Massie R. Polymerase gamma 1 mutations: clinical correlations. *Neurologist* 2010;16:84-91.
 327. Tsao CY, Mendell JR, Luquette M, Dixon B, Morrow G 3rd. Mitochondrial DNA depletion in children. *J Child Neurol* 2000;15:822-824.
 328. Rake JP, van Spronsen FJ, Visser G, Ruitenbeek W, Schweizer JJ, Bijleveld CM, et al. End-stage liver disease as the only consequence of a mitochondrial respiratory chain deficiency: no contra-indication for liver transplantation. *Eur J Pediatr* 2000;159:523-526.
 329. Thomson M, McKiernan P, Buckels J, Mayer D, Kelly D. Generalised mitochondrial cytopathy is an absolute contraindication to orthotopic liver transplant in childhood. *J Pediatr Gastroenter Nutr* 1998;26:478-481.
 330. Tzoulis C, Engelsen BA, Telstad W, Aasly J, Zeviani M, Winterthun S, et al. The spectrum of clinical disease caused by the A467T and W748S POLG mutations: a study of 26 cases. *Brain* 2006;129(Pt 7):1685-1692.
 331. Dhawan A, Mieli-Vergani G. Liver transplantation for mitochondrial respiratory chain disorders: to be or not to be? *Transplantation* 2001;71:596-598.
 332. Dubern B, Broue P, Dubuisson C, Cormier-Daire V, Habes D, Chardot C, et al. Orthotopic liver transplantation for mitochondrial respiratory chain disorders: a study of 5 children. *Transplantation* 2001;71:633-637.
 333. Sokal EM, Sokol R, Cormier V, Lacaile F, McKiernan P, Van Spronsen FJ, et al. Liver transplantation in mitochondrial respiratory chain disorders. *Eur J Pediatr* 1999;158(Suppl 2):S81-84.
 334. Delarue A, Paut O, Guys JM, Montfort MF, Lethel V, Roquelaure B, et al. Inappropriate liver transplantation in a child with Alpers-Huttenlocher syndrome misdiagnosed as valproate-induced acute liver failure. *Pediatr Transpl* 2000;4:67-71.
 335. deBruyn JC, Chan AK, Bhargava R, Idikio H, Huynh HQ. Liver failure in mitochondrial DNA depletion syndrome: the importance of serial neuroimaging in liver transplantation evaluation. *J Pediatr Gastroenter Nutr* 2007;45:252-256.
 336. Dimmock DP, Dunn JK, Feigenbaum A, Rugar A, Horvath R, Freisinger P, et al. Abnormal neurological features predict poor survival and should preclude liver transplantation in patients with deoxyguanosine kinase deficiency. *Liver Transpl* 2008;14:1480-1485.
 337. Hanchard NA, Shchelochkov OA, Roy A, Wiszniewska J, Wang J, Popek EJ, et al. Deoxyguanosine kinase deficiency presenting as neonatal hemochromatosis. *Mol Genet Metab* 2011;103:262-267.
 338. Srinath A, Shneider BL. Congenital hepatic fibrosis and autosomal recessive polycystic kidney disease. *J Pediatr Gastroenter Nutr* 2012;54:580-7.
 339. Gunay-Aygun M, Font-Montgomery E, Lukose L, Tuchman Gerstein M, Piwnicka-Worms K, Choyke P, et al. Characteristics of congenital hepatic fibrosis in a large cohort of patients with autosomal recessive polycystic kidney disease. *Gastroenterology* 2013;144:112-121 e2.
 340. Chapal M, Debout A, Dufay A, Salomon R, Roussey G, Burety S, et al. Kidney and liver transplantation in patients with autosomal recessive polycystic kidney disease: a multicentric study. *Nephrol Dial Transpl* 2012;27:2083-2088.
 341. Ko JS, Yi NJ, Suh KS, Seo JK. Pediatric liver transplantation for fibropolycystic liver disease. *Pediatr Transpl* 2012;16:195-200.
 342. Mazariegos GV, Soltys K, Bond G, Girmata A, Machaidze Z, Jaffe R, et al. Pediatric intestinal retransplantation: techniques, management, and outcomes. *Transplantation* 2008;86:1777-1782.
 343. Botha JF, Grant WJ, Torres C, Iverson AK, Sudan DL, Shaw BW Jr, et al. Isolated liver transplantation in infants with endstage liver disease due to short bowel syndrome. *Liver Transpl* 2006;12:1062-1066.
 344. Taha AM, Sharif K, Johnson T, Clarke S, Murphy MS, Gupte GL. Long-term outcomes of isolated liver transplantation for short bowel syndrome and intestinal failure-associated liver disease. *J Pediatr Gastroenter Nutr* 2012;54:547-551.

345. Cavicchi M, Beau P, Crenn P, Degott C, Messing B. Prevalence of liver disease and contributing factors in patients receiving home parenteral nutrition for permanent intestinal failure. *Ann Intern Med* 2000;132:525-532.
346. Cober MP, Teitelbaum DH. Prevention of parenteral nutrition-associated liver disease: lipid minimization. *Curr Opin Organ Transpl* 2010;15:330-333.
347. Rudolph JA, Squires R. Current concepts in the medical management of pediatric intestinal failure. *Curr Opin Organ Transpl* 2010;15:324-329.
348. Fallon EM, Le HD, Puder M. Prevention of parenteral nutrition-associated liver disease: role of omega-3 fish oil. *Curr Opin Organ Transpl* 2010;15:334-340.
349. Soden JS, Lovell MA, Brown K, Partrick DA, Sokol RJ. Failure of resolution of portal fibrosis during omega-3 fatty acid lipid emulsion therapy in two patients with irreversible intestinal failure. *J Pediatr* 2010;156:327-331.
350. Pacifico L, Nobili V, Anania C, Verdecchia P, Chiesa C. Pediatric nonalcoholic fatty liver disease, metabolic syndrome and cardiovascular risk. *World J Gastroenterol* 2011;17:3082-3091.
351. Lapecorella M, Mariani G. Factor VII deficiency: defining the clinical picture and optimizing therapeutic options. *Haemophilia* 2008;14:1170-1175.
352. Mariani G, Bernardi F. Factor VII Deficiency. *Semin Thromb Hemost* 2009;35:400-406.
353. Levi D, Pefkarou A, Fort JA, DeFaria W, Tzakis AG. Liver transplantation for factor VII deficiency. *Transplantation* 2001;72:1836-1837.
354. Muiesan P, Jassem W, Girlanda R, Steinberg R, Vilca-Melendez H, Mieli-Vergani G, et al. Segmental liver transplantation from non-heart beating donors—an early experience with implications for the future. *Am J Transpl* 2006;6(5 Pt 1):1012-1016.
355. Horita K, Matsunami H, Shimizu Y, Shimizu A, Kurimoto M, Suzuki K, et al. Treatment of a patient with hemophilia A and hepatitis C virus-related cirrhosis by living-related liver transplantation from an obligate carrier donor. *Transplantation* 2002;73:1909-1912.
356. Chalmers E, Cooper P, Forman K, Grimley C, Khair K, Minford A, et al. Purpura fulminans: recognition, diagnosis and management. *Arch Dis Child* 2011;96:1066-1071.
357. de Kort EH, Vrancken SL, van Heijst AF, Binkhorst M, Cuppen MP, Brons PP. Long-term subcutaneous protein C replacement in neonatal severe protein C deficiency. *Pediatrics* 2011;127:e1338-1342.
358. Pescatore SL. Clinical management of protein C deficiency. *Exp Opin Pharmacother* 2001;2:431-439.
359. Florman SS, Fishbein TM, Schiano T, Letizia A, Fennelly E, DeSancho M. Multivisceral transplantation for portal hypertension and diffuse mesenteric thrombosis caused by protein C deficiency. *Transplantation* 2002;74:406-407.
360. Darwish Murad S, Plessier A, Hernandez-Guerra M, Fabris F, Eapen CE, Bahr MJ, et al. Etiology, management, and outcome of the Budd-Chiari syndrome. *Ann Intern Med* 2009;151:167-175.
361. DeLeve LD, Valla DC, Garcia-Tsao G, American Association for the Study Liver D. Vascular disorders of the liver. *HEPATOLOGY* 2009;49:1729-1764.
362. Darwish Murad S, Valla DC, de Groen PC, Zeitoun G, Hopmans JA, Haagsma EB, et al. Determinants of survival and the effect of portosystemic shunting in patients with Budd-Chiari syndrome. *HEPATOLOGY* 2004;39:500-508.
363. Garcia-Pagan JC, Heydtmann M, Raffa S, Plessier A, Murad S, Fabris F, et al. TIPS for Budd-Chiari syndrome: long-term results and prognostic factors in 124 patients. *Gastroenterology* 2008;135:808-815.
364. Carnevale FC, Santos AC, Tannuri U, Cerri GG. Hepatic veins and inferior vena cava thrombosis in a child treated by transjugular intrahepatic portosystemic shunt. *Cardiovasc Intervent Radiol* 2010;33:627-630.
365. Singer AL, Locke JE, Stewart ZA, Lonze BE, Hamilton JP, Scudiere JR, et al. Successful liver transplantation for Budd-Chiari syndrome in a patient with paroxysmal nocturnal hemoglobinuria treated with the anti-complement antibody eculizumab. *Liver Transpl* 2009;15:540-543.
366. Chinnakotla S, Klintmalm GB, Kim P, Tomiyama K, Klintmalm E, Davis GL, et al. Long-term follow-up of liver transplantation for Budd-Chiari syndrome with antithrombotic therapy based on the etiology. *Transplantation* 2011;92:341-345.
367. Darwish Murad S, Kamath PS. Liver transplantation for Budd-Chiari syndrome: when is it really necessary? *Liver Transpl* 2008;14:133-135.
368. Mackiewicz A, Kotulski M, Zieniewicz K, Krawczyk M. Results of liver transplantation in the treatment of Budd-Chiari syndrome. *Ann Transpl* 2012;17:5-10.
369. Cauchi JA, Oliff S, Baumann U, Mirza D, Kelly DA, Hewitson J, et al. The Budd-Chiari syndrome in children: the spectrum of management. *J Pediatr Surg* 2006;41:1919-1923.
370. Schouten JN, Garcia-Pagan JC, Valla DC, Janssen HL. Idiopathic noncirrhotic portal hypertension. *HEPATOLOGY* 2011;54:1071-1081.
371. de Ville de Goyet J, D'Ambrosio G, Grimaldi C. Surgical management of portal hypertension in children. *Semin Pediatr Surg* 2012;21:219-232.
372. Kaymakoglu S, Kahraman T, Kudat H, Demir K, Cakaloglu Y, Adalet I, et al. Hepatopulmonary syndrome in noncirrhotic portal hypertensive patients. *Dig Dis Sci* 2003;48:556-560.
373. De BK, Sen S, Sanyal R. Hepatopulmonary syndrome in noncirrhotic portal hypertension. *Ann Intern Med* 2000;132:924.
374. Sarin SK, Gupta N, Jha SK, Agrawal A, Mishra SR, Sharma BC, et al. Equal efficacy of endoscopic variceal ligation and propranolol in preventing variceal bleeding in patients with noncirrhotic portal hypertension. *Gastroenterology* 2010;139:1238-1245.
375. Geramizadeh B, Malek-Hosseini SA, Salahi H, Bahador A, Nikeghbalian S. Liver failure and the need for transplantation in three patients with hepatoportal sclerosis. *Transpl Proc* 2008;40:3526-3528.
376. Krasinskas AM, Eghtesad B, Kamath PS, Demetris AJ, Abraham SC. Liver transplantation for severe intrahepatic noncirrhotic portal hypertension. *Liver Transpl* 2005;11:627-634; discussion 10-11.
377. Maganty K, Ghanta R, Bejarano P, Wepler D, Tekin A, Moon J, et al. Liver transplantation for hepatopulmonary syndrome due to noncirrhotic portal hypertension. *Transpl Proc* 2011;43:2814-2816.
378. Tateo M, Sebah M, Bralet MP, Teicher E, Azoulay D, Mallet V, et al. A new indication for liver transplantation: nodular regenerative hyperplasia in human immunodeficiency virus-infected patients. *Liver Transpl* 2008;14:1194-1198.
379. Gupta NA, Abramowsky C, Pillen T, Redd D, Fasola C, Heffron T, et al. Pediatric hepatopulmonary syndrome is seen with polysplenia/interrupted inferior vena cava and without cirrhosis. *Liver Transpl* 2007;13:680-686.
380. Baichi MM, Arifuddin RM, Mantry PS, Bozorgzadeh A, Ryan C. Liver transplantation in sickle cell anemia: a case of acute sickle cell intrahepatic cholestasis and a case of sclerosing cholangitis. *Transplantation* 2005;80:1630-1632.
381. Hurtova M, Bachir D, Lee K, Calderaro J, Decaens T, Kluger MD, et al. Transplantation for liver failure in patients with sickle cell disease: challenging but feasible. *Liver Transpl* 2011;17:381-392.
382. Mekeel KL, Langham MR Jr, Gonzalez-Peralta R, Fujita S, Hemming AW. Liver transplantation in children with sickle-cell disease. *Liver Transpl* 2007;13:505-508.
383. Krowka MJ. Hepatopulmonary syndromes. *Gut* 2000;46:1-4.
384. Al-Hussaini A, Taylor RM, Samyn M, Bansal S, Heaton N, Rela M, et al. Long-term outcome and management of hepatopulmonary syndrome in children. *Pediatr Transpl* 2010;14:276-282.
385. Willis AD, Miloh TA, Arnon R, Iyer KR, Suchy FJ, Kerker N. Hepatopulmonary syndrome in children — is conventional liver transplantation always needed? *Clin Transplant* 2011;25:849-855.
386. Kochar R, Tanikella R, Fallon MB. Serial pulse oximetry in hepatopulmonary syndrome. *Dig Dis Sci* 2011;56:1862-1868.
387. Roberts DN, Arguedas MR, Fallon MB. Cost-effectiveness of screening for hepatopulmonary syndrome in liver transplant candidates. *Liver Transpl* 2007;13:206-214.

388. Schenk P, Schoniger-Hekele M, Fuhrmann V, Madl C, Silberhumer G, Muller C. Prognostic significance of the hepatopulmonary syndrome in patients with cirrhosis. *Gastroenterology* 2003;125:1042-1052.
389. Fallon MB, Krowka MJ, Brown RS, Trotter JF, Zacks S, Roberts KE, et al. Impact of hepatopulmonary syndrome on quality of life and survival in liver transplant candidates. *Gastroenterology* 2008;135:1168-1175.
390. Swanson KL, Wiesner RH, Krowka MJ. Natural history of hepatopulmonary syndrome: impact of liver transplantation. *HEPATOLOGY* 2005;41:1122-1129.
391. Alonso J, Sierre S, Lipsich J, Questa H, Faella H, Muguillansky S. Endovascular treatment of congenital portal vein fistulas with the Amplatzer occlusion device. *J Vasc Interv Radiol* 2004;15:989-993.
392. Alvarez AE, Ribeiro AF, Hessel G, Baracat J, Ribeiro JD. Abernethy malformation: one of the etiologies of hepatopulmonary syndrome. *Pediatr Pulmonol* 2002;34:391-394.
393. Grimaldi C, Monti L, Falappa P, d'Ambrosio G, Manca A, de Ville de Goyet J. Congenital intrahepatic portohepatic shunt managed by interventional radiologic occlusion: a case report and literature review. *J Pediatr Surg* 2012;47:e27-31.
394. Morikawa N, Honna T, Kuroda T, Kitano Y, Fuchimoto Y, Kawashima N, et al. Resolution of hepatopulmonary syndrome after ligation of a portosystemic shunt in a pediatric patient with an Abernethy malformation. *J Pediatr Surg* 2008;43:e35-38.
395. Iqbal CW, Krowka MJ, Pham TH, Freese DK, El Youssef M, Ishitani MB. Liver transplantation for pulmonary vascular complications of pediatric endstage liver disease. *J Pediatr Surg* 2008;43:1813-1820.
396. Whitworth JR, Ivy DD, Gralla J, Narkewicz MR, Sokol RJ. Pulmonary vascular complications in asymptomatic children with portal hypertension. *J Pediatr Gastroenterol Nutr* 2009;49:607-612.
397. Rodriguez-Roisin R, Krowka MJ, Herve P, Fallon MB. Pulmonary-hepatic vascular disorders (PHD). *Eur Respir J* 2004;24:861-880.
398. Laving A, Khanna A, Rubin L, Ing F, Dohil R, Lavine JE. Successful liver transplantation in a child with severe portopulmonary hypertension treated with epoprostenol. *J Pediatr Gastroenterol Nutr* 2005;41:466-468.
399. Safdar Z, Bartolome S, Sussman N. Portopulmonary hypertension: an update. *Liver Transpl* 2012;18:881-891.
400. Fox AN, Brown RS Jr. Is the patient a candidate for liver transplantation? *Clin Liver Dis* 2012;16:435-448.
401. Ahmed A, Keeffe EB. Current indications and contraindications for liver transplantation. *Clin Liver Dis* 2007;11:227-247.
402. Watt KD, Pedersen RA, Kremers WK, Heimbach JK, Sanchez W, Gores GJ. Long-term probability of and mortality from de novo malignancy after liver transplantation. *Gastroenterology* 2009;137:2010-2017.
403. Chan G, Kocha W, Reid R, Taqi A, Wall W, Quan D. Liver transplantation for symptomatic liver metastases of neuroendocrine tumours. *Curr Oncol* 2012;19:217-221.
404. Kerkar N, Emre S. Issues unique to pediatric liver transplantation. *Clin Liver Dis* 2007;11:323-335.
405. McGoogan KE, Haafiz AB, Gonzalez Peralta RP. Herpes simplex virus hepatitis in infants: clinical outcomes and correlates of disease severity. *J Pediatr* 2011;159:608-611.
406. Verma A, Dhawan A, Zuckerman M, Hadzic N, Baker AJ, Mieli-Vergani G. Neonatal herpes simplex virus infection presenting as acute liver failure: prevalent role of herpes simplex virus type I. *J Pediatr Gastroenterol Nutr* 2006;42:282-286.
407. Patterson MC, Hendriksz CJ, Walterfang M, Sedel F, Vanier MT, Wijburg F. Recommendations for the diagnosis and management of Niemann-Pick disease type C: an update. *Mol Genet Metab* 2012;106:330-344.
408. Vanier MT. Niemann-Pick disease type C. *Orphanet J Rare Dis* 2010;5:16.
409. Vanier MT, Wenger DA, Comly ME, Rousson R, Brady RO, Pentchev PG. Niemann-Pick disease group C: clinical variability and diagnosis based on defective cholesterol esterification. A collaborative study on 70 patients. *Clin Genet* 1988;33:331-348.
410. Yerushalmi B, Sokol RJ, Narkewicz MR, Smith D, Ashmead JW, Wenger DA. Niemann-pick disease type C in neonatal cholestasis at a North American Center. *J Pediatr Gastroenterol Nutr* 2002;35:44-50.
411. Kelly DA, Portmann B, Mowat AP, Sherlock S, Lake BD. Niemann-Pick disease type C: diagnosis and outcome in children, with particular reference to liver disease. *J Pediatr* 1993;123:242-247.
412. Gartner JC Jr, Bergman I, Malatack JJ, Zitelli BJ, Jaffe R, Watkins JB, et al. Progression of neurovisceral storage disease with supranuclear ophthalmoplegia following orthotopic liver transplantation. *Pediatrics* 1986;77:104-106.
413. Henter JI. Biology and treatment of familial hemophagocytic lymphohistiocytosis: importance of perforin in lymphocyte-mediated cytotoxicity and triggering of apoptosis. *Med Pediatr Oncol* 2002;38:305-309.
414. Henter JI, Arico M, Elinder G, Imashuku S, Janka G. Familial hemophagocytic lymphohistiocytosis. Primary hemophagocytic lymphohistiocytosis. *Hematol Oncol Clin N Am* 1998;12:417-433.
415. Nitta A, Suzumura H, Watabe Y, Okuya M, Nakajima D, Kurosawa H, et al. Fetal hemophagocytic lymphohistiocytosis in a premature infant. *J Pediatr* 2007;151:98.
416. Parizhskaya M, Reyes J, Jaffe R. Hemophagocytic syndrome presenting as acute hepatic failure in two infants: clinical overlap with neonatal hemochromatosis. *Pediatr Dev Pathol* 1999;2:360-366.
417. Shanmugam NP, Bansal S, Greenough A, Verma A, Dhawan A. Neonatal liver failure: aetiologies and management—state of the art. *Eur J Pediatr* 2011;170:573-581.
418. Malinchoc M, Kamath PS, Gordon FD, Peine CJ, Rank J, ter Borg PC. A model to predict poor survival in patients undergoing transjugular intrahepatic portosystemic shunts. *HEPATOLOGY* 2000;31:864-871.
419. McDiarmid SV, Anand R, Lindblad AS. Development of a pediatric endstage liver disease score to predict poor outcome in children awaiting liver transplantation. *Transplantation* 2002;74:173-181.
420. Reyes J. A critical analysis to a critical analysis: breaking the circle of organ allocation in the United States. *Liver Transpl* 2005;11:737-738.
421. Shneider BL, Neimark E, Frankenberg T, Arnott L, Suchy FJ, Emre S. Critical analysis of the pediatric endstage liver disease scoring system: a single center experience. *Liver Transpl* 2005;11:788-795.
422. Salvalaggio PR, Neighbors K, Kelly S, Emerick KM, Iyer K, Superina RA, et al. Regional variation and use of exception letters for cadaveric liver allocation in children with chronic liver disease. *Am J Transpl* 2005;5:1868-1874.
423. Rodriguez-Luna H, Vargas HE, Moss A, Reddy KS, Freeman RB, Mulligan D. Regional variations in peer reviewed liver allocation under the MELD system. *Am J Transpl* 2005;5:2244-2247.
424. UK Transplant, Donor Organ Sharing Scheme Operating Principles, Liver Transplant Units in the UK and Republic of Ireland. In: *Transplant NBA*, editor. Available at: http://www.organdonation.nhs.uk/ukt/about_transplants/organ_allocation/liver/liver_organ_sharing_principles/2012.
425. Desschans B, Van Gelder F, Van Hees D, de Rocy J, Monbaliu D, Aerts R, et al. Evolution in allocation rules for renal, hepatic, pancreatic and intestinal grafts. *Acta Chir Belg* 2008;108:31-34.
426. Neto JS, Carone E, Pugliese RP, Fonseca EA, Porta G, Miura I, et al. Modified pediatric endstage liver disease scoring system and pediatric liver transplantation in Brazil. *Liver Transpl* 2010;16:426-430.
427. Choi Y, Lee KW, Hong G, Kim H, Park MS, Suh S, et al. Status and Current Problems in the Allocation System for Pediatric Liver Transplantation in Korea. *J Korean Soc Transplant* 2012;26:196-201.
428. Organ Allocation Protocols: Liver Protocol. Available at: <http://www.tsanz.com.au/organallocationprotocols/liverprotocol.asp>: The Transplantation Society of Australia and New Zealand, 2012.
429. Aita K. New organ transplant policies in Japan, including the family-oriented priority donation clause. *Transplantation* 2011;91:489-491.
430. Thuluvath PJ, Guidinger MK, Fung JJ, Johnson LB, Rayhill SC, Pelletier SJ. Liver transplantation in the United States, 1999-2008. *Am J Transpl* 2010;10(4 Pt 2):1003-1019.

431. McDiarmid SV, Anand R, Martz K, Millis MJ, Mazariegos G. A multivariate analysis of pre-, peri-, and post-transplant factors affecting outcome after pediatric liver transplantation. *Ann Surg* 2011;254:145-154.
432. Diamond IR, Fecteau A, Millis JM, Losanoff JE, Ng V, Anand R, et al. Impact of graft type on outcome in pediatric liver transplantation: a report from Studies of Pediatric Liver Transplantation (SPLIT). *Ann Surg* 2007;246:301-310.
433. Sieders E, Peeters PM, TenVergert EM, Bijleveld CM, de Jong KP, Zwaveling JH, et al. Analysis of survival and morbidity after pediatric liver transplantation with full-size and technical-variant grafts. *Transplantation* 1999;68:540-545.
434. Furtado A, Tome L, Oliveira FJ, Furtado E, Viana J, Perdigoto R. Sequential liver transplantation. *Transpl Proc* 1997;29:467-468.
435. Mazariegos GV, Morton DH, Sindhi R, Soltys K, Nayyar N, Bond G, et al. Liver transplantation for classical maple syrup urine disease: long-term follow-up in 37 patients and comparative United Network for Organ Sharing experience. *J Pediatr* 2012;160:116-121 e1.
436. Saner FH, Treckmann J, Pratschke J, Arbogast H, Rahmel A, Vester U, et al. Early renal failure after domino liver transplantation using organs from donors with primary hyperoxaluria type 1. *Transplantation* 2010;90:782-785.
437. Casas-Melley AT, Thomas PG, Krueger LJ, Falkenstein KP, Flynn LM, Conley SB, et al. Domino as a bridge to definitive liver transplantation in a neonate. *Pediatr Transpl* 2002;6:249-254.
438. Horslen SP, Fox IJ. Hepatocyte transplantation. *Transplantation* 2004;77:1481-1486.
439. Lysy PA, Campard D, Smets F, Najimi M, Sokal EM. Stem cells for liver tissue repair: current knowledge and perspectives. *World J Gastroenterol* 2008;14:864-875.
440. Soltys KA, Soto-Gutierrez A, Nagaya M, Baskin KM, Deutsch M, Ito R, et al. Barriers to the successful treatment of liver disease by hepatocyte transplantation. *J Hepatol* 2010;53:769-774.