

Diagnosis and Treatment of Wilson Disease: An Update

Eve A. Roberts¹ and Michael L. Schilsky²

This guideline has been approved by the American Association for the Study of Liver Diseases (AASLD) and represents the position of the association.

Preamble

These recommendations provide a data-supported approach to the diagnosis and treatment of patients with Wilson disease. They are based on the following: (1) formal review and analysis of the recently-published world literature on the topic including Medline search; (2) American College of Physicians Manual for Assessing Health Practices and Designing Practice Guidelines¹; (3) guideline policies, including the AASLD Policy on the Development and Use of Practice Guidelines and the American Gastroenterological Association Policy Statement on Guidelines²; (4) the experience of the authors in the specified topic. A significant problem with the literature on Wilson disease is that patients are sufficiently rare to preclude large cohort studies or randomized controlled trials; moreover, most treatment modalities were developed at a time when conventions for drug assessment were less stringent than at present.

Intended for use by physicians, these recommendations suggest preferred approaches to the diagnostic, therapeutic, and preventive aspects of care. They are intended to be flexible, in contrast to standards of care, which are inflexible policies to be followed in every case. Specific recommendations are based on relevant published information. To characterize more fully the quality of evidence supporting recommendations, the Practice Guidelines Committee of the AASLD requires a *class* (reflecting ben-

efit versus risk) and *level* (assessing strength or certainty) of evidence to be assigned and reported with each recommendation (Table 1, adapted from the American College of Cardiology and the American Heart Association Practice Guidelines^{3,4}).

Introduction

Copper is an essential metal that is an important cofactor for many proteins. The average diet provides substantial amounts of copper, typically 2-5 mg/day; the recommended intake is 0.9 mg/day. Most dietary copper ends up being excreted. Copper is absorbed by enterocytes mainly in the duodenum and proximal small intestine and transported in the portal circulation in association with albumin and the amino acid histidine to the liver, where it is avidly removed from the circulation. The liver utilizes some copper for metabolic needs, synthesizes and secretes the copper-containing protein ceruloplasmin, and excretes excess copper into bile. Processes that impair biliary copper excretion can lead to increases in hepatic copper content.

Wilson disease (WD; also known as hepatolenticular degeneration) was first described in 1912 by Kinnear Wilson as “progressive lenticular degeneration,” a familial, lethal neurological disease accompanied by chronic liver disease leading to cirrhosis.⁵ Over the next several decades, the role of copper in the pathogenesis of WD was established, and the pattern of inheritance was determined to be autosomal recessive.^{6,7} In 1993, the abnormal gene in WD was identified.⁸⁻¹⁰ This gene, *ATP7B*, encodes a metal-transporting P-type adenosine triphosphatase (ATPase), which is expressed mainly in hepatocytes and functions in the transmembrane transport of copper within hepatocytes. Absent or reduced function of ATP7B protein leads to decreased hepatocellular excretion of copper into bile. This results in hepatic copper accumulation and injury. Eventually, copper is released into the bloodstream and deposited in other organs, notably the brain, kidneys, and cornea. Failure to incorporate copper into ceruloplasmin is an additional consequence of the loss of functional ATP7B protein. The hepatic production and secretion of the ceruloplas-

Abbreviations: AASLD, American Association for the Study of Liver Diseases; BAL, British anti-Lewisite; MR, magnetic resonance; TM, tetrathiomolybdate; WD, Wilson disease.

From the ¹Division of Gastroenterology, Hepatology and Nutrition, The Hospital for Sick Children, and Departments of Paediatrics, Medicine and Pharmacology, University of Toronto, Toronto, Ontario, Canada, and ²Department of Medicine and Surgery, Division of Digestive Diseases, Section of Transplant and Immunology, Yale University Medical Center, New Haven, CT.

Copyright © 2008 by the American Association for the Study of Liver Diseases.

Published online in Wiley InterScience (www.interscience.wiley.com).

DOI 10.1002/hep.22261

Potential conflict of interest: Nothing to report.

Table 1. Grading System for Recommendations

Classification	Description
Class I	Conditions for which there is evidence and/or general agreement that a given procedure or treatment is beneficial, useful, and effective.
Class II	Conditions for which there is conflicting evidence and/or a divergence of opinion about the usefulness/efficacy of a procedure or treatment.
Class IIa	Weight of evidence/opinion is in favor of usefulness/efficacy.
Class IIb	Usefulness/efficacy is less well established by evidence/opinion.
Class III	Conditions for which there is evidence and/or general agreement that a procedure/treatment is not useful/effective and in some cases may be harmful.

Level of Evidence	Description
Level A	Data derived from multiple randomized clinical trials or meta-analyses.
Level B	Data derived from a single randomized trial, or nonrandomized studies.
Level C	Only consensus opinion of experts, case studies, or standard-of-care.

min protein without copper, apoceruloplasmin, result in the decreased blood level of ceruloplasmin found in most patients with WD due to the reduced half-life of apoceruloplasmin.¹¹

WD occurs worldwide with an average prevalence of ~30 affected individuals per million population.¹² It can present clinically as liver disease, as a progressive neurological disorder (hepatic dysfunction being less apparent or occasionally absent), or as psychiatric illness. WD presents with liver disease more often in children and younger adult patients than in older adults. Symptoms at any age are frequently nonspecific.

WD was uniformly fatal until treatments were developed a half-century ago. WD was one of the first liver diseases for which effective pharmacologic treatment was identified. The first chelating agent introduced in 1951 for the treatment of WD was British anti-Lewisite (BAL or dimercaptopropanol).^{13,14} The identification and testing of an orally administered chelator, D-penicillamine, by John Walsh in 1956 revolutionized treatment of this disorder.¹⁵ Other treatment modalities have since been introduced, including zinc salts to block enteral copper absorption, tetrathiomolybdate (TM) to chelate copper and block enteral absorption, and orthotopic liver transplantation, which may be lifesaving and curative for this disorder.

Clinical Features

Over the years, diagnostic advances have enabled more systematic evaluation of individuals suspected to have WD prior to their development of neurologic symptoms.

These include recognition of corneal Kayser-Fleischer rings,¹⁶ identification of reduced concentrations of ceruloplasmin in the circulation of most patients,¹⁷ and the ability to measure copper concentration in percutaneous liver biopsy specimens. More recently, molecular diagnostic studies have made it feasible either to define patterns of haplotypes or polymorphisms of DNA surrounding *ATP7B* which are useful for identification of first-degree relatives of newly diagnosed patients or to examine directly for disease-specific *ATP7B* mutations on both alleles of chromosome 13.

Patients with cirrhosis, neurological manifestations, and Kayser-Fleischer rings are easily diagnosed as having WD because they resemble the original clinical description. The patient presenting with liver disease, who is at least 5 years old but under 40 years old, with a decreased serum ceruloplasmin and detectable Kayser-Fleischer rings, has been generally regarded as having classic WD.¹⁸ However, about half of the patients presenting with liver disease do not possess two of these three criteria and pose a challenge in trying to establish the diagnosis.¹⁹ Moreover, as with other liver diseases, patients may come to medical attention when their clinical disease is comparatively mild.

Because at present, *de novo* genetic diagnosis is expensive and not universally available (and sometimes inconclusive), a combination of clinical findings and biochemical testing is usually necessary to establish the diagnosis of WD (Fig. 1). A scoring system has been devised to aid diagnosis, based on a composite of key parameters²⁰; it has been subjected to preliminary validation in children.²¹ A molecular genetic strategy using haplotype analysis or direct mutation analysis may be effective in identifying affected siblings of probands.

Spectrum of Disease. The spectrum of liver disease encountered in patients with WD is summarized in Table 2. The type of the liver disease can be highly variable, ranging from asymptomatic with only biochemical abnormalities to acute liver failure. Children may be entirely asymptomatic, with hepatic enlargement or abnormal serum aminotransferases found only incidentally. Some patients have a brief clinical illness resembling an acute viral hepatitis, and others may present with features indistinguishable from autoimmune hepatitis. Some present with only biochemical abnormalities or histologic findings of steatosis on liver biopsy. Many patients present with signs of chronic liver disease and evidence of cirrhosis, either compensated or decompensated. Patients may present with isolated splenomegaly due to clinically inapparent cirrhosis with portal hypertension. WD may also present as acute liver failure with an associated Coombs-negative hemolytic anemia and acute renal failure. Some patients

Unexplained liver disease

Serum ceruloplasmin (CPN); 24-h urinary Cu; slit lamp examination

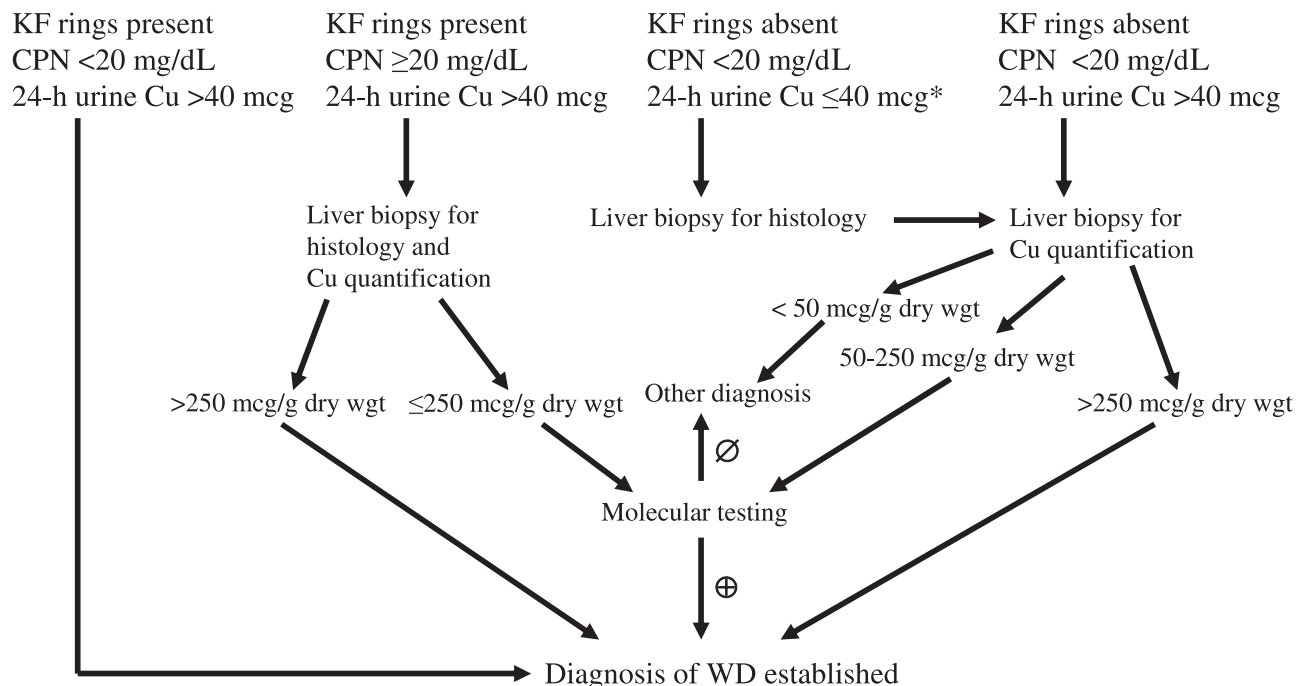


Fig. 1. Approach to diagnosis of Wilson disease (WD) in a patient with unexplained liver disease. Molecular testing means confirming homozygosity for one mutation or defining two mutations constituting compound heterozygosity. *Assure adequacy of urine collection. Conversion to SI units: CPN <20 mg/dL or 0.2 g/L; 24-hour urinary Cu >40 μ g/day or 0.6 μ mol/day. Note that normal ranges for CPN may vary slightly between laboratories. Abbreviations: CPN, ceruloplasmin; KF, Kayser-Fleischer.

have transient episodes of jaundice due to hemolysis. Low-grade hemolysis may be associated with WD when liver disease is not clinically evident. In one series, hemolysis was a presenting feature in 25 of 220 cases (11%); in these patients, hemolysis occurred as a single acute episode, recurrently, or was low-grade and chronic.²² In a series of 283 Japanese cases of WD, only three presented with acute hemolysis alone,²³ but one-quarter of the patients who presented with jaundice also had hemolysis. Patients diagnosed with WD who have a history of jaundice may have previously experienced an episode of hemolysis.

Patients with apparent autoimmune hepatitis presenting in childhood, or in adults with a suspicion of autoimmune hepatitis that does not readily respond to therapy, should be assessed carefully for WD because elevated serum immunoglobulins and detectable nonspecific autoantibodies may be found in both conditions.²⁴⁻²⁶

Neurologic manifestations of WD typically present later than the liver disease, most often in the third decade of life, but they can present in childhood (Fig. 2). Earlier subtle

findings may appear in pediatric patients, including changes in behavior, deterioration in schoolwork, or inability to perform activities requiring good hand-eye coordination. Handwriting may deteriorate, and cramped small handwriting as in Parkinson disease (micrographia) may develop. Other common findings in those presenting with neurologic disease include tremor, lack of motor coordination, drooling, dysarthria, dystonia, and spasticity. Because of pseudo-bulbar palsy, transfer dysphagia may also occur, with a risk of aspiration if severe. Dysautonomia may be present. Migraine headaches and insomnia may be reported; however, seizures are infrequent. Along with behavioral changes, other psychiatric manifestations include depression, anxiety, and even frank psychosis. Many of the individuals with neurologic or psychiatric manifestations may have cirrhosis, but frequently they are not symptomatic from their liver disease.

Patients with WD may present with important extrahepatic manifestations apart from neurologic or psychiatric disease: renal abnormalities including aminoaciduria and nephrolithiasis,²⁷⁻²⁹ skeletal abnormalities such as premature osteoporosis and arthritis,³⁰ cardiomyopa-

Table 2. Clinical Features in Patients with Wilson Disease

Hepatic	<ul style="list-style-type: none"> • Asymptomatic hepatomegaly • Isolated splenomegaly • Persistently elevated serum aminotransferase activity (AST, ALT) • Fatty liver • Acute hepatitis • Resembling autoimmune hepatitis • Cirrhosis: compensated or decompensated • Acute liver failure • Movement disorders (tremor, involuntary movements)
Neurological	<ul style="list-style-type: none"> • Drooling, dysarthria • Rigid dystonia • Pseudobulbar palsy • Dysautonomia • Migraine headaches • Insomnia • Seizures
Psychiatric	<ul style="list-style-type: none"> • Depression • Neurotic behaviours • Personality changes • Psychosis
Other systems	<ul style="list-style-type: none"> • Ocular: Kayser-Fleischer rings, sunflower cataracts • Cutaneous: lunulae ceruleae • Renal abnormalities: aminoaciduria and nephrolithiasis • Skeletal abnormalities: premature osteoporosis and arthritis • Cardiomyopathy, dysrhythmias • Pancreatitis • Hypoparathyroidism • Menstrual irregularities; infertility, repeated miscarriages

thy,³¹⁻³³ pancreatitis,³⁴ hypoparathyroidism,³⁵ and infertility or repeated miscarriages.³⁶⁻³⁹

Age. Even when presymptomatic siblings are excluded, the age at which WD may present or be diagnosed is both younger and older than generally appreciated, though the majority present between ages 5 and 35. WD is increasingly diagnosed in children younger than 5 years old, with atypical findings in children under 2 years old,⁴⁰⁻⁴⁴ cirrhosis in a 3-year-old,⁴⁵ and acute liver failure in a 5-year-old.⁴⁶ The oldest patients with WD, confirmed by molecular studies demonstrating *ATP7B* mutations, were in their early 70s.^{47,48} Although the upper age limit for consideration of WD is generally stated as <40 years, when other concurrent neurologic or psychiatric symptoms and histologic or biochemical findings suggest this disorder, further evaluation should be carried out in older individuals.

Kayser-Fleischer Ring. Kayser-Fleischer rings represent deposition of copper in Descemet's membrane of the cornea. When they are visible by direct inspection, they appear as a band of golden-brownish pigment near the limbus. A slit-lamp examination by an experienced observer is required to identify Kayser-Fleischer rings in

most patients. They are not entirely specific for WD, because they may be found in patients with chronic cholestatic diseases⁴⁹⁻⁵¹ and in children with neonatal cholestasis⁵²; however, these disorders can usually be distinguished from WD on clinical grounds. Large series of patients with WD show that Kayser-Fleischer rings are present in only 44%-62% of patients with mainly hepatic disease at the time of diagnosis.^{19,53-56} In children presenting with liver disease, Kayser-Fleischer rings are usually absent.⁵⁷⁻⁵⁹ Kayser-Fleischer rings are almost invariably present in patients with a neurological presentation, but even in these patients they may be absent in 5% of cases.^{19,60} Kayser-Fleischer rings are rarely reported with chronic cholestatic liver disease.

Other ophthalmological changes may be found. Sunflower cataracts, also found by slit-lamp examination, represent deposits of copper in the lens.⁶¹ These typically do not obstruct vision. Both Kayser-Fleischer rings and sunflower cataracts will gradually disappear with effective medical treatment or following liver transplant, though the rate of disappearance does not correlate with resolution of clinical symptoms.^{62,63} The reappearance of either of these ophthalmologic findings in a medically treated patient in whom these had previously disappeared suggests noncompliance with therapy.

Recommendations:

1. WD should be considered in any individual between the ages of 3 and 55 years with liver abnormalities of uncertain cause. Age alone should not be the basis for eliminating a diagnosis of WD (Class I, Level B).

2. WD must be excluded in any patient with unexplained liver disease along with neurological or neuropsychiatric disorder (Class I, Level B).

3. In a patient in whom WD is suspected, Kayser-Fleischer rings should be sought by slit-lamp examination by a skilled examiner. The absence of Kayser-Fleischer rings does not exclude the diagnosis of WD, even in patients with predominantly neurological disease (Class I, Level B).

Diagnostic Testing:

Biochemical Liver Tests. Serum aminotransferase activities are generally abnormal in WD except at a very early age. In many individuals, the degree of elevation of aminotransferase activity may be mild and does not reflect the severity of the liver disease.

Ceruloplasmin. This 132-kDa protein is synthesized mainly in the liver and is an acute phase reactant. The vast majority of the protein is secreted into the circulation from hepatocytes as a copper-carrying protein containing

Neuropsychiatric disorder \pm liver disease

Serum ceruloplasmin (CPN); 24-h urinary Cu; slit lamp examination

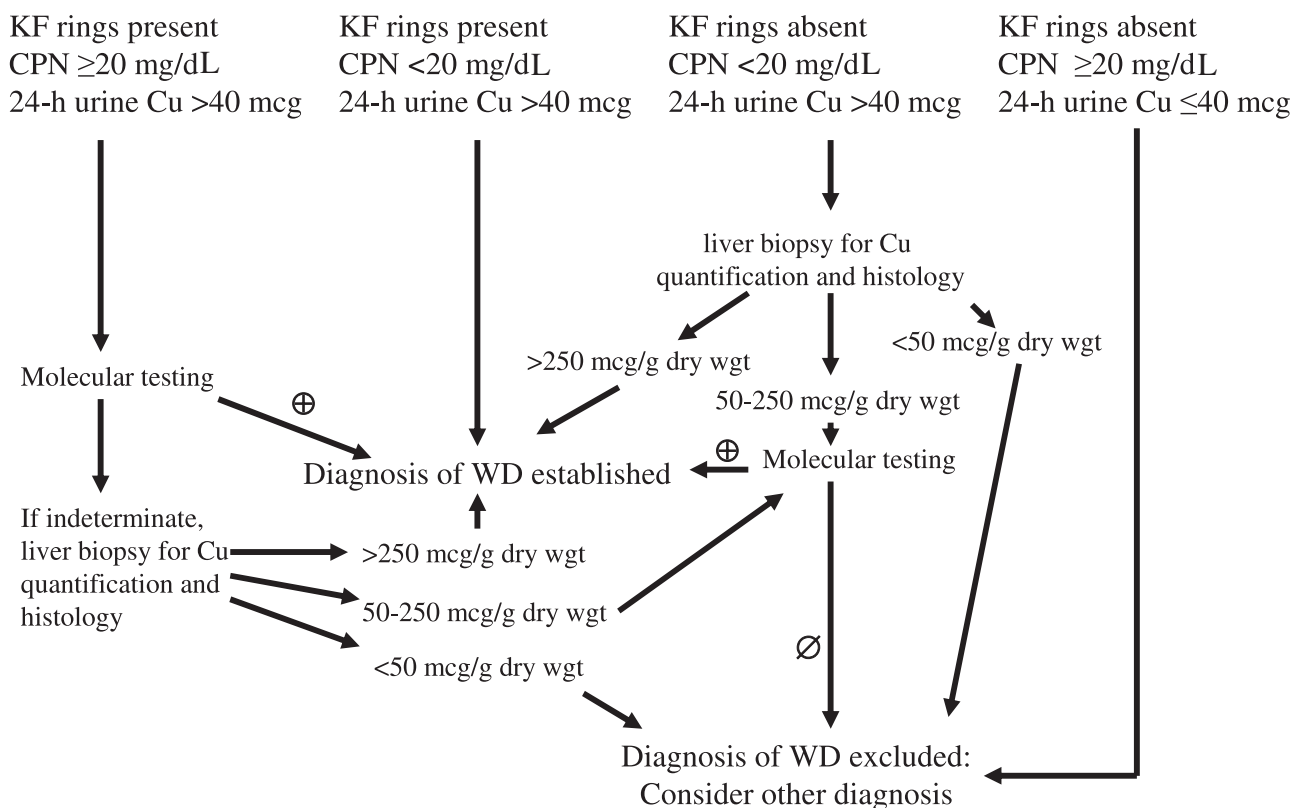


Fig. 2. Approach to diagnosis of Wilson disease (WD) in a patient with a neurological disorder or psychiatric disease with or without liver disease. Molecular testing means confirming homozygosity for one mutation or defining two mutations constituting compound heterozygosity. Conversion to SI units: CPN <20 mg/dL or 0.2 g/L; 24-hour urinary Cu >40 μ g/day or 0.6 μ mol/day. Abbreviations: CPN, ceruloplasmin; KF, Kayser-Fleischer.

six copper atoms per molecule of ceruloplasmin (holoceruloplasmin), and the remainder as the protein lacking copper (apoceruloplasmin). Ceruloplasmin is the major carrier for copper in the blood, accounting for 90% of the circulating copper in normal individuals. Ceruloplasmin is a ferroxidase. It is a nitric oxide oxidase thus influencing nitric oxide homeostasis,⁶⁴ and it acts as an oxidase for substrates such as *p*-phenylamine diamine⁶⁵ and *o*-dianisidine,⁶⁶ which forms the basis for enzymatic assays for the protein. Levels of serum ceruloplasmin may be measured enzymatically by their copper-dependent oxidase activity toward these substrates, or by antibody-dependent assays such as radioimmunoassay, radial immunodiffusion, or nephelometry. Results generally are regarded as equivalent,⁶⁷ but immunologic assays routinely in clinical use may overestimate ceruloplasmin concentrations because they do not discriminate between apoceruloplasmin and holoceruloplasmin. This makes serum ceruloplasmin as a diagnostic criterion difficult to interpret. Serum ceruloplasmin concentrations are elevated by acute inflamma-

tion and in states associated with hyperestrogenemia such as pregnancy, estrogen supplementation, and use of some oral contraceptive pills.

Levels of serum ceruloplasmin are physiologically very low in early infancy to the age of 6 months, peak at higher than adult levels in early childhood (at approximately 300-500 mg/L), and then settle to the adult range. Serum ceruloplasmin is typically decreased in patients with WD, but serum ceruloplasmin may be low in certain other conditions with marked renal or enteric protein loss or with severe end-stage liver disease of any etiology or with various rare neurologic diseases.⁶⁸ Low levels of ceruloplasmin and/or appearance of pancytopenia have been recognized in patients with copper deficiency when trace elements were not added to parenteral alimentation⁶⁹ and in patients with Menkes disease, an X-linked disorder of copper transport due to mutations in *ATP7A*.⁷⁰ Patients with the rare disorder aceruloplasminemia lack the protein entirely due to mutations in the ceruloplasmin gene on

chromosome 3, but these patients may exhibit hemosiderosis, not copper accumulation.^{71,72}

A serum ceruloplasmin level <200 mg/L (<20 mg/dL, though there are different normal ranges depending on the laboratory) has been considered consistent with WD, and diagnostic if associated with Kayser-Fleischer rings. A prospective study of using serum ceruloplasmin alone as a screening test for WD in patients referred with liver disease showed that subnormal ceruloplasmin had a very low positive predictive value: of 2867 patients tested, only 17 had subnormal ceruloplasmin and only one of these was found to have WD.⁷³ Other recent reports indicate the limitations of ceruloplasmin measurements for diagnosis. In one series, 12 of 55 patients with WD had normal ceruloplasmin and no Kayser-Fleischer rings.¹⁹ In another study, six of 22 patients with WD had serum ceruloplasmin >170 mg/L (>17 mg/dL), and of these, four had no Kayser-Fleischer rings.⁵³ In children, three of 26 patients had ceruloplasmin >150 mg/L (>15 mg/dL)⁵⁹ and in an early study, 10 of 28 children with WD had serum ceruloplasmin ≥ 200 mg/L (≥ 20 mg/dL).⁷⁴ However, most reports based on several decades of experience from the mid-1950s onward indicate that 90%–100% of patients had serum ceruloplasmin in the subnormal range.^{75–77} Using serum ceruloplasmin to identify patients with WD is further complicated by overlap with some heterozygotes.⁷⁵ Approximately 20% of heterozygotes have decreased levels of serum ceruloplasmin.

Uric Acid. Serum uric acid may be decreased at presentation with symptomatic hepatic or neurological disease because of associated renal tubular dysfunction (Fanconi syndrome). Insufficient evidence is available to determine the predictive value of this finding.

Recommendation:

4. An extremely low serum ceruloplasmin level (<50 mg/L or <5 mg/dL) should be taken as strong evidence for the diagnosis of WD. Modestly subnormal levels suggest further evaluation is necessary. Serum ceruloplasmin within the normal range does not exclude the diagnosis (Class I, Level B).

Serum Copper. Although a disease of copper overload, the total serum copper (which includes copper incorporated in ceruloplasmin) in WD is usually decreased in proportion to the decreased ceruloplasmin in the circulation. In patients with severe liver injury, serum copper may be within the normal range despite a decreased serum ceruloplasmin level. In the setting of acute liver failure due to WD, levels of serum copper may be markedly elevated due to the sudden release of the metal from tissue stores. Normal or elevated serum copper levels in the face

of decreased levels of ceruloplasmin indicate an increase in the concentration of copper not bound to ceruloplasmin in the blood (non-ceruloplasmin bound copper).

The serum non-ceruloplasmin bound copper concentration has been proposed as a diagnostic test for WD. It is elevated above 25 $\mu\text{g/dL}$ (250 $\mu\text{g/L}$) in most untreated patients (normal <15 $\mu\text{g/dL}$ or <150 $\mu\text{g/L}$). Non-ceruloplasmin bound copper is usually estimated from the serum copper and ceruloplasmin. The amount of copper associated with ceruloplasmin is approximately 3.15 μg of copper per milligram of ceruloplasmin. Thus, the non-ceruloplasmin bound copper is the difference between the serum copper concentration in micrograms per deciliter and three times the serum ceruloplasmin concentration in milligrams per deciliter.^{78,79} (For Système International (SI) units, both serum copper and ceruloplasmin should be expressed as “per liter”; the conversion factor is unchanged, but the normal reference value is <150 $\mu\text{g/L}$.) The serum non-ceruloplasmin bound copper concentration may be elevated in acute liver failure of any etiology, not only in WD,^{57,80} and it may be elevated in chronic cholestasis⁸¹ and in cases of copper intoxication from ingestion or poisoning.

The major problem with non-ceruloplasmin bound copper as a diagnostic test for WD is that it is dependent on the adequacy of the methods for measuring both serum copper and ceruloplasmin. If the serum copper measurement is inaccurate or, more commonly, if the serum ceruloplasmin measurement overestimates holoceruloplasmin, then the estimated non-ceruloplasmin bound copper concentration cannot be interpreted because it may be a negative number. This determination may be of more value in patient monitoring of pharmacotherapy than in the diagnosis of WD. Non-ceruloplasmin bound copper concentration <5 $\mu\text{g/dL}$ (<50 $\mu\text{g/L}$) may signal systemic copper depletion that can occur in some patients with prolonged treatment.

Urinary Copper Excretion. The amount of copper excreted in the urine in a 24-hour period may be useful for diagnosing WD and for monitoring of treatment. The 24-hour urinary excretion of copper reflects the amount of non-ceruloplasmin bound copper in the circulation. Basal measurements can provide useful diagnostic information so long as copper does not contaminate the collection apparatus and the urine collection is complete. There is too much variability in the copper content in spot urine specimens for them to be utilized. Volume and total creatinine excretion in the 24-hour urine collection are measured to assess completeness. The conventional level taken as diagnostic of WD is >100 $\mu\text{g}/24$ hours (>1.6 $\mu\text{mol}/24$ hours) in symptomatic patients.^{56,80} Recent studies indicate that basal 24-hour urinary copper

excretion may be $<100 \mu\text{g}$ at presentation in 16%-23% of patients diagnosed with WD.^{19,58,59} The reference limits for normal 24-hour excretion of copper vary among clinical laboratories. Many laboratories take $40 \mu\text{g}/24$ hours ($0.6 \mu\text{mol}/24$ hours) as the upper limit of normal. This appears to be a better threshold for diagnosis.^{53,82}

Interpreting 24-hour urinary copper excretion can be difficult due to overlap with findings in other types of liver disease, and heterozygotes may also have intermediate levels.⁸⁰ Patients with certain chronic liver diseases, including autoimmune hepatitis, may have basal 24-hour copper excretion in the range of $100\text{-}200 \mu\text{g}/24$ hours ($1.6\text{-}3.2 \mu\text{mol}/24$ hours).⁸³ In one study of patients with chronic active liver disease, five of 54 patients had urinary copper excretion above $100 \mu\text{g}/24$ hours⁸⁴; overlap has also been reported in children with autoimmune hepatitis.⁷⁴

Urinary copper excretion with D-penicillamine administration may be a useful diagnostic adjunctive test. This test has only been standardized in a pediatric population⁵⁷ in which 500 mg of D-penicillamine was administered orally at the beginning and again 12 hours later during the 24-hour urine collection, irrespective of body weight. Compared to a spectrum of other liver diseases including autoimmune hepatitis, primary sclerosing cholangitis and acute liver failure, a clear differentiation was found when $>1600 \mu\text{g}$ copper/24 hours ($>25 \mu\text{mol}/24$ hours) was excreted. Recent reevaluation of the penicillamine challenge test in children found it valuable for the diagnosis of WD in patients with active liver disease (sensitivity 92%) but poor for excluding the diagnosis in asymptomatic siblings (sensitivity only 46%).⁸⁵ Others have found the predictive value of the $25 \mu\text{mol}/24$ hours cut-off to be $<100\%$.^{86,87} This test has been used in adults, but many of the reported results of this test in adults used different dosages and timing for administration of D-penicillamine.^{19,80,83}

Measurement of the basal 24-hour urinary excretion of copper forms part of the assessment to screen siblings for WD, but it has not been validated as the sole test for screening.

Recommendations:

5. Basal 24-hour urinary excretion of copper should be obtained in all patients in whom the diagnosis of WD is being considered. The amount of copper excreted in the 24-hour period is typically $>100 \mu\text{g}$ ($1.6 \mu\text{mol}$) in symptomatic patients, but finding $>40 \mu\text{g}$ ($>0.6 \mu\text{mol}$ or $>600 \text{nmol}$) may indicate WD and requires further investigation (Class I, Level B).

6. Penicillamine challenge studies may be performed for the purpose of obtaining further evidence for the

diagnosis of WD in symptomatic children if basal urinary copper excretion is $<100 \mu\text{g}/24$ hours ($1.6 \mu\text{mol}/24$ hours). Values for the penicillamine challenge test of $>1600 \mu\text{g}$ copper/24 hours ($>25 \mu\text{mol}/24$ hours) following the administration of 500 mg of D-penicillamine at the beginning and again 12 hours later during the 24-hour urine collection are found in patients with Wilson disease. The predictive value of this test in adults is unknown (Class I, Level B).

Hepatic Parenchymal Copper Concentration. Hepatic copper content $\geq 250 \mu\text{g}/\text{g}$ dry weight remains the best biochemical evidence for WD. However, this threshold value has been criticized as being too high and based on relatively few cases: based on analysis of 114 genetically proven cases, a threshold value of $70 \mu\text{g}/\text{g}$ dry weight has been suggested to increase sensitivity dramatically albeit with some loss of specificity.⁸⁸ In another large series, all patients studied had at least $95 \mu\text{g}/\text{g}$ dry weight, and all but 8% had parenchymal concentrations $\geq 250 \mu\text{g}/\text{g}$ dry weight.⁵⁶ Normal concentrations rarely exceed $50 \mu\text{g}/\text{g}$ dry weight of liver. The concentration of hepatic copper in heterozygotes, although frequently elevated above normal, does not exceed $250 \mu\text{g}/\text{g}$ dry weight. In long-standing cholestatic disorders, hepatic copper content may also be increased above this level. Markedly elevated levels of hepatic copper may also be found in idiopathic copper toxicosis syndromes such as Indian childhood cirrhosis.⁵⁷

Biopsies for quantitative copper determination should be taken with a disposable suction or cutting needle and placed dry in a copper-free container. A core (or part of a biopsy core) of liver should be dried overnight in a vacuum oven or, preferably, frozen immediately and kept frozen for shipment to a laboratory for quantitative copper determination. Paraffin-embedded specimens can also be analyzed for copper content.

The major problem with hepatic parenchymal copper concentration is that in later stages of WD, distribution of copper within the liver is often inhomogeneous. In extreme cases, nodules lacking histochemically detectable copper are found next to cirrhotic nodules with abundant copper. Thus, the concentration can be underestimated due to sampling error. In a pediatric study, sampling error was sufficiently common to render this test unreliable in patients with cirrhosis and clinically evident WD.⁵⁷ In general, the accuracy of measurement is improved with adequate specimen size: at least 1-2 cm of biopsy core length should be submitted for analysis.⁸⁹ Technical problems associated with obtaining a liver biopsy in a patient with decompensated cirrhosis or severe coagulopathy have largely been circumvented by the advent of

the transjugular liver biopsy. However, the measurement of hepatic parenchymal copper concentration is most important in younger patients in whom hepatocellular copper is mainly cytoplasmic and thus undetectable by routine histochemical methods.

Radiocopper Study. In patients with WD who have a normal serum ceruloplasmin, radiocopper incorporation into this protein is significantly reduced compared with normal individuals and most heterozygotes. The failure to incorporate copper into the plasma protein within the hepatocyte occurs in all homozygotes with the disease. This test is now rarely used because of the difficulty in obtaining isotope. An experimental alternative to using radiocopper is the use of ^{65}Cu , a nonradioactive isotope for copper which can be detected by mass spectroscopic methods⁹⁰; however, this methodology has difficulty in distinguishing heterozygotes from patients and is not routinely available.

Recommendation:

7. Hepatic parenchymal copper content >250 $\mu\text{g/g}$ dry weight provides critical diagnostic information and should be obtained in cases where the diagnosis is not straightforward and in younger patients. In untreated patients, normal hepatic copper content (<40-50 $\mu\text{g/g}$ dry weight) almost always excludes a diagnosis of WD. Further diagnostic testing is indicated for patients with intermediate copper concentrations (70-250 $\mu\text{g/g}$ dry weight) especially if there is active liver disease or other symptoms of WD (Class I, Level B).

Liver Biopsy Findings. The earliest histological abnormalities in the liver include mild steatosis (both microvesicular and macrovesicular), glycogenated nuclei in hepatocytes, and focal hepatocellular necrosis.⁹¹⁻⁹³ The liver biopsy may show classic histological features of autoimmune hepatitis. With progressive parenchymal damage, fibrosis and subsequently cirrhosis develop.⁹⁴ Cirrhosis is frequently found in most patients by the second decade of life. It is usually macronodular, although occasionally micronodular. There are some older individuals who do not appear to have cirrhosis even after this time, though they have neurologic disease; however, their hepatic histology is not normal.¹⁹ In the setting of acute liver failure due to WD, there is marked hepatocellular degeneration and parenchymal collapse, typically on the background of cirrhosis. Apoptosis of hepatocytes is a prominent feature with acute liver failure due to WD.⁹⁵

Detection of copper in hepatocytes by routine histochemical evaluation is highly variable. In early stages of the disease, copper is mainly in the cytoplasm bound to metallothionein and is not histochemically detectable; in

later stages, copper is found predominantly in lysosomes.⁹⁶ The amount of copper varies from nodule to nodule in cirrhotic liver and may vary from cell to cell in precirrhotic stages. The absence of histochemically identifiable copper does not exclude WD, and this test has a poor predictive value for screening for WD.⁹⁷ Copper-binding protein can be stained by various methods, including the rhodanine or orcein stain. The more sensitive Timms sulfur stain for copper binding protein is not routinely applied.⁹⁶

Ultrastructural analysis of liver specimens at the time steatosis is present reveals specific mitochondrial abnormalities.^{98,99} Specific patterns of mitochondrial abnormalities may be visible among affected family members.¹⁰⁰ Typical findings include variability in size and shape, increased density of the matrix material, and numerous inclusions including lipid and fine granular material which may be copper.¹⁰¹ The most striking alteration is increased intracrystal space with dilatation of the tips of the cristae, creating a cystic appearance. In the absence of cholestasis, these changes are considered to be essentially pathognomonic of WD. With adequate chelation treatment, these changes may resolve.¹⁰² At later stages of the disease, dense deposits within lysosomes are present. Ultrastructural analysis may be a useful adjunct for diagnosis in helping to distinguish between heterozygous carriers and patients, but if not routine, it requires advanced planning so that part of the specimen is placed in the proper preservative when biopsy is performed.

Development of hepatocellular carcinoma was regarded as rare with WD, but recent reports suggest it occurs in WD more frequently than appreciated.¹⁰³⁻¹⁰⁸ A case of cholangiocarcinoma complicating WD has been reported.⁵⁶ Screening for hepatocellular carcinoma has not been recommended for patients with WD; cost effectiveness of screening in this population needs to be examined prospectively, at least for those with cirrhosis at the time of presentation.

Neurologic Findings and Radiologic Imaging of the Brain. Neurologic disease may manifest as motor abnormalities with Parkinsonian characteristics of dystonia, hypertonia, and rigidity, either choreic or pseudosclerotic, with tremors and dysarthria. Disabling symptoms include muscle spasms, which can lead to contractures, dysarthria and dysphonia, and dysphagia. Rare patients present with polyneuropathy¹⁰⁹ or dysautonomia.¹¹⁰ At this stage of disease, magnetic resonance (MR) imaging of the brain or computed tomography (CT) may detect structural abnormalities in the basal ganglia. Most frequently found are increased density on CT and hyperintensity on T2 MR imaging in the region of the basal ganglia. MR imaging may be more sensitive in detecting these lesions. Abnor-

mal findings are not limited to this region, and other abnormalities have been described. Significant abnormalities on brain imaging may even be present in some individuals prior to the onset of symptoms.^{111,112}

Neurologic evaluation should be performed on all patients with WD. Consultation with a neurologist or movement disorder specialist should be sought for evaluation of patients with evident neurologic symptoms before treatment or soon after treatment is initiated. A specific rating scale based on that for Huntington disease was used to evaluate patients with WD in clinical trials; however, this has never been tested outside of this research setting.^{113,114}

Recommendation:

8. Neurologic evaluation and radiologic imaging of the brain, preferably by MR imaging, should be considered prior to treatment in all patients with neurologic WD and should be part of the evaluation of any patient presenting with neurological symptoms consistent with WD (Class I, Level C).

Genetic Studies. Molecular genetic studies are becoming available for clinical use. Pedigree analysis using haplotypes based on polymorphisms surrounding the WD gene is commercially available from specific clinical laboratories. This analysis requires the identification of a patient within the family (the proband) by clinical and biochemical studies as above. After the mutation or haplotype, based on the pattern of dinucleotide and trinucleotide repeats around *ATP7B*, is determined in the proband, the same specific regions of the DNA from first-degree relatives can be tested to determine whether they are unaffected, heterozygous, or indeed patients.¹¹⁵⁻¹¹⁸ Prenatal testing can also be performed^{119,120} but has limited application clinically because diagnosis early in life allows appropriate timing for treatment.¹²¹

Direct mutation analysis is currently feasible. Interpretation of results can sometimes be difficult because most patients are compound heterozygotes with a different mutation on each allele. Currently, more than 300 mutations of *ATP7B* have been identified, but not all gene changes have been established as causing disease (see www.medgen.med.ualberta.ca/database.html for updated catalog). Mutation analysis is an especially valuable diagnostic strategy for certain well-defined populations exhibiting a limited spectrum of *ATP7B* mutations. Some populations with a single predominant mutation include: Sardinian,¹²² Icelandic,¹²³ Korean,¹²⁴ Japanese,¹²⁵ Taiwanese,¹²⁶ Spanish¹²⁷ and in the Canary Islands.⁸² Similar mutations are found in Brazil as in the Canary Islands.¹²⁸ Certain populations in Eastern Europe also show predominance of the H1069Q mutation.^{127,129,130}

Genotype-to-phenotype correlations in WD are hampered by the high prevalence of compound heterozygotes and the relative paucity of homozygotes. Studies in homozygotes suggest that mutations affecting critical portions of the protein, including copper-binding domains or the ATPase loop, may lead to early onset of hepatic disease,¹³¹ but strict concordance is difficult to prove.^{118,132} In general, convincing genotype-phenotype correlations remain elusive.⁵⁶

Recommendation:

9. Mutation analysis by whole-gene sequencing is possible and should be performed on individuals in whom the diagnosis is difficult to establish by clinical and biochemical testing. Haplotype analysis or specific testing for known mutations can be used for family screening of first-degree relatives of patients with WD. A clinical geneticist may be required to interpret the results (Class I, Level B).

Diagnostic Considerations in Specific Target Populations

“Mimic” Liver Diseases. Patients with WD, especially younger ones, may have clinical features and histologic findings on liver biopsy indistinguishable from autoimmune hepatitis.²⁴⁻²⁶ All children with apparent autoimmune hepatitis and any adult patient with the presumptive diagnosis of autoimmune hepatitis failing to respond rapidly and appropriately to corticosteroid treatment must be carefully evaluated for WD. Occasional patients with WD may benefit from a brief course of treatment with corticosteroids along with appropriate specific treatment for WD.²⁶ In some patients concurrent WD and autoimmune hepatitis cannot be excluded.¹³³ Hepatic steatosis in WD is rarely as severe as in nonalcoholic fatty liver disease (NAFLD). Nevertheless, occasional patients with WD closely resemble NAFLD or may have both diseases.

Acute Liver Failure. Most patients with the acute failure presentation of WD have a characteristic pattern of clinical findings¹³⁴⁻¹³⁹:

- Coombs-negative hemolytic anemia with features of acute intravascular hemolysis;
- Coagulopathy unresponsive to parenteral vitamin K administration;
- Rapid progression to renal failure;
- Relative modest rises in serum aminotransferases (typically <<2000 IU/L) from the beginning of clinical illness;
- Normal or markedly subnormal serum alkaline phosphatase (typically <40 IU/L)²⁶;
- Female:male ratio of 2:1.

A high level of clinical suspicion is essential for the diagnosis; simple indices of laboratory findings do not reliably distinguish patients with acute liver failure due to WD from those with acute liver failure due to viral infection or drug toxicity.¹⁴⁰ The relatively modest elevations of serum aminotransferase activity seen in most of these individuals compared with acute liver failure of other etiologies often leads to an underestimate of the severity of the disease. Serum ceruloplasmin is usually decreased, but the predictive value of this test in the setting of acute liver failure is poor (M.L. Schilsky, unpublished observations). Serum copper and 24-hour urinary excretion of copper are greatly elevated. The serum copper is usually >200 $\mu\text{g/dL}$ or >31.5 $\mu\text{mol/L}$ (M.L. Schilsky, unpublished observations). In many facilities, these results are not available in a timely manner, and diagnosis has to rest on clinical features. Kayser-Fleischer rings may be identified to support the diagnosis of WD but may be absent in 50% of these patients. Other findings, such as lunulae ceruleae, are rarely detected but should suggest further evaluation to exclude WD. Expedient diagnosis is critically important because these patients require urgent liver transplantation to survive. In some patients with acute liver failure due to WD, the serum aspartate aminotransferase (AST) level may be higher than the serum alanine aminotransferase (ALT) level, potentially reflecting mitochondrial damage, but this finding is not sufficiently invariable to be diagnostic.^{54,62,141} A more common finding in this setting is the low level of serum alkaline phosphatase activity and a ratio of alkaline phosphatase (in international units per liter) to total bilirubin (in milligrams per deciliter) of <2.¹⁴¹ A prognostic index to be applied at the time of diagnosis of acute liver failure due to WD that may be helpful to predict survival without liver transplant has been developed based on total serum bilirubin, AST, and prolongation of prothrombin time¹⁴²; although it defines extreme cases adequately, it does not reliably discriminate between survivors and nonsurvivors in patients with moderately severe disease. This index has recently been revised (and now includes white blood count and serum albumin) and may provide a more informative assessment.⁸⁶

Because this is usually the first presentation of WD in the patient, underlying liver disease is not suspected, though cirrhosis is typically present.⁵⁴ It is thought that an intercurrent illness such as a viral infection¹⁴³ or drug toxicity may touch off this rapidly progressive liver disease. Rare patients have acute liver failure from viral hepatitis and are found at that time to have underlying WD.^{144,145}

Patients with acute liver failure due to WD are appropriately afforded the highest category of priority for liver transplantation by the United Network for Organ Shar-

ing, status 1A, despite the recognition of the underlying chronic liver injury in these patients.⁵⁴

Recommendations:

10. Patients in the pediatric age bracket who present a clinical picture of autoimmune hepatitis should be investigated for WD (Class I, Level B).

11. Adult patients with atypical autoimmune hepatitis or who respond poorly to standard corticosteroid therapy should also be investigated for WD (Class I, Level C).

12. WD should be considered in the differential diagnosis of patients presenting with nonalcoholic fatty liver disease or have pathologic findings of non-alcoholic steatohepatitis (Class IIb, Level C).

13. WD should be suspected in any patient presenting with acute hepatic failure with Coombs-negative intravascular hemolysis, modest elevations in serum aminotransferases, or low serum alkaline phosphatase and ratio of alkaline phosphatase to bilirubin of <2 (Class I, Level B).

Family Screening. First-degree relatives of any patient newly diagnosed with WD must be screened for WD (Fig. 3). Assessment should include: brief history relating to jaundice, liver disease, and subtle features of neurological involvement; physical examination; serum copper, ceruloplasmin, liver function tests including aminotransferases, albumin, and conjugated and unconjugated bilirubin; slit-lamp examination of the eyes for Kayser-Fleischer rings; and basal 24-hour urinary copper. Individuals without Kayser-Fleischer rings who have subnormal ceruloplasmin and abnormal liver tests undergo liver biopsy to confirm the diagnosis. If available, molecular testing for *ATP7B* mutations or haplotype studies should be obtained and may be used as primary screening. Treatment should be initiated for all individuals greater than 3 years old identified as patients by family screening.

Newborn Screening. Measurement of ceruloplasmin in Guthrie dried-blood spots or urine samples from newborns may promote detection of individuals affected with WD, but further refinement of methodology involving immunologic measurement of ceruloplasmin is required before wide-scale implementation can be advised.¹⁴⁶⁻¹⁴⁸

Recommendation:

14. First-degree relatives of any patient newly diagnosed with WD must be screened for WD (Class I, Level A).

Treatment

For the first half century following the description of WD, there was no effective treatment for this progres-

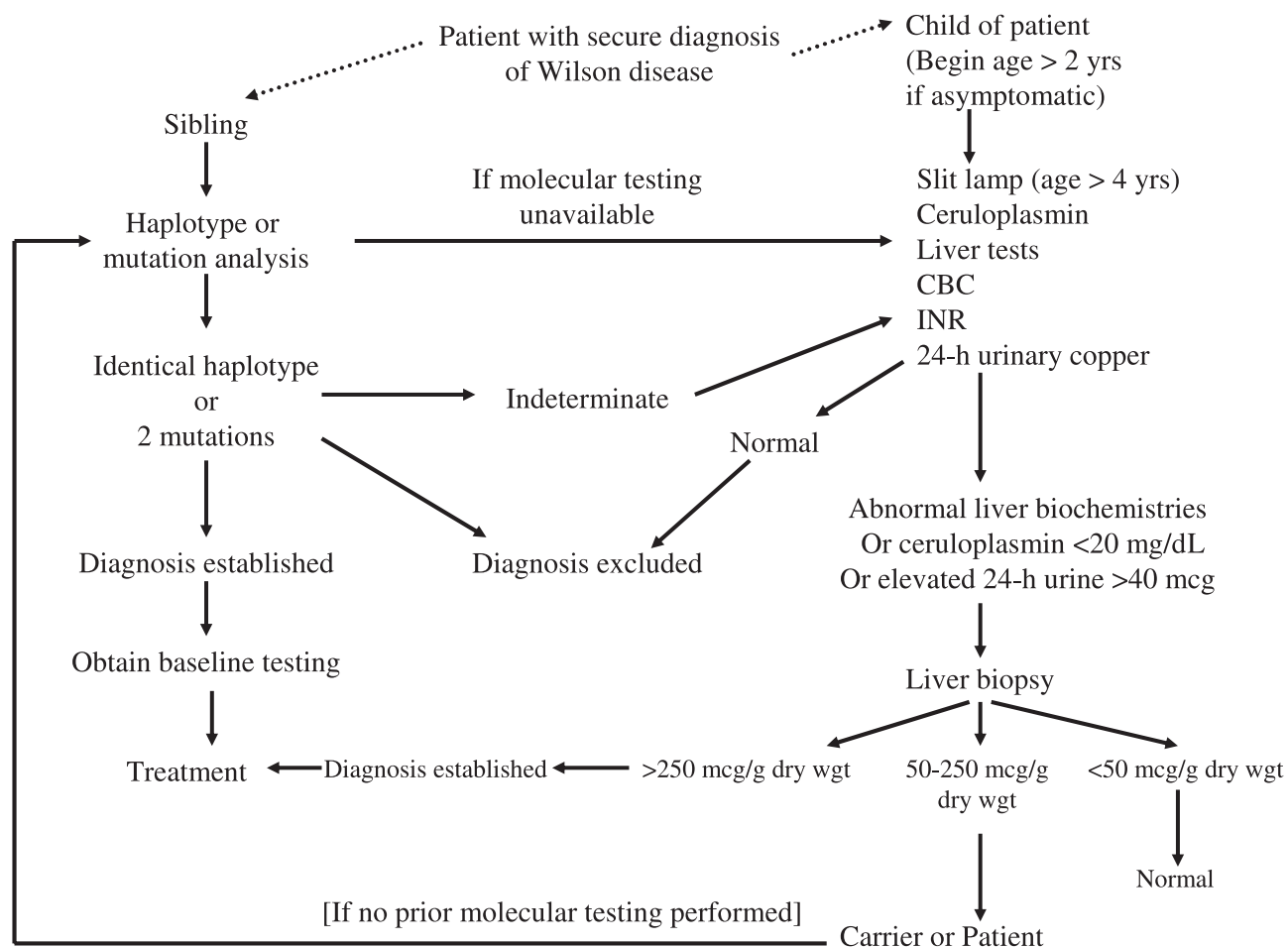


Fig. 3. Screening for Wilson disease (WD) in sibling or child of a patient with secure diagnosis of WD. If molecular testing is available in the index patient, then this is the most efficient screening strategy. If initial screening by blood and urine testing is normal, then consider repeat screening in 2-5 years. Conversion to SI units: CPN <20 mg/dL or 0.2 g/L; 24-hour urinary Cu >40 μ g/day or 0.6 μ mol/day. Abbreviation: KF, Kayser-Fleischer. Baseline testing = complete blood count including platelet count (CBC), liver biochemistries, international normalized ratio (INR), serum ceruloplasmin, 24-hour urine copper excretion; liver biopsy when appropriate.

sively fatal disorder. Because controlled trials were not possible when treatment became available, treatments for WD historically progressed from the intramuscular administration of BAL to the more easily administered oral penicillamine. Although there are studies showing dose response of penicillamine and the resultant cupriuresis, initial clinical use was limited by the availability of the drug itself. Empiric doses were chosen because no formal dose response studies for efficacy over time were carried out. Interestingly, when these treatments initially became available, treatment was first reserved for symptomatic patients because there were no good diagnostic tests available to identify presymptomatic disease. Simultaneous with the advances in diagnostic testing for WD, a new era was ushered in by the recognition that significant morbidity and mortality could be prevented by the treatment of asymptomatic patients.¹⁴⁹ The development of alternative agents to penicillamine was stimulated by the inability

of some patients to tolerate this drug. Trientine was developed and introduced specifically for patients who developed adverse reactions to penicillamine. Zinc was developed separately, as was TM which was used by veterinarians for copper poisoning in animals. Today, the mainstay of treatment for WD remains lifelong pharmacologic therapy; liver transplantation, which corrects the underlying hepatic defect in WD, is reserved for severe or resistant cases.

In general, the approach to treatment is dependent on whether there is clinically-evident disease or laboratory or histological evidence of aggressive inflammatory injury, whether neurologic or hepatic, or whether the patient is identified prior to the onset of clinical symptoms. We believe this distinction helps in determining the choice of therapy and the dosages of medications utilized, although there are no studies in which this approach has been systematically explored. The recommended initial treatment

Table 3. Pharmacological Therapy for Wilson Disease

Drug	Mode of Action	Neurological Deterioration	Side Effects	Comments
D-Penicillamine	General chelator induces cupruria	10%-20% during initial phase of treatment	<ul style="list-style-type: none"> • Fever, rash, proteinuria, lupus-like reaction • Aplastic anemia • Leukopenia • Thrombocytopenia • Nephrotic syndrome • Degenerative changes in skin • Elastosis perforans serpingosa • Serous retinitis • Hepatotoxicity 	<p>Reduce dose for surgery to promote wound-healing and during pregnancy</p> <p>Maximum dose 20 mg/kg/day; reduce by 25% when clinically stable</p>
Trientine	General chelator induces cupruria	10%-15% during initial phase of treatment	<ul style="list-style-type: none"> • Gastritis • Aplastic anemia rare • Sideroblastic anemia 	<p>Reduce dose for surgery to promote wound-healing and during pregnancy</p> <p>Maximum dose 20 mg/kg/day; reduce by 25% when clinically stable</p>
Zinc	Metallothionein inducer, blocks intestinal absorption of copper	Can occur during initial phase of treatment	<ul style="list-style-type: none"> • Gastritis; biochemical pancreatitis • Zinc accumulation • Possible changes in immune function 	<p>No dosage reduction for surgery or pregnancy</p> <p>Usual dose in adults: 50 mg elemental Zn three times daily; <i>minimum</i> dose in adults: 50 mg elemental Zn twice daily</p>
Tetrathiomolybdate	Chelator, blocks copper absorption	Reports of rare neurologic deterioration during initial treatment	<ul style="list-style-type: none"> • Anemia; neutropenia • Hepatotoxicity 	Experimental in the United States and Canada

of symptomatic patients or those with active disease is with chelating agents, though there are some reports showing primary treatment with zinc may be adequate for some individuals. The largest treatment experience worldwide is still with D-penicillamine; however, there is now more frequent consideration of trientine for primary therapy. Data now exist that show the efficacy of trientine in treating patients with decompensated neurologic or hepatic disease. Previous limitations to the use of trientine were its limited supply and concerns about its continued availability; many clinicians lack experience with this medication. Combination therapy, in which zinc is used in conjunction with a chelating agent (temporally separated), has a theoretical basis in both blocking copper uptake and eliminating excess copper. There are some reports of the simultaneous use of chelators and zinc as primary therapy, and future studies are needed to determine whether efficacy is greater than with chelator therapy alone. Studies of the use of TM as an alternative chelating agent for the initial treatment of neurologic WD suggest that this drug may be useful as initial therapy for patients presenting with neurological symptoms.

Once disease symptoms or biochemical abnormalities have stabilized, typically in 2-6 months after initiation of therapy,²⁵ maintenance dosages of chelators or zinc therapy can be used for treatment. Patients presenting without symptoms may be treated with either maintenance

dosages of a chelating agent or with zinc from the outset. Failure to comply with lifelong therapy has led to recurrent symptoms and liver failure, the latter requiring liver transplantation for survival. Monitoring of therapy includes monitoring for compliance as well as for potential treatment-induced side effects.

Available Treatments:

Available treatments are listed in Table 3.

D-Penicillamine. Penicillamine was introduced as the first oral agent for treating WD in 1956.¹⁵ It was identified as a breakdown product of penicillin but is actually the sulfhydryl-bearing amino acid cysteine doubly-substituted with methyl groups. Like dimercaptopropanol (or BAL) it has a free sulfhydryl group, which functions as the copper chelating moiety. Penicillamine is currently synthesized as such, and contamination with penicillin is not an issue; likewise, the racemic mixture, which tends to interfere with pyridoxine action, is no longer used. Nevertheless, supplemental pyridoxine is still provided at a dosage of 25-50 mg by mouth daily.

The major effect of D-penicillamine in WD is to promote the urinary excretion of copper. D-Penicillamine may also act by inducing metallothionein in individuals with WD.¹⁵⁰ D-Penicillamine also interferes with collagen cross-linking¹⁵¹ and has some immunosuppressant actions.¹⁵² It is a general chelator of metals, is used to treat

cystinosis, and has been used as an immunosuppressant in rheumatoid arthritis.

D-Penicillamine is rapidly absorbed from the gastrointestinal tract with a double-peaked curve for intestinal absorption.¹⁵³⁻¹⁵⁵ Uptake may occur by an unusual mechanism: disulfide binding to the enterocyte membrane followed by pinocytosis. If D-penicillamine is taken with a meal, its absorption is decreased overall by about 50%.^{155,156} Total bioavailability is estimated at 40%-70%.^{154,157} Once absorbed, 80% of D-penicillamine circulates bound to plasma proteins; there is little free D-penicillamine in the plasma, because it forms inactive dimers or binds to cysteine. Greater than 80% of D-penicillamine excretion is via the kidneys. The excretion half-life of D-penicillamine is on the order of 1.7-7 hours,^{153,155,157} but there is considerable interindividual variation and D-penicillamine or its metabolites can be found in the urine months after the drug has been discontinued.¹⁵⁸

The initial use of D-penicillamine was for the treatment of symptomatic patients, and numerous studies attest to the effectiveness of D-penicillamine as treatment for WD.^{77,159-164} Worsening of neurologic symptoms has been reported in 10%-50% of those treated with D-penicillamine during the initial phase of treatment.^{165,166} In a recent series, neurologic worsening occurred on all three treatments used for WD, but mainly with D-penicillamine where 13.8% were adversely affected.⁵⁶ For patients with symptomatic liver disease, the time for evidence of recovery of synthetic function and improvement in clinical signs such as jaundice and ascites is typically during the first 2-6 months of treatment, but further recovery can occur during the first year of treatment. Failure to comply with therapy has led to significant progression of liver disease and liver failure in 1-12 months following discontinuation of treatment, resulting in death or necessitating liver transplantation.¹⁶⁷

D-Penicillamine use is associated with numerous side effects. Severe side effects requiring the drug to be discontinued occur in approximately 30% of patients.^{55,76} Early sensitivity reactions marked by fever and cutaneous eruptions, lymphadenopathy, neutropenia or thrombocytopenia, and proteinuria may occur during the first 1-3 weeks. D-Penicillamine should be discontinued immediately if early sensitivity occurs; the availability of alternative medications makes a trial of prednisone cotreatment unnecessary. Late reactions include nephrotoxicity, usually heralded by proteinuria or the appearance of other cellular elements in the urine, for which discontinuation of D-penicillamine should be immediate. Other late reactions include a lupus-like syndrome marked by hematuria, proteinuria, and positive antinuclear antibody, and with

higher dosages of D-penicillamine no longer typically used for treating WD, Goodpasture syndrome. Significant bone marrow toxicity includes severe thrombocytopenia or total aplasia. Dermatological toxicities reported include progeric changes in the skin and elastosis perforans serpiginosa,¹⁶⁸ and pemphigous or pemphigoid lesions, lichen planus, and aphthous stomatitis. Very late side effects include nephrotoxicity, severe allergic response upon restarting the drug after it has been discontinued, myasthenia gravis, polymyositis, loss of taste, immunoglobulin A depression, and serous retinitis. Hepatotoxicity has been reported.¹⁶⁹ Hepatic siderosis has been reported in treated patients with reduced levels of serum ceruloplasmin and non-ceruloplasmin bound copper.¹⁷⁰

Tolerability of D-penicillamine may be enhanced by starting with incremental doses, 250-500 mg/day, increased by 250 mg increments every 4-7 days to a maximum of 1000-1500 mg/day in 2-4 divided dosages. Maintenance dose is usually 750-1000 mg/day administered in two divided doses. Dosing in the child is 20 mg/kg/day rounded off to the nearest 250 mg and given in two or three divided doses. D-Penicillamine is best administered 1 hour prior to or 2 hours after meals, because food inhibits its absorption. Closer proximity to meals is acceptable if it ensures compliance. Apart from numerous adverse side effects detailed above, another feature of treatment with D-penicillamine is that the serum ceruloplasmin may decrease after initiation of treatment. Serum ceruloplasmin may then either remain low or increase over the term of chronic treatment, the latter occurring in some patients with severe hepatic insufficiency as they recover synthetic function in response to treatment. In contrast, decrease in serum ceruloplasmin levels in patients treated chronically with penicillamine may be a sign of excessive copper depletion and often is associated with neutropenia, sideroblastic anemia, and hemosiderosis.

Adequacy of treatment is monitored by measuring 24-hour urinary copper excretion while on treatment. This is highest immediately after starting treatment and may exceed 1000 μg (16 μmol) per day at that time. With chronic (maintenance) treatment, urinary copper excretion should run in the vicinity of 200-500 μg (3-8 μmol) per day on treatment. In addition, estimate of non-ceruloplasmin bound copper shows normalization of the non-ceruloplasmin bound copper concentration with effective treatment.

Values of urine copper excretion below 200 $\mu\text{g/day}$ (3.2 $\mu\text{mol/day}$) may indicate either nonadherence to therapy or overtreatment and excess copper removal. In those with nonadherence to therapy, non-ceruloplasmin bound copper is elevated ($>15 \mu\text{g/dL}$ or $>150 \mu\text{g/L}$),

while with overtreatment, values are very low ($<5 \mu\text{g/dL}$ or $<50 \mu\text{g/L}$).

Trientine. Trientine (triethylene tetramine dihydrochloride or 2,2,2-tetramine, also known by its official short name trien) is one of a family of chelators with a polyamine-like structure chemically distinct from penicillamine. It lacks sulfhydryl groups and copper is chelated by forming a stable complex with the four constituent nitrogens in a planar ring.

Trientine was introduced in 1969 as an alternative to penicillamine. Few data exist about the pharmacokinetics of trientine. It is poorly absorbed from the gastrointestinal tract, and what is absorbed is metabolized and inactivated.^{171,172} About 1% of the administered trientine and about 8% of the biotransformed trientine metabolite, acetyltrien, ultimately appears in the urine. The acetyltrien is a less effective chelator than trientine. The amounts of urinary copper, zinc and iron increase in parallel with the amount of trientine excreted in the urine.¹⁷³

Like penicillamine, trientine promotes copper excretion by the kidneys. Whether trientine is a weaker chelator of copper than penicillamine is controversial^{160,174,175} and dose adjustments can compensate for small differences. Trientine and penicillamine may mobilize different pools of body copper.¹⁷⁴

Trientine is effective treatment for WD^{167,176} and is indicated especially in patients who are intolerant of penicillamine or have clinical features indicating potential intolerance (history of renal disease of any sort, congestive splenomegaly causing severe thrombocytopenia, autoimmune tendency). Neurological worsening after beginning treatment with trientine has been reported but appears much less common than with penicillamine. Trientine has also been shown to be effective initial therapy for patients, even with decompensated liver disease at the outset.^{177,178}

Trientine has few side effects. No hypersensitivity reactions have been reported although a fixed cutaneous drug reaction was observed in one patient. Pancytopenia has rarely been reported. Trientine also chelates iron, and coadministration of trientine and iron should be avoided because the complex with iron is toxic. A reversible sideroblastic anemia may be a consequence of overtreatment and resultant copper deficiency. Lupus-like reactions have also been reported in some WD patients treated with trientine; however, these patients were almost all uniformly treated previously with penicillamine, so the true frequency of this reaction when trientine is used *de novo* is unknown. In general, adverse effects due to penicillamine resolve when trientine is substituted for penicillamine and do not recur during prolonged treatment with trientine. Use in patients with primary biliary cirrhosis revealed that

trientine may cause hemorrhagic gastritis, loss of taste, and rashes.¹⁷⁹ Recent evidence suggests that copper deficiency induced by trientine can result in iron overload in livers of patients with WD, similar to that observed for penicillamine.¹⁸⁰

Typical dosages are 750-1500 mg/day in two or three divided doses, with 750 or 1000 mg used for maintenance therapy. In children, the weight-based dose is not established, but the dose generally used is 20 mg/kg/day rounded off to the nearest 250 mg, given in two or three divided doses. Trientine should be administered 1 hour before or 2 hours after meals. Taking it closer to meals is acceptable if this ensures compliance. Trientine tablets are not stable for prolonged periods at high ambient temperatures, which is a problem for patients traveling to warm climates.

Adequacy of treatment is monitored by measuring 24-hour urinary copper excretion while on treatment. This should run in the vicinity of 200-500 μg (3-8 μmoles) per day on maintenance treatment but may be higher when treatment is first started. Additionally, estimate of non-ceruloplasmin bound copper may show normalization of the non-ceruloplasmin bound copper concentration with effective treatment.

Values of urine copper excretion below 200 $\mu\text{g/day}$ (3.2 $\mu\text{mol/day}$) may indicate either nonadherence to therapy or overtreatment and excess copper removal. In those with nonadherence to therapy, non-ceruloplasmin bound copper is elevated ($>15 \mu\text{g/dL}$ or $>150 \mu\text{g/L}$), whereas with overtreatment, values are very low ($<5 \mu\text{g/dL}$ or $<50 \mu\text{g/L}$).

Zinc. Zinc was first used to treat WD by Schouwink in Holland in the early 1960s.^{181,182} Its mechanism of action is different from that of penicillamine and trientine: zinc interferes with the uptake of copper from the gastrointestinal tract. Zinc induces enterocyte metallothionein, a cysteine-rich protein that is an endogenous chelator of metals. Metallothionein has greater affinity for copper than for zinc and thus preferentially binds copper present in the enterocyte and inhibits its entry into the portal circulation. Once bound, the copper is not absorbed but is lost into the fecal contents as enterocytes are shed in normal turnover.¹⁸³ Because copper also enters the gastrointestinal tract from saliva and gastric secretions, zinc treatment can generate a negative balance for copper and thereby remove stored copper.¹⁸⁴ Zinc may also act by inducing levels of hepatocellular metallothionein.¹⁸⁵⁻¹⁸⁷

Zinc has very few side effects. Gastric irritation is the main problem and may be dependent on the salt employed. Hepatic deterioration has been occasionally reported when zinc was commenced and was fatal in one

case.^{188,189} Zinc may have immunosuppressant effects and reduce leukocyte chemotaxis, but one study found no adverse effect on lymphocyte function with chronic use.¹⁹⁰ Elevations in serum lipase and/or amylase may occur, without clinical or radiologic evidence of pancreatitis. Neurological deterioration is uncommon with zinc.^{164,183} Whether high-dose zinc is safe for patients with impaired renal function is not yet established.

Although zinc is currently reserved for maintenance treatment, it has been used as first-line therapy, most commonly for asymptomatic or presymptomatic patients. It appears to be equally effective as penicillamine but much better tolerated.¹⁶⁴ Reports of large studies of adults with WD indicate good efficacy.^{114,182} A child who presented with ascites and coagulopathy was effectively treated only with zinc¹⁹¹; a few other favorable reports have appeared in children¹⁹² and in adults.¹⁹³ Combination treatment with trientine plus zinc or penicillamine plus zinc in which the chelator and the zinc are given at widely spaced intervals during the day has been advocated but not yet reported in rigorously designed series.

Dosing is in milligrams of *elemental* zinc. For larger children and adults, 150 mg/day is administered in three divided doses. Compliance with the three times per day dosage may be problematic, and it has to be taken at least twice daily to be effective.¹¹⁴ The actual salt used does not make a difference with respect to efficacy but may affect tolerability. With respect to gastrointestinal side effects, acetate and gluconate may be more tolerable than sulfate, but this varies with individuals. For smaller children, <50 kg in body weight, the dose is 75 mg/day in three divided doses,¹⁹⁴ and the dose is not well defined for children under 5 years of age. Taking zinc with food interferes with zinc absorption¹⁹⁵ and effectiveness of treatment, but dose adjustments can be employed to compensate for this effect if taking zinc around mealtime assures compliance.

Adequacy of treatment with zinc is judged by clinical and biochemical improvement and by measuring 24-hour urinary excretion of copper, which should be less than 75 μg (1.2 μmol) per 24 hours on stable treatment. Additionally, estimate of non-ceruloplasmin bound copper shows normalization of the non-ceruloplasmin bound copper concentration with effective treatment. Urinary excretion of zinc may be measured from time to time to check compliance.

Antioxidants. Antioxidants, mainly vitamin E, may have a role as adjunctive treatment. Serum and hepatic vitamin E levels have been found to be low in WD.¹⁹⁶⁻²⁰⁰ Symptomatic improvement when vitamin E was added to the treatment regimen has been occasionally reported but no rigorous studies have been conducted. One study sug-

gests no correlation of antioxidant deficiency with clinical symptoms.¹⁹⁹

Diet. Foods with very high concentrations of copper (shellfish, nuts, chocolate, mushrooms, and organ meats) generally should be avoided, at least in the first year of treatment. Diets deficient in copper may delay the onset of the disease and control disease progression, but dietary management is not recommended as sole therapy.²⁰¹ Consultation with a dietitian is advisable for practicing vegetarians. Well water or water brought into the household through copper pipes should be checked for copper content, but in general, municipal water supplies do not have to be checked. A water purifying system may be advisable if the copper content of the water is high. For those with copper pipes, it is important to flush the system of stagnant water before using water for cooking or consumption. Copper containers or cookware should not be used to store or prepare foods or drinks.

Ammonium Tetrathiomolybdate. TM is a very strong decoppering agent which works by two mechanisms: interfering with intestinal uptake of copper (if administered with meals) and binding copper from plasma (when taken between meals). At low doses, TM removes copper from metallothionein, but at higher doses it forms an insoluble copper complex, which is deposited in the liver.²⁰² TM remains an experimental therapy in the United States, and it is not commercially available. Recent data indicate its utility because it does not cause neurological deterioration.^{203,204} Potential adverse effects include bone marrow depression,²⁰⁵ hepatotoxicity,²⁰⁶ and overly aggressive copper removal which causes neurological dysfunction. TM also has antiangiogenic effects due to its extensive decoppering effect.²⁰⁷⁻²⁰⁹

Treatment in Specific Clinical Situations:

Asymptomatic Patients. For asymptomatic or presymptomatic patients identified through family screening, treatment with a chelating agent, such as D-penicillamine^{149,210} or with zinc is effective in preventing disease symptoms or progression.²¹¹ Zinc appears preferable for presymptomatic children under the age of 3 years.

Maintenance Therapy. After adequate treatment with a chelator, stable patients may be continued on a lower dosage of the chelating agent (as noted above) or shifted to treatment with zinc. In general, such patients will have been treated for 1-5 years. They will be clinically well, with normal serum aminotransferase levels and hepatic synthetic function, non-ceruloplasmin bound copper concentration in the normal range, and 24-hour urinary copper repeatedly in the range of 200-500 $\mu\text{g}/\text{day}$ (3-8 $\mu\text{mol}/\text{day}$) on treatment. The advantages of long-term treatment with zinc include that it is more selective for removing copper than penicilla-

mine or trientine and is associated with few side effects. Adequate studies regarding the timing of this change-over in treatment of adult patients with hepatic WD are not available, and only limited data are available for children.²¹² No matter how well a patient appears, treatment should never be terminated indefinitely. Patients who discontinue treatment altogether risk development of intractable hepatic decompensation.^{167,213}

Recommendations:

15. Initial treatment for symptomatic patients should include a chelating agent (D-penicillamine or trientine). Trientine may be better tolerated (Class I, Level B).

16. Patients should avoid intake of foods and water with high concentrations of copper, especially during the first year of treatment (Class I, Level C).

17. Treatment of presymptomatic patients or those on maintenance therapy can be accomplished with a chelating agent or with zinc. Trientine may be better tolerated (Class I, Level B).

Decompensated Cirrhosis. Patients who present with decompensated chronic liver disease, typically with hypoalbuminemia, prominent coagulopathy, ascites, but no encephalopathy, have recently been treated with a chelator, either D-penicillamine^{86,178} or trientine,²¹⁴ plus zinc. The two types of treatment must be temporally dispersed throughout the day in four dosages, with usually 5-6 hours between administration of either drug, in order to avoid having chelator bind the zinc and thus potentially cancel the efficacy of either modality. A typical regimen is zinc (50 mg elemental, or 25 mg elemental in children) given by mouth as the first and third doses, and trientine (500 mg, or ~10 mg/kg in children) given by mouth as the second and fourth doses. This is fundamentally an intensive induction regimen. Some patients may fail this regimen and require transplantation; therefore, they should be referred to a transplant center promptly. Those who respond may be transitioned to full-dose zinc or full-dose trientine (or D-penicillamine) as monotherapy after 3-6 months. This treatment strategy remains investigational despite some supportive data^{86,178,214} (E.A. Roberts, unpublished observations).

Acute Liver Failure. Patients with acute liver failure due to WD require liver transplantation, which is life-saving.²¹⁵ To help determine which patients with acute hepatic presentations will not survive without liver transplantation, Nazer et al. developed a prognostic score whose components include serum bilirubin, serum aspartate aminotransferase, and prolongation of prothrombin time above normal; patients with a score of 7 or greater did not survive in their series of patients with WD.¹⁴²

Scoring systems have recently been devised for children⁸⁶ and adults²¹⁶ with Wilsonian acute liver failure: both have good predictive values but do not appear to be routinely utilized. Until transplantation can be performed, plasmapheresis and hemofiltration²¹⁷ and exchange transfusion²¹⁸ or hemofiltration²¹⁹ or dialysis may protect the kidneys from copper-mediated tubular damage.^{220,221} Albumin dialysis was shown to stabilize patients with acute liver failure due to WD and delay, but not eliminate, the need for transplantation.²²² The Molecular Adsorbents Recirculating System ultrafiltration device may be efficacious in this setting.²²³⁻²²⁵

Pregnancy. In pregnant women, treatment must be maintained throughout the course of pregnancy for all patients with WD. Interruption of treatment during pregnancy has resulted in acute liver failure.²²⁶ Experience to date indicates the chelating agents (both penicillamine and trientine)^{172,227-230} and zinc salts^{231,232} have been associated with satisfactory outcomes for the mother and fetus.^{36,233-237} The occurrence of a few birth defects has been noted infrequently in offspring of treated patients; however, the rarity of this disorder has made it difficult to determine whether this is different from the frequency of these defects in the population at large. The dosage of zinc salts is maintained throughout without change; however, dosages of chelating agents should be reduced to the minimum necessary during pregnancy, especially for the last trimester to promote better wound healing if cesarean section is performed. Such a dose reduction might be on the order of 25%-50% of the prepregnancy dose. Patients should be monitored frequently during pregnancy.

Women taking D-penicillamine should not breast-feed because the drug is excreted into breast milk and might harm the infant. Little is known about the safety of trientine and zinc in breast milk.

Liver Transplantation. Liver transplantation is the only effective option for those with WD who present with acute liver failure and is indicated for all patients with WD with decompensated liver disease unresponsive to medical therapy. Liver transplantation corrects the hepatic metabolic defects of WD and may serve to initiate normalization of extrahepatic copper metabolism.²³⁸ One-year survival following liver transplantation ranges from 79%-87%, and those who survive this early period continue to survive in the long term.²³⁹ Although the vast majority of patients undergoing liver transplant for WD have received cadaveric donor organs, living donor transplants can be performed. Successful live donor transplant is possible when the donor is a family member heterozygous for WD.²⁴⁰⁻²⁴³

Less definite indications for liver transplantation exist for patients with respect to severe neurological disease.

Some individuals who undergo transplantation for decompensated cirrhosis have had psychiatric or neurologic symptoms, which improved after liver transplantation.^{239,244} There are also a few reports of other individuals who underwent transplantation for neurologic disease who improved after liver transplantation,²⁴⁵⁻²⁴⁸ but detailed data on the neurologic evaluations of these patients are not available. Liver transplantation is not recommended as a primary treatment for neurologic WD because the liver disease is stabilized by medical therapy in most of these individuals and outcomes with liver transplantation are not always beneficial.^{54,239,249-252} Furthermore, patients with neurological or psychiatric disease due to WD may have poorer outcomes and also difficulties with adherence to medical regimens after liver transplantation.²⁵³

Recommendations:

18. Patients with acute liver failure due to WD should be referred for and treated with liver transplantation immediately (Class I, Level B).

19. Patients with decompensated cirrhosis unresponsive to chelation treatment should be evaluated promptly for liver transplantation (Class I, Level B).

20. Treatment for WD should be continued during pregnancy, but dosage reduction is advisable for D-penicillamine and trientine (Class I, Level C).

21. Treatment is lifelong and should not be discontinued, unless a liver transplant has been performed (Class I, Level B).

Treatment Targets and Monitoring of Treatment.

The goal of treatment monitoring is to confirm clinical and biochemical improvement, ensure compliance with therapy, and identify adverse side effects in a timely fashion. The frequency of monitoring of patients may vary, but at a minimum it should be performed twice a year. More frequent monitoring is needed during the initial phase of treatment, for those experiencing worsening of symptoms or side effects of medications and in individuals suspected of noncompliance with therapy. Physical examinations should look for evidence of liver disease and neurological symptoms. Repeat examination for Kayser-Fleischer rings should be performed if there is a question of patient compliance because their appearance or reappearance in a patient in whom they were absent may portend the onset of symptomatic disease. For patients on penicillamine, cutaneous changes should be sought on physical examination. A careful history should also include questioning for psychiatric symptoms, especially depression.

Laboratory testing should include liver biochemistries including tests of hepatic synthetic function and indices

of copper metabolism (serum copper and ceruloplasmin); the estimated serum non-ceruloplasmin bound copper may provide the best guide to treatment efficacy. Analysis of 24-hour urinary copper excretion while on medication reflects overall exchangeable copper and is helpful for monitoring compliance. Patients taking D-penicillamine or trientine should have 24-hour urinary copper excretion values of 200-500 $\mu\text{g}/\text{day}$ (3-8 $\mu\text{mol}/\text{day}$); for patients on zinc, it should be no more than 75 $\mu\text{g}/\text{day}$ (1.2 $\mu\text{mol}/\text{day}$). For patients on chelation therapy, elevated values for urine copper may suggest nonadherence to treatment, and hepatic deterioration may follow.⁵⁶ Low values for urine copper excretion for patients on chelation treatment can also indicate overtreatment, and this finding is accompanied by very low values for estimates of non-ceruloplasmin bound copper. Neutropenia and anemia, as well as hyperferritinemia, can also be present in these individuals. Patients who have stopped their chelation therapy or are taking subtherapeutic dosages may also have low values for 24-hour urine copper excretion, but these individuals have elevated non-ceruloplasmin bound copper. Compliance in patients taking zinc can also be checked by measuring serum zinc or 24-hour urinary zinc excretion, which should be on the order of 2 mg/24 hours. The total blood count should be monitored in all patients on chelators, and a urinalysis should be performed regularly to assure safety.

Recommendations:

22. For routine monitoring, serum copper and ceruloplasmin, liver biochemistries and international normalized ratio, complete blood count and urinalysis (especially for those on chelation therapy), and physical examination should be performed regularly, at least twice annually. Patients receiving chelation therapy require a complete blood count and urinalysis regularly, no matter how long they have been on treatment (Class I, Level C).

23. The 24-hour urinary excretion of copper while on medication should be measured yearly, or more frequently if there are questions on compliance or if dosage of medications is adjusted. The estimated serum non-ceruloplasmin bound copper may be elevated in situations of nonadherence and extremely low in situations of overtreatment (Class I, Level C).

Acknowledgment: This guideline was produced in collaboration with the Practice Guidelines Committee of the AASLD which provided extensive peer review of the manuscript. Members of the AASLD Practice Guidelines Committee include Margaret C. Shuhart, M.D., M.S., (Committee Chair), Gary L. Davis, M.D. (Board Liaison), Kiran Bambha, M.D., Andres Cardenas, M.D.,

MMSc, Timothy J. Davern, M.D., Christopher P. Day, M.D., Ph.D., Steven-Huy B. Han, M.D., Charles D. Howell, M.D., Lawrence U. Liu, M.D., Paul Martin, M.D., Nancy Reau, M.D., Bruce A. Runyon, M.D., Jayant A. Talwalkar, M.D., M.P.H., John B. Wong, M.D., and Colina Yim, RN, M.N.

References

- Eddy DM. A Manual for Assessing Health Practices and Designing Practice Guidelines. Philadelphia, PA: American College of Physicians; 1996.
- American Gastroenterological Association policy statement on the use of medical practice guidelines by managed care organizations and insurance carriers. *Gastroenterology* 1995;108:925-926.
- Methodology Manual for ACC/AHA Guideline Writing Committees (April 2006). Available at: http://www.americanheart.org/presenter.jhtml?identifier_3039683. Accessed July 2007.
- Shiffman RN, Shekelle P, Overhage JM, Slutsky J, Grimshaw J, Deshpande AM. Standardized reporting of clinical practice guidelines: a proposal from the Conference on Guideline Standardization. *Ann Intern Med* 2003;139:493-498.
- Wilson SAK. Progressive lenticular degeneration: a familial nervous disease associated with cirrhosis of the liver. *Brain* 1912;34:295-507.
- Bearn AG. A genetical analysis of thirty families with Wilson's disease (hepatolenticular degeneration). *Ann Hum Genet* 1960;24:33-43.
- Walshe JM. History of Wilson's disease: 1912 to 2000. *Mov Disord* 2006;21:142-147.
- Bull PC, Thomas GR, Rommens JM, Forbes JR, Cox DW. The Wilson disease gene is a putative copper transporting P-type ATPase similar to the Menkes gene. *Nat Genet* 1993;5:327-337.
- Tanzi RE, Petrukhin K, Chernov I, Pellequer JL, Wasco W, Ross B, et al. The Wilson disease gene is a copper transporting ATPase with homology to the Menkes disease gene. *Nat Genet* 1993;5:344-350.
- Yamaguchi Y, Heiny ME, Gitlin JD. Isolation and characterization of a human liver cDNA as a candidate gene for Wilson disease. *Biochem Biophys Res Commun* 1993;197:271-277.
- Holtzman NA, Gaumnitz BM. Studies on the rate of release and turnover of ceruloplasmin and apoceruloplasmin in rat plasma. *J Biol Chem* 1970;245:2354-2358.
- Frydman M. Genetic aspects of Wilson's disease. *J Gastroenterol Hepatol* 1990;5:483-490.
- Cumings JN. The effect of BAL in hepatolenticular degeneration. *Brain* 1951;74:10-22.
- Denny-Brown D, Porter H. The effect of BAL (2,3 dimercaptopropanol) on hepatolenticular degeneration (Wilson's disease). *New Engl J Med* 1951;245:917-925.
- Walshe JM. Wilson's disease. New oral therapy. *Lancet* 1956;i:25-26.
- Fleischer B. Ueber einer der "Pseudosclerose" nahestehende bisher unbekannte Krankheit (gekennzeichnet durch Tremor, psychische Störungen, braeunliche Pigmentierung bestimmter Gewebe, insbesondere Sucher Hornhauptperipherie, Lebercirrhose). *Deutsch Z Nerven Heilk* 1912;44:179-201.
- Scheinberg IH, Gitlin D. Deficiency of ceruloplasmin in patients with hepatolenticular degeneration (Wilson's disease). *Science* 1952;116:484-485.
- Sternlieb I. Perspectives on Wilson's disease. *HEPATOLOGY* 1990;12:1234-1239.
- Steindl P, Ferenci P, Dienes HP, Grimm G, Pabinger I, Madl C, et al. Wilson's disease in patients presenting with liver disease: a diagnostic challenge. *Gastroenterology* 1997;113:212-218.
- Ferenci P, Caca K, Loudianos G, Mieli-Vergani G, Tanner S, Sternlieb I, et al. Diagnosis and phenotypic classification of Wilson disease. *Liver Int* 2003;23:139-142.
- Koppikar S, Dhawan A. Evaluation of the scoring system for the diagnosis of Wilson's disease in children. *Liver Int* 2005;25:680-681.
- Walshe JM. The liver in Wilson's disease. In: Schiff L, Schiff ER, eds. *Diseases of the Liver*. 6th ed. Philadelphia, PA: J B Lippincott; 1987:1037-1050.
- Saito T. Presenting symptoms and natural history of Wilson disease. *Eur J Pediatr* 1987;146:261-265.
- Scott J, Gollan JL, Samourian S, Sherlock S. Wilson's disease, presenting as chronic active hepatitis. *Gastroenterology* 1978;74:645-651.
- Schilsky ML, Scheinberg IH, Sternlieb I. Prognosis of Wilsonian chronic active hepatitis. *Gastroenterology* 1991;100:762-767.
- Milkiewicz P, Saksena S, Hubscher SG, Elias E. Wilson's disease with superimposed autoimmune features: report of two cases and review. *J Gastroenterol Hepatol* 2000;15:570-574.
- Azizi E, Eshel G, Aladjem M. Hypercalciuria and nephrolithiasis as a presenting sign in Wilson disease. *Eur J Pediatr* 1989;148:548-549.
- Nakada SY, Brown MR, Rabinowitz R. Wilson's disease presenting as symptomatic urolithiasis: a case report and review of the literature. *J Urol* 1994;152:978-979.
- Chu CC, Huang CC, Chu NS. Recurrent hypokalemic muscle weakness as an initial manifestation of Wilson's disease. *Nephron* 1996;73:477-479.
- Golding DN, Walshe JM. Arthropathy of Wilson's disease. Study of clinical and radiological features in 32 patients. *Ann Rheum Dis* 1977;36:99-111.
- Factor SM, Cho S, Sternlieb I, Scheinberg IH, Goldfischer S. The cardiomyopathy of Wilson's disease. Myocardial alterations in nine cases. *Virchows Arch Pathol Anat* 1982;397:301-311.
- Kuan P. Cardiac Wilson's disease. *Chest* 1987;91:579-583.
- Hlubocka Z, Maracek Z, Linhart A, Kejrova E, Pospisilova L, Martasek P, et al. Cardiac involvement in Wilson disease. *J Inherit Metab Dis* 2002;25:269-277.
- Weizman Z, Picard E, Barki Y, Moses S. Wilson's disease associated with pancreatitis. *J Pediatr Gastroenterol Nutr* 1988;7:931-933.
- Carpenter TO, Carnes DL Jr, Anast CS. Hypoparathyroidism in Wilson's disease. *N Engl J Med* 1983;309:873-877.
- Walshe JM. Pregnancy in Wilson's disease. *Q J Med* 1977;46:73-83.
- Klee JG. Undiagnosed Wilson's disease as cause of unexplained miscarriage. *Lancet* 1979;2:423.
- Kaushansky A, Frydman M, Kaufman H, Homburg R. Endocrine studies of the ovulatory disturbances in Wilson's disease (hepatolenticular degeneration). *Fertil Steril* 1987;47:270-273.
- Tarnacka B, Rodo M, Cichy S, Czlonkowska A. Procreation ability in Wilson's disease. *Acta Neurol Scand* 2000;101:395-398.
- Iorio R, D'Ambrosi M, Mazzarella G, Varrella F, Vecchione R, Vegnente A. Early occurrence of hypertransaminasemia in a 13-month-old child with Wilson disease. *J Pediatr Gastroenterol Nutr* 2003;36:637-638.
- Beyersdorff A, Findeisen A. Morbus Wilson: Case report of a two-year-old child as first manifestation. *Scand J Gastroenterol* 2006;41:496-497.
- Mak CM, Tam S, Fan ST, Liu CL, Lam CW. Wilson's disease: a patient undiagnosed for 18 years. *Hong Kong Med J* 2006;12:154-158.
- Lo Curto AG, Marchi A, Grasso M, Arbustini E, Loudianos G, Brega A. Early diagnosis of Wilson Disease in a six-year-old child. *J Pediatr* 2006;148:141.
- Caprai S, Loudianos G, Massei F, Gori L, Lovicu M, Maggiore G. Direct diagnosis of Wilson disease by molecular genetics. *J Pediatr* 2006;148:138-140.
- Wilson DC, Phillips MJ, Cox DW, Roberts EA. Severe hepatic Wilson's disease in preschool-aged children. *J Pediatr* 2000;137:719-722.
- Kalach N, Seidman EG, Morin C, Rasquin-Weber A, O'Regan S, Laberge JM, et al. Acute liver failure from Wilson's disease in a five year-old child. *Can J Gastroenterol* 1993;7:610-612.
- Ala A, Borjigin J, Rochwarger A, Schilsky M. Wilson disease in septuagenarian siblings: Raising the bar for diagnosis. *HEPATOLOGY* 2005;41:668-670.
- Perri RE, Hahn SH, Ferber MJ, Kamath PS. Wilson Disease—keeping the bar for diagnosis raised. *HEPATOLOGY* 2005;42:974.

49. Fleming CR, Dickson ER, Wahner HW, Hollenhorst RW, McCall JT. Pigmented corneal rings in non-Wilsonian liver disease. *Ann Intern Med* 1977;86:285-288.
50. Frommer D, Morris J, Sherlock S, Abrams J, Newman S. Kayser-Fleischer-like rings in patients without Wilson's disease. *Gastroenterology* 1977;72:1331-1335.
51. Tauber J, Steinert RF. Pseudo-Kayser-Fleischer ring of the cornea associated with non-Wilsonian liver disease. A case report and literature review. *Cornea* 1993;12:74-77.
52. Dunn LL, Annable WL, Kliegman RM. Pigmented corneal rings in neonates with liver disease. *J Pediatr* 1987;110:771-776.
53. Gow PJ, Smallwood RA, Angus PW, Smith AL, Wall AJ, Sewell RB. Diagnosis of Wilson's disease: an experience over three decades. *Gut* 2000;46:415-419.
54. Emre S, Atillasoy EO, Ozdemir S, Schilsky M, Rathna Varma CV, Thung SN, et al. Orthotopic liver transplantation for Wilson's disease: a single-center experience. *Transplantation* 2001;72:1232-1236.
55. Medici V, Trevisan CP, D'Inca R, Barollo M, Zancan L, Fagioli S, et al. Diagnosis and management of Wilson's disease: results of a single center experience. *J Clin Gastroenterol* 2006;40:936-941.
56. Merle U, Schaefer M, Ferenci P, Stremmel W. Clinical presentation, diagnosis and long-term outcome of Wilson's disease: a cohort study. *Gut* 2007;56:115-120.
57. Martins da Costa C, Baldwin D, Portmann B, Lolin Y, Mowat AP, Mieli-Vergani G. Value of urinary copper excretion after penicillamine challenge in the diagnosis of Wilson's disease. *HEPATOLOGY* 1992;15:609-615.
58. Giacchino R, Marazzi MG, Barabino A, Fasce L, Ciravegna B, Famularo L, et al. Syndromic variability of Wilson's disease in children. Clinical study of 44 cases. *Ital J Gastroenterol Hepatol* 1997;29:155-161.
59. Sanchez-Albisaia I, Garde T, Hierro L, Camarena C, Frauca E, de la Vega A, et al. A high index of suspicion: the key to an early diagnosis of Wilson's disease in childhood. *J Pediatr Gastroenterol Nutr* 1999;28:186-190.
60. Demirkiran M, Jankovic J, Lewis RA, Cox DW. Neurologic presentation of Wilson disease without Kayser-Fleischer rings. *Neurology* 1996;46:1040-1043.
61. Cairns JE, Williams HP, Walshe JM. "Sunflower cataract" in Wilson's disease. *Br Med J* 1969;3:95-96.
62. Schilsky ML, Scheinberg IH, Sternlieb I. Liver transplantation for Wilson's disease: indications and outcome. *HEPATOLOGY* 1994;19:583-587.
63. Esmaeli B, Burnstine MA, Martonyi CL, Sugar A, Johnson V, Brewer GJ. Regression of Kayser-Fleischer rings during oral zinc therapy: correlation with systemic manifestations of Wilson's disease. *Cornea* 1996;15:582-588.
64. Shiva S, Wang X, Ringwood LA, Xu X, Yuditskaya S, Annavajjhala V, et al. Ceruloplasmin is a NO oxidase and nitrite synthase that determines endocrine NO homeostasis. *Nat Chem Biol* 2006;2:486-493.
65. Morell AG, Windsor J, Sternlieb I, Scheinberg IH. Measurement of the concentration of ceruloplasmin by determination of its oxidase activity. In: Sunderman SW, Sunderman SW Jr, eds. *Laboratory Diagnosis of Liver Diseases*. St. Louis, MO: Warren H. Green; 1968:193-195.
66. Schosinsky KH, Lehmann HP, Beeler MS. Measurement of ceruloplasmin from its oxidase activity in serum by use of *o*-dianisidine dihydrochloride. *Clin Chem* 1974;20:1556-1563.
67. Gnanou JV, Thykadavil VG, Thuppl V. Pros and cons of immunochemical and enzymatic method in the diagnosis of Wilson's disease. *Indian J Med Sci* 2006;60:371-375.
68. Walshe JM. Diagnostic significance of reduced serum caeruloplasmin concentration in neurological disease. *Mov Disord* 2005;20:1658-1661.
69. Fuhrman MP, Herrmann V, Masidonski P, Eby C. Pancytopenia after removal of copper from total parenteral nutrition. *J Parenter Enteral Nutr* 2001;24:361-366.
70. Menkes JH. Menkes disease and Wilson disease: two sides of the same copper coin. Part I: Menkes disease. *Eur J Paediatr Neurol* 1999;3:147-158.
71. Edwards CQ, Williams DM, Cartwright GE. Hereditary hypoceruloplasminemia. *Clin Genet* 1979;15:311-316.
72. Xu X, Pin S, Gathinji M, Fuchs R, Harris ZL. Aceruloplasminemia: an inherited neurodegenerative disease with impairment of iron homeostasis. *Ann N Y Acad Sci* 2004;1012:299-305.
73. Cauza E, Maier-Dobersberger T, Polli C, Kaserer K, Kramer L, Ferenci P. Screening for Wilson's disease in patients with liver diseases by serum ceruloplasmin. *J Hepatol* 1997;27:358-362.
74. Perman JA, Werlin SL, Grand RJ, Watkins JB. Laboratory measures of copper metabolism in the differentiation of chronic active hepatitis and Wilson disease in children. *J Pediatr* 1979;94:564-568.
75. Scheinberg IH, Sternlieb I. *Wilson's Disease*. Philadelphia, PA: W B Saunders; 1984.
76. Walshe JM. Wilson's disease presenting with features of hepatic dysfunction: a clinical analysis of eighty-seven patients. *Q J Med* 1989;70:253-263.
77. Lau JY, Lai CL, Wu PC, Pan HY, Lin HJ, Todd D. Wilson's disease: 35 years' experience. *Q J Med* 1990;75:597-605.
78. Roberts EA, Cox DW. Wilson disease. *Baillieres Clin Gastroenterol* 1998;12:237-256.
79. Gaffney D, Fell GS, O'Reilly DS. ACP Best Practice No 163. Wilson's disease: acute and presymptomatic laboratory diagnosis and monitoring. *J Clin Pathol* 2000;53:807-812.
80. Tu JB, Blackwell RQ. Studies on levels of penicillamine-induced cupriuresis in heterozygotes of Wilson's disease. *Metabolism* 1967;16:507-513.
81. Gross JB Jr, Ludwig J, Wiesner RH, McCall JT, LaRusso NF. Abnormalities in tests of copper metabolism in primary sclerosing cholangitis. *Gastroenterology* 1985;89:272-278.
82. Garcia-Villarreal L, Daniels S, Shaw SH, Cotton D, Galvin M, Geskes J, et al. High prevalence of the very rare Wilson disease gene mutation Leu708Pro in the island of Gran Canaria (Canary Islands, Spain): a genetic and clinical study. *HEPATOLOGY* 2000;32:1329-1336.
83. Frommer DJ. Urinary copper excretion and hepatic copper concentrations in liver disease. *Digestion* 1981;21:169-178.
84. LaRusso NF, Summerskill WH, McCall JT. Abnormalities of chemical tests for copper metabolism in chronic active liver disease: differentiation from Wilson's disease. *Gastroenterology* 1976;70:653-655.
85. Muller T, Koppikar S, Taylor RM, Carragher F, Schlenck B, Heinz-Erian P, et al. Re-evaluation of the penicillamine challenge test in the diagnosis of Wilson's disease in children. *J Hepatol* 2007;47:270-276.
86. Dhawan A, Taylor RM, Cheeseman P, De Silva P, Katsiyiannakis L, Mieli-Vergani G. Wilson's disease in children: 37-Year experience and revised King's score for liver transplantation. *Liver Transpl* 2005;11:441-448.
87. Roberts EA, Jimenez C, O'Connor C, Cox DW. Diagnosis and outcome of Wilson disease in a paediatric cohort [Abstract]. *J Pediatr Gastroenterol Nutr* 2004;39(Suppl 1):A128.
88. Ferenci P, Steindl-Munda P, Vogel W, Jessner W, Gschwantler M, Stauber R, et al. Diagnostic value of quantitative hepatic copper determination in patients with Wilson's Disease. *Clin Gastroenterol Hepatol* 2005;3:811-818.
89. Song YM, Chen MD. A single determination of liver copper concentration may misdiagnose Wilson's disease. *Clin Biochem* 2000;33:589-590.
90. Lyon TD, Fell GS, Gaffney D, McGaw BA, Russell RI, Park RH, et al. Use of a stable copper isotope (⁶⁵Cu) in the differential diagnosis of Wilson's disease. *Clin Sci (Lond)* 1995;88:727-732.
91. Alt ER, Sternlieb I, Goldfischer S. The cytopathology of metal overload. *Int Rev Exp Pathol* 1990;31:165-188.
92. Ludwig J, Moyer TP, Rakela J. The liver biopsy diagnosis of Wilson's disease. *Methods in pathology*. *Am J Clin Pathol* 1994;102:443-446.
93. Langner C, Denk H. Wilson disease. *Virchows Arch* 2004;445:111-118.
94. Stromeyer FW, Ishak KG. Histology of the liver in Wilson's disease: a study of 34 cases. *Am J Clin Pathol* 1980;73:12-24.
95. Strand S, Hofmann WJ, Grambihler A, Hug H, Volkmann M, Otto G, et al. Hepatic failure and liver cell damage in acute Wilson's disease

- involve CD95 (APO-1/Fas) mediated apoptosis. *Nat Med* 1998;4:588-593.
96. Goldfischer S, Sternlieb I. Changes in the distribution of hepatic copper in relation to the progression of Wilson's disease (hepatolenticular degeneration). *Am J Pathol* 1968;53:883-901.
 97. Geller SA, Petrovic LM, Batts KB, Ferrell LM, Cohen C, Lewin K, et al. Histopathology of end-stage Wilson disease [Abstract]. *Mod Pathol* 2000;13:184A.
 98. Sternlieb I. Mitochondrial and fatty changes in hepatocytes of patients with Wilson's disease. *Gastroenterology* 1968;55:354-367.
 99. Feldmann G, Groussard O, Fauvert R. L'ultrastructure hépatique au cours de la maladie de Wilson [Hepatic ultrastructure in Wilson's disease]. *Biol Gastroenterol* 1969;2:137-160.
 100. Sternlieb I. Fraternal concordance of types of abnormal hepatocellular mitochondria in Wilson's disease. *HEPATOLOGY* 1992;16:728-732.
 101. Phillips MJ, Poucell S, Patterson J, Valencia P. *The Liver. An Atlas and Text of Ultrastructural Pathology*. New York, NY: Raven Press; 1987.
 102. Sternlieb I, Feldmann G. Effects of anticopper therapy on hepatocellular mitochondria in patients with Wilson's disease: an ultrastructural and stereological study. *Gastroenterology* 1976;71:457-461.
 103. Walshe JM, Waldenstrom E, Sams V, Nordlinder H, Westermarck K. Abdominal malignancies in patients with Wilson's disease. *Q J Med* 2003;96:657-662.
 104. Iwadate H, Ohira H, Suzuki T, Abe K, Yokokawa J, Takiguchi J, et al. Hepatocellular carcinoma associated with Wilson's disease. *Intern Med* 2004;43:1042-1045.
 105. Kumagi T, Horiike N, Michitaka K, Hasebe A, Kawai K, Tokumoto Y, et al. Recent clinical features of Wilson's disease with hepatic presentation. *J Gastroenterol* 2004;39:1165-1169.
 106. Kumagi T, Horiike N, Abe M, Kurose K, Iuchi H, Masumoto T, et al. Small hepatocellular carcinoma associated with Wilson's disease. *Intern Med* 2005;44:439-443.
 107. Savas N, Canan O, Ozcay F, Bilezikci B, Karakayali H, Yilmaz U, et al. Hepatocellular carcinoma in Wilson's disease: a rare association in childhood. *Pediatr Transplant* 2006;10:639-643.
 108. Xu R, Bu-Ghanim M, Fiel MI, Schiano T, Cohen E, Thung SN. Hepatocellular carcinoma associated with an atypical presentation of Wilson's disease. *Semin Liver Dis* 2007;27:122-127.
 109. Jung KH, Ahn TB, Jeon BS. Wilson disease with an initial manifestation of polyneuropathy. *Arch Neurol* 2005;62:1628-1631.
 110. Bhattacharya K, Velickovic M, Schilsky M, Kaufmann H. Autonomic cardiovascular reflexes in Wilson's disease. *Clin Auton Res* 2002;12:190-192.
 111. Aisen AM, Martel W, Gabrielsen TO, Glazer GM, Brewer G, Young AB, et al. Wilson disease of the brain: MR imaging. *Radiology* 1985;157:137-141.
 112. van Wassenaeer-van Hall HN, van den Heuvel AG, Algra A, Hoogenraad TU, Mali WP. Wilson disease: findings at MR imaging and CT of the brain with clinical correlation. *Radiology* 1996;198:531-536.
 113. Brewer GJ, Dick RD, Johnson V, Wang Y, Yuzbasiyan-Gurkan V, Kluin K, et al. Treatment of Wilson's disease with ammonium tetrathiomolybdate. I. Initial therapy in 17 neurologically affected patients. *Arch Neurol* 1994;51:545-554.
 114. Brewer GJ, Dick RD, Johnson VD, Brunberg JA, Kluin KJ, Fink JK. Treatment of Wilson's disease with zinc: XV Long-term follow-up studies. *J Lab Clin Med* 1998;132:264-278.
 115. Thomas GR, Roberts EA, Walshe JM, Cox DW. Haplotypes and mutations in Wilson disease. *Am J Hum Genet* 1995;56:1315-1319.
 116. Maier-Dobersberger T, Mannhalter C, Rack S, Granditsch G, Kaserer K, Korninger L, et al. Diagnosis of Wilson's disease in an asymptomatic sibling by DNA linkage analysis. *Gastroenterology* 1995;109:2015-2018.
 117. Vidaud D, Assouline B, Lecoz P, Cadranet JF, Chappuis P. Misdiagnosis revealed by genetic linkage analysis in a family with Wilson disease. *Neurology* 1996;46:1485-1486.
 118. Shah AB, Chernov I, Zhang HT, Ross BM, Das K, Lutsenko S, et al. Identification and analysis of mutations in the Wilson disease gene (ATP7B): population frequencies, genotype-phenotype correlation, and functional analyses. *Am J Hum Genet* 1997;61:317-328.
 119. Cossu P, Pirastu M, Nucaro A, Figus A, Balestrieri A, Borrone C, et al. Prenatal diagnosis of Wilson's disease by analysis of DNA polymorphism. *N Engl J Med* 1992;327:57.
 120. Loudianos G, Figus AL, Loi A, Angius A, Dessi V, Deiana M, et al. Improvement of prenatal diagnosis of Wilson disease using microsatellite markers. *Prenat Diagn* 1994;14:999-1002.
 121. Yamaguchi Y, Aoki T, Arashima S, Oura T, Takada G, Kitagawa T, et al. Mass screening for Wilson's disease: results and recommendations. *Pediatr Int* 1999;41:405-408.
 122. Loudianos G, Dessi V, Lovicu M, Angius A, Figus A, Lilliu F, et al. Molecular characterization of Wilson disease in the Sardinian population—evidence of a founder effect. *Hum Mutat* 1999;14:294-303.
 123. Thomas GR, Jenson O, Gudmundsson G, Thorsteinsson L, Cox DW. Wilson disease in Iceland: a clinical and genetic study. *Am J Hum Genet* 1995;56:1140-1146.
 124. Kim EK, Yoo OJ, Song KY, Yoo HW, Choi SY, Cho SW, et al. Identification of three novel mutations and a high frequency of the Arg778Leu mutation in Korean patients with Wilson disease. *Hum Mutat* 1998;11:275-278.
 125. Nanji MS, Nguyen VT, Kawasoe JH, Inui K, Endo F, Nakajima T, et al. Haplotype and mutation analysis in Japanese patients with Wilson disease. *Am J Hum Genet* 1997;60:1423-1429.
 126. Wan L, Tsai CH, Tsai Y, Hsu CM, Lee CC, Tsai FJ. Mutation analysis of Taiwanese Wilson disease patients. *Biochem Biophys Res Commun* 2006;345:734-738.
 127. Margarit E, Bach V, Gomez D, Bruguera M, Jara P, Queralto R, et al. Mutation analysis of Wilson disease in the Spanish population – identification of a prevalent substitution and eight novel mutations in the ATP7B gene. *Clin Genet* 2005;68:61-68.
 128. Deguti MM, Genschel J, Cancado EL, Barbosa ER, Bochow B, Mucenic M, et al. Wilson disease: novel mutations in the ATP7B gene and clinical correlation in Brazilian patients. *Hum Mutat* 2004;23:398.
 129. Caca K, Ferenci P, Kuhn HJ, Polli C, Willgerodt H, Kunath B, et al. High prevalence of the H1069Q mutation in East German patients with Wilson disease: rapid detection of mutations by limited sequencing and phenotype-genotype analysis. *J Hepatol* 2001;35:575-581.
 130. Firneisz G, Lakatos PL, Szalay F, Polli C, Glant TT, Ferenci P. Common mutations of ATP7B in Wilson disease patients from Hungary. *Am J Med Genet* 2002;108:23-28.
 131. Thomas GR, Forbes JR, Roberts EA, Walshe JM, Cox DW. The Wilson disease gene: spectrum of mutations and their consequences. *Nat Genet* 1995;9:210-217.
 132. Palsson R, Jonasson JG, Kristjansson M, Bodvarsson A, Goldin RD, Cox DW, et al. Genotype-phenotype interactions in Wilson's disease: insight from an Icelandic mutation. *Eur J Gastroenterol Hepatol* 2001;13:433-436.
 133. Yener S, Akarsu M, Karacanci C, Sengul B, Topalak O, Biberoglu K, et al. Wilson's disease with coexisting autoimmune hepatitis. *J Gastroenterol Hepatol* 2004;19:114-116.
 134. Roche-Sicot J, Benhamou JP. Acute intravascular hemolysis and acute liver failure associated as a first manifestation of Wilson's disease. *Ann Intern Med* 1977;86:301-303.
 135. Hamlyn AN, Gollan JL, Douglas AP, Sherlock S. Fulminant Wilson's disease with haemolysis and renal failure: copper studies and assessment of dialysis regimens. *Br Med J* 1977;2:660-662.
 136. McCullough AJ, Fleming CR, Thistle JL, Baldus WP, Ludwig J, McCall JT, et al. Diagnosis of Wilson's disease presenting as fulminant hepatic failure. *Gastroenterology* 1983;84:161-167.
 137. Rector WG Jr, Uchida T, Kanel GC, Redeker AG, Reynolds TB. Fulminant hepatic and renal failure complicating Wilson's disease. *Liver* 1984;4:341-347.
 138. Enomoto K, Ishibashi H, Irie K, Okumura Y, Nomura H, Fukushima M, et al. Fulminant hepatic failure without evidence of cirrhosis in a case of Wilson's disease. *Jpn J Med* 1989;28:80-84.
 139. Ferlan-Marolt V, Stepec S. Fulminant Wilsonian hepatitis unmasked by disease progression: report of a case and review of the literature. *Dig Dis Sci* 1999;44:1054-1058.

140. Sallie R, Katsiyiannakis L, Baldwin D, Davies S, O'Grady J, Mowat A, et al. Failure of simple biochemical indexes to reliably differentiate fulminant Wilson's disease from other causes of fulminant liver failure. *HEPATOLOGY* 1992;16:1206-1211.
141. Berman DH, Leventhal RI, Gavaler JS, Cadoff EM, Van Thiel DH. Clinical differentiation of fulminant Wilsonian hepatitis from other causes of hepatic failure. *Gastroenterology* 1991;100:1129-1134.
142. Nazer H, Ede RJ, Mowat AP, Williams R. Wilson's disease: clinical presentation and use of prognostic index. *Gut* 1986;27:1377-1381.
143. Zandman-Goddard G, Weiss P, Avidan B, Bar-Meir S, Shoefeld Y. Acute varicella infection heralding Wilsonian crisis. *J Clin Gastroenterol* 1994;18:265-266.
144. Sallie R, Chiyende J, Tan KC, Bradley D, Portmann B, Williams R, et al. Fulminant hepatic failure resulting from coexistent Wilson's disease and hepatitis E. *Gut* 1994;35:849-853.
145. Lembowicz K, Kryczka W, Walewska-Zielecka B, Kubicka J. Wilson's disease coexisting with viral hepatitis type C: a case report with histological and ultrastructural studies of the liver. *Ultrastruct Pathol* 1999;23:39-44.
146. Owada M, Suzuki K, Fukushi M, Yamauchi K, Kitagawa T. Mass screening for Wilson's disease by measuring urinary holoceruloplasmin. *J Pediatr* 2002;140:614-616.
147. Aoki K. Newborn screening in Japan. *Southeast Asian J Trop Med Public Health* 2003;34(Suppl 3):80.
148. Kroll CA, Ferber MJ, Dawson BD, Jacobson RM, Mensink KA, Lorey F, et al. Retrospective determination of ceruloplasmin in newborn screening blood spots of patients with Wilson disease. *Mol Genet Metab* 2006;89:134-138.
149. Sternlieb I, Scheinberg IH. Prevention of Wilson's disease in asymptomatic patients. *N Engl J Med* 1968;278:352-359.
150. Scheinberg IH, Sternlieb I, Schilsky M, Stockert RJ. Penicillamine may detoxify copper in Wilson's disease. *Lancet* 1987;ii:95.
151. Siegel RC. Collagen cross-linking effect of D-penicillamine on cross-linking in vitro. *J Biol Chem* 1977;252:254-259.
152. Lipsky PE, Ziff M. The effect of D-penicillamine on mitogen-induced human lymphocyte proliferation: synergistic inhibition by D-penicillamine and copper salts. *J Immunol* 1978;120:1006-1013.
153. Perrett D. The metabolism and pharmacology of D-penicillamine in man. *J Rheumatol Suppl* 1981;7:41-50.
154. Wiesner RH, Dickson ER, Carlson GL, McPhaul LW, Go VLW. The pharmacokinetics of D-penicillamine in man. *J Rheumatol* 1981;8(Suppl 7):51-55.
155. Bergstrom RF, Kay DR, Harkcom TM, Wagner JG. Penicillamine kinetics in normal subjects. *Clin Pharmacol Ther* 1981;30:404-413.
156. Schuna A, Osman MA, Patel RB, Welling PB, Sundstrom WR. Influence of food on the bioavailability of penicillamine. *J Rheumatol* 1983;10:95-97.
157. Kukovetz WR, Beubler E, Kreuzig F, Moritz AJ, Nimberger G, Werner-Breitnecker L. Bioavailability and pharmacokinetics of D-penicillamine. *J Rheumatol* 1983;10:90-94.
158. Wei P, Sass-Kortsak A. Urinary excretion and renal clearance of D-penicillamine in humans and the dog. *Gastroenterology* 1970;58:288.
159. Falkmer S, Samuelson G, Sjolín S. Penicillamine-induced normalization of clinical signs, and liver morphology and histochemistry in a case of Wilson's disease. *Pediatrics* 1970;45:260-268.
160. Walshe JM. Copper chelation in patients with Wilson's disease. A comparison of penicillamine and triethylene tetramine dihydrochloride. *Q J Med* 1973;42:441-452.
161. Sass-Kortsak A. Wilson's disease. A treatable liver disease in children. *Pediatr Clin North Am* 1975;22:963-984.
162. Grand RJ, Vawter GF. Juvenile Wilson disease: histologic and functional studies during penicillamine therapy. *J Pediatr* 1975;87:1161-1170.
163. Sternlieb I. Copper and the liver. *Gastroenterology* 1980;78:1615-1628.
164. Czlonkowska A, Gajda J, Rodo M. Effects of long-term treatment in Wilson's disease with D-penicillamine and zinc sulphate. *J Neurol* 1996;243:269-273.
165. Brewer GJ, Terry CA, Aisen AM, Hill GM. Worsening of neurologic syndrome in patients with Wilson's disease with initial penicillamine therapy. *Arch Neurol* 1987;44:490-493.
166. Walshe JM, Yealland M. Chelation treatment of neurological Wilson's disease. *Q J Med* 1993;86:197-204.
167. Scheinberg IH, Jaffe ME, Sternlieb I. The use of trientine in preventing the effects of interrupting penicillamine therapy in Wilson's disease. *N Engl J Med* 1987;317:209-213.
168. Becuwe C, Dalle S, Ronger-Savle S, Skowron F, Balme B, Kanitakis J, et al. Elastosis perforans serpiginosa associated with pseudo-pseudoxanthoma elasticum during treatment of Wilson's disease with penicillamine. *Dermatology* 2005;210:60-63.
169. Deutscher J, Kiess W, Scheers Schmidt G, Willgerodt H. Potential hepatotoxicity of penicillamine treatment in three patients with Wilson's disease. *J Pediatr Gastroenterol Nutr* 1999;29:628.
170. Shiono Y, Wakusawa S, Hayashi H, Takikawa T, Yano M, Okada T, et al. Iron accumulation in the liver of male patients with Wilson disease. *Am J Gastroenterol* 2001;96:3147-3151.
171. Walshe JM. Treatment of Wilson's disease with trientine (triethylene tetramine) dihydrochloride. *Lancet* 1982;1:643-647.
172. Walshe JM. The management of pregnancy in Wilson's disease treated with trientine. *Q J Med* 1986;58:81-87.
173. Kodama H, Murata Y, Iitsuka T, Abe T. Metabolism of administered triethylene tetramine dihydrochloride in humans. *Life Sci* 1997;61:899-907.
174. Sarkar B, Sass-Kortsak A, Clarke R, Laurie SH, Wei P. A comparative study of *in vitro* and *in vivo* interaction of D-penicillamine and triethylene-tetramine with copper. *Proc R Soc Med* 1977;70(Suppl 3):13-18.
175. Borthwick TR, Benson GD, Schugar HJ. Copper chelating agents. A comparison of cupruric responses to various tetramines and D-penicillamine. *J Lab Clin Med* 1980;95:575-580.
176. Walshe JM. The management of Wilson's disease with triethylene tetramine 2HC1 (Trien 2HC1). *Prog Clin Biol Res* 1979;34:271-280.
177. Saito H, Watanabe K, Sahara M, Mochizuki R, Edo K, Ohyama Y. Triethylene-tetramine (trien) therapy for Wilson's disease. *Tohoku J Exp Med* 1991;164:29-35.
178. Santos Silva EE, Sarles J, Buts JP, Sokal EM. Successful medical treatment of severely decompensated Wilson disease. *J Pediatr* 1996;128:285-287.
179. Epstein O, Sherlock S. Triethylene tetramine dihydrochloride toxicity in primary biliary cirrhosis. *Gastroenterology* 1980;78:1442-1445.
180. Shiono Y, Hayashi H, Wakusawa S, Yano M. Ultrastructural identification of iron and copper accumulation in the liver of a male patient with Wilson disease. *Med Electron Microsc* 2001;34:54-60.
181. Hoogenraad TU, Koevoet R, de Ruyter Korver EG. Oral zinc sulphate as long-term treatment in Wilson's disease (hepatolenticular degeneration). *Eur Neurol* 1979;18:205-211.
182. Hoogenraad TU, Van Hattum J, Van den Hamer CJ. Management of Wilson's disease with zinc sulphate. Experience in a series of 27 patients. *J Neurol Sci* 1987;77:137-146.
183. Brewer GJ, Yuzbasiyan-Gurkan V, Young AB. Treatment of Wilson's disease. *Semin Neurol* 1987;7:209-220.
184. Brewer GJ, Hill GM, Prasad AS, Cossack ZT, Rabbani P. Oral zinc therapy for Wilson's disease. *Ann Intern Med* 1983;99:314-319.
185. Cousins RJ. Absorption, transport and hepatic metabolism of copper and zinc: special reference to metallothionein and ceruloplasmin. *Physiol Rev* 1985;65:238-309.
186. Hill GM, Brewer GJ, Prasad AS, Hydrick CR, Hartmann DE. Treatment of Wilson's disease with zinc. I. Oral zinc therapy regimens. *HEPATOLOGY* 1987;7:522-528.
187. Schilsky M, Blank RR, Czaja MJ, Scheinberg IH, Stockert RJ, Sternlieb I. Hepatocellular copper toxicity and its attenuation by zinc. *J Clin Invest* 1989;84:1562-1568.
188. Lang CJ, Rabas-Kolominsky P, Engelhardt A, Kobras G, Konig HJ. Fatal deterioration of Wilson's disease after institution of oral zinc therapy. *Arch Neurol* 1993;50:1007-1008.

189. Walshe JM, Munro NA. Zinc-induced deterioration in Wilson's disease aborted by treatment with penicillamine, dimercaprol, and a novel zero copper diet. *Arch Neurol* 1995;52:10-11.
190. Brewer GJ, Johnson V, Kaplan J. Treatment of Wilson's disease with zinc: XIV. Studies of the effect of zinc on lymphocyte function. *J Lab Clin Med* 1997;129:649-652.
191. Alexiou D, Hatzis T, Koutselinis A. [Maintenance treatment of Wilson's disease with oral zinc. Apropos of a child treated for 4 years]. *Arch Fr Pediatr* 1985;42:447-449.
192. Marcellini M, Di Ciommo V, Callea F, Devito R, Comparcola D, Sartorelli MR, et al. Treatment of Wilson's disease with zinc from the time of diagnosis in pediatric patients: a single-hospital, 10-year follow-up study. *J Lab Clin Med* 2005;145:139-143.
193. Lee VD, Northup PG, Berg CL. Resolution of decompensated cirrhosis from Wilson's disease with zinc monotherapy: a potential therapeutic option? *Clin Gastroenterol Hepatol* 2006;4:1069-1071.
194. Brewer GJ, Dick RD, Johnson VD, Fink JK, Kluin KJ, Daniels S. Treatment of Wilson's disease with zinc XVI: Treatment during the pediatric years. *J Lab Clin Med* 2001;137:191-198.
195. Pecoud A, Dozel F, Schelling JL. The effect of foodstuffs on the absorption of zinc sulfate. *Clin Pharmacol Ther* 1975;17:469.
196. von Herbay A, de Groot H, Hegi U, Stremmel W, Strohmeyer G, Sies H. Low vitamin E content in plasma of patients with alcoholic liver disease, hemochromatosis and Wilson's disease. *J Hepatol* 1994;20:41-46.
197. Sokol RJ, Twedt D, McKim JM Jr, Devereaux MW, Karrer FM, Kam I, et al. Oxidant injury to hepatic mitochondria in patients with Wilson's disease and Bedlington terriers with copper toxicosis. *Gastroenterology* 1994;107:1788-1798.
198. Ogihara H, Ogihara T, Miki M, Yasuda H, Mino M. Plasma copper and antioxidant status in Wilson's disease. *Pediatr Res* 1995;37:219-226.
199. Sinha S, Christopher R, Arunodaya GR, Prashanth LK, Gopinath G, Swamy HS, et al. Is low serum tocopherol in Wilson's disease a significant symptom? *J Neurol Sci* 2005;228:121-123.
200. Nagasaka H, Inoue I, Inui A, Komatsu H, Sogo T, Murayama K, et al. Relationship between oxidative stress and antioxidant systems in the liver of patients with Wilson disease: hepatic manifestation in Wilson disease as a consequence of augmented oxidative stress. *Pediatr Res* 2006;60:472-477.
201. Brewer GJ, Yuzbasiyan-Gurkan V, Dick R, Wang Y, Johnson V. Does a vegetarian diet control Wilson's disease? *J Am Coll Nutr* 1993;12:527-530.
202. Ogra Y, Suzuki KT. Targeting of tetrathiomolybdate on the copper accumulating in the liver of LEC rats. *J Inorg Biochem* 1998;70:49-55.
203. Brewer GJ, Hedera P, Kluin KJ, Carlson M, Askari F, Dick RB, et al. Treatment of Wilson disease with ammonium tetrathiomolybdate: III. Initial therapy in a total of 55 neurologically affected patients and follow-up with zinc therapy. *Arch Neurol* 2003;60:379-385.
204. Brewer GJ, Askari F, Lorincz MT, Carlson M, Schilsky M, Kluin KJ, et al. Treatment of Wilson disease with ammonium tetrathiomolybdate: IV. Comparison of tetrathiomolybdate and trientine in a double-blind study of treatment of the neurologic presentation of Wilson disease. *Arch Neurol* 2006;63:521-527.
205. Karunajeewa H, Wall A, Metz J, Grigg A. Cytopenias secondary to copper depletion complicating ammonium tetrathiomolybdate therapy for Wilson's disease. *Aust N Z J Med* 1998;28:215-216.
206. Medici V, Trevisan CP, Bigotto MA, D'Inca R, Martines D, Dal Pont E, et al. Adverse reaction after tetrathiomolybdate treatment for Wilson's disease: A case report. *Mov Disord* 2006;21:2030-2032.
207. Pan Q, Kleer CG, van Golen KL, Irani J, Bottema KM, Bias C, et al. Copper deficiency induced by tetrathiomolybdate suppresses tumor growth and angiogenesis. *Cancer Res* 2002;62:4854-4859.
208. Lowndes SA, Harris AL. Copper chelation as an antiangiogenic therapy. *Oncol Res* 2004;14:529-539.
209. Brewer GJ. Copper lowering therapy with tetrathiomolybdate as an antiangiogenic strategy in cancer. *Curr Cancer Drug Targets* 2005;5:195-202.
210. Walshe JM. Diagnosis and treatment of presymptomatic Wilson's disease. *Lancet* 1988;2:435-437.
211. Brewer GJ, Yuzbasiyan-Gurkan V, Lee DY, Appelman H. Treatment of Wilson's disease with zinc. VI. Initial treatment studies. *J Lab Clin Med* 1989;114:633-638.
212. Arnon R, Calderon JF, Schilsky M, Emre S, Shneider BL. Wilson disease in children: serum aminotransferases and urinary copper on triethylene tetramine dihydrochloride (trientine) treatment. *J Pediatr Gastroenterol Nutr* 2007;44:596-602.
213. Walshe JM, Dixon AK. Dangers of non-compliance in Wilson's disease. *Lancet* 1986;1:845-847.
214. Askari FK, Greenson J, Dick RD, Johnson VD, Brewer GJ. Treatment of Wilson's disease with zinc. XVIII. Initial treatment of the hepatic decompensation presentation with trientine and zinc. *J Lab Clin Med* 2003;142:385-390.
215. Sokol RJ, Francis PD, Gold SH, Ford DM, Lum GM, Ambruso DR. Orthotopic liver transplantation for acute fulminant Wilson disease. *J Pediatr* 1985;107:549-552.
216. Petrasek J, Jirsa M, Sperl J, Kozak L, Taimr P, Spicak J, et al. Revised King's College score for liver transplantation in adult patients with Wilson's disease. *Liver Transpl* 2007;13:55-61.
217. Jhang JS, Schilsky ML, Lefkowitz JH, Schwartz J. Therapeutic plasmapheresis as a bridge to liver transplantation in fulminant Wilson disease. *J Clin Apher* 2007;22:10-14.
218. Kiss JE, Berman D, Van Thiel D. Effective removal of copper by plasma exchange in fulminant Wilson's disease. *Transfusion* 1998;38:327-331.
219. Rakela J, Kurtz SB, McCarthy JT, Krom RA, Baldus WP, McGill DB, et al. Postdilution hemofiltration in the management of acute hepatic failure: a pilot study. *Mayo Clin Proc* 1988;63:113-118.
220. Rakela J, Kurtz SB, McCarthy JT, Ludwig J, Ascher NL, Bloomer JR, et al. Fulminant Wilson's disease treated with postdilution hemofiltration and orthotopic liver transplantation. *Gastroenterology* 1986;90:2004-2007.
221. Sarles J, Lefevre P, Picon G. Plasma exchange for fulminant Wilson disease. *Eur J Pediatr* 1992;151:310.
222. Kreymann B, Seige M, Schweigart U, Kopp KF, Classen M. Albumin dialysis: effective removal of copper in a patient with fulminant Wilson disease and successful bridging to liver transplantation: a new possibility for the elimination of protein-bound toxins. *J Hepatol* 1999;31:1080-1085.
223. Stange J, Mitzner SR, Risler T, Erley CM, Lauchart W, Goehl H, et al. Molecular adsorbent recycling system (MARS): clinical results of a new membrane-based blood purification system for bioartificial liver support. *Artif Organs* 1999;23:319-330.
224. Sen S, Felldin M, Steiner C, Larsson B, Gillett GT, Olausson M, et al. Albumin dialysis and Molecular Adsorbents Recirculating System (MARS) for acute Wilson's disease. *Liver Transpl* 2002;8:962-967.
225. Auth MK, Kim HS, Beste M, Bonzel KE, Baumann U, Ballauff A, et al. Removal of metabolites, cytokines and hepatic growth factors by extracorporeal liver support in children. *J Pediatr Gastroenterol Nutr* 2005;40:54-59.
226. Shimono N, Ishibashi H, Ikematsu H, Kudo J, Shirahama M, Inaba S, et al. Fulminant hepatic failure during perinatal period in a pregnant woman with Wilson's disease. *Gastroenterol Jpn* 1991;26:69-73.
227. Morimoto I, Ninomiya H, Komatsu K, Satho M. Pregnancy and penicillamine treatment in a patient with Wilson's disease. *Jpn J Med* 1986;25:59-62.
228. Dupont P, Irion O, Beguin F. Pregnancy in a patient with treated Wilson's disease: a case report. *Am J Obstet Gynecol* 1990;163:1527-1528.
229. Soong YK, Huang HY, Huang CC, Chu NS. Successful pregnancy after D-penicillamine therapy in a patient with Wilson's disease. *J Formos Med Assoc* 1991;90:693-696.
230. Devesa R, Alvarez A, de las Heras G, Ramon de Miguel J. Wilson's disease treated with trientine during pregnancy. *J Pediatr Gastroenterol Nutr* 1995;20:102-103.

231. Lao TT, Chin RK, Cockram CS, Leung NW. Pregnancy in a woman with Wilson's disease treated with zinc. *Asia Oceania J Obstet Gynaecol* 1988;14:167-169.
232. Brewer GJ, Johnson VD, Dick RD, Hedera P, Fink JK, Kluin KJ. Treatment of Wilson's disease with zinc. XVII: Treatment during pregnancy. *HEPATOLOGY* 2000;31:364-370.
233. Endres W. D-penicillamine in pregnancy—to ban or not to ban? *Klin Wochenschr* 1981;59:535-537.
234. Biller J, Swiontoniowski M, Brazis PW. Successful pregnancy in Wilson's disease: a case report and review of the literature. *Eur Neurol* 1985;24:306-309.
235. Hartard C, Kunze K. Pregnancy in a patient with Wilson's disease treated with D-penicillamine and zinc sulfate. A case report and review of the literature. *Eur Neurol* 1994;34:337-340.
236. Nunns D, Hawthorne B, Goulding P, Maresh M. Wilson's disease in pregnancy. *Eur J Obstet Gynecol Reprod Biol* 1995;62:141-143.
237. Sternlieb I. Wilson's disease and pregnancy. *HEPATOLOGY* 2000;31:531-532.
238. Groth CG, Dubois RS, Corman J, Gustafsson A, Iwatsuki S, Rodgerson DO, et al. Metabolic effects of hepatic replacement in Wilson's disease. *Transplant Proc* 1973;5:829-833.
239. Eghtesad B, Nezakatgoo N, Geraci LC, Jabbour N, Irish WD, Marsh W, et al. Liver transplantation for Wilson's disease: a single-center experience. *Liver Transpl Surg* 1999;5:467-474.
240. Asonuma K, Inomata Y, Kasahara M, Uemoto S, Egawa H, Fujita S, et al. Living related liver transplantation from heterozygote genetic carriers to children with Wilson's disease. *Pediatr Transplant* 1999;3:201-205.
241. Komatsu H, Fujisawa T, Inui A, Sogo T, Sekine I, Kodama H, et al. Hepatic copper concentration in children undergoing living related liver transplantation due to Wilsonian fulminant hepatic failure. *Clin Transplant* 2002;16:227-232.
242. Wang XH, Cheng F, Zhang F, Li XC, Kong LB, Li GQ, et al. Living-related liver transplantation for Wilson's disease. *Transpl Int* 2005;18:651-656.
243. Tamura S, Sugawara Y, Kishi Y, Akamatsu N, Kaneko J, Makuuchi M. Living-related liver transplantation for Wilson's disease. *Clin Transplant* 2005;19:483-486.
244. Schumacher G, Platz KP, Mueller AR, Neuhaus R, Steinmuller T, Bechstein WO, et al. Liver transplantation: treatment of choice for hepatic and neurological manifestation of Wilson's disease. *Clin Transplant* 1997;11:217-224.
245. Bax RT, Hassler A, Luck W, Hefter H, Krageloh-Mann I, Neuhaus P, et al. Cerebral manifestation of Wilson's disease successfully treated with liver transplantation. *Neurology* 1998;51:863-865.
246. Lui CC, Chen CL, Cheng YF, Lee TY. Recovery of neurological deficits in a case of Wilson's disease after liver transplantation. *Transplant Proc* 1998;30:3324-3325.
247. Stracciari A, Tempestini A, Borghi A, Guarino M. Effect of liver transplantation on neurological manifestations in Wilson disease. *Arch Neurol* 2000;57:384-386.
248. Wu JC, Huang CC, Jeng LB, Chu NS. Correlation of neurological manifestations and MR images in a patient with Wilson's disease after liver transplantation. *Acta Neurol Scand* 2000;102:135-139.
249. Guarino M, Stracciari A, D'Alessandro R, Pazzaglia P. No neurological improvement after liver transplantation for Wilson's disease. *Acta Neurol Scand* 1995;92:405-408.
250. Kassam N, Witt N, Kneteman N, Bain VG. Liver transplantation for neuropsychiatric Wilson disease. *Can J Gastroenterol* 1998;12:65-68.
251. Brewer GJ, Askari F. Transplant livers in Wilson's disease for hepatic, not neurologic, indications. *Liver Transpl* 2000;6:662-664.
252. Senzolo M, Loreno M, Fagiuoli S, Zanus G, Canova D, Masier A, et al. Different neurological outcome of liver transplantation for Wilson's disease in two homozygotic twins. *Clin Neurol Neurosurg* 2007;109:71-75.
253. Medici V, Mirante VG, Fassati LR, Pompili M, Forti D, Del Gaudio M, et al. Liver transplantation for Wilson's disease: The burden of neurological and psychiatric disorders. *Liver Transpl* 2005;11:1056-1063.