Pediatric Colonoscopic Polypectomy Technique

Marsha Kay and Robert Wyllie

ABSTRACT

Colonoscopy with polypectomy is frequently performed in pediatric patients based on symptoms, with the majority of polyps identified being benign juvenile pedunculated polyps with a vascular stalk. This is in distinction to adults where polypectomy is often performed as part of a colon cancer screening and prevention strategy and a higher fraction of polyps are sessile and or dysplastic. In adults, polypectomy techniques emphasize a need for deeper resection to ensure complete resection of adenomas or potential carcinoma in situ. Adenomatous polyps can occur in the pediatric age group and may be associated with an underlying polyposis, hereditary or chronic inflammatory conditions. Polypectomy techniques include use of cold biopsy forceps for very small polyps, cold snare polypectomy for small sessile polyps and hot snare polypectomy for the majority of polyps in the pediatric age group. Adjuvant techniques include epinephrine volume reduction, saline-assisted polypectomy and hemostatic techniques including injection, clip application and loop application to prevent or treat post-polypectomy bleeding. Electrosurgical principles guide the settings and type of current utilized during hot snare polypectomy. Polypectomy utilizing thermal techniques is associated with a higher risk of complications compared with diagnostic colonoscopy.

Key Words: colonoscopy, complication, electrosurgery, epinephrine volume reduction, gastrointestinal bleeding, pediatric

(*JPGN* 2020;70: 280–284)

RATIONALE FOR PROCEDURE

Polypectomy in adults frequently is performed as part of a strategy to reduce the incidence of colon cancer based on the assumption that in the average risk adult population colon cancers often arise from preexisting adenomas or neoplastic polyps. Patients in higher risk groups will require earlier or more frequent screening and possibly additional intraprocedural imaging, such as utilization of chromoendoscopy. These groups include those with a family or personal history of colon cancer, and those who have an underlying disease process that makes them more susceptible to the development of cancer, such as IBD, familial adenomatous polyposis (FAP), or hereditary nonpolyposis colon cancer (HNPCC) (1–4). In adults, early cancer detection or cancer prevention in patients with nonmalignant but dysplastic polyps is the focus of polypectomy resection and ablation techniques. Therefore, the goal is a complete and by extension deeper resection to limit the possibility of residual adenomatous tissue or of a missed carcinoma.

In distinction, the majority of polyps in the pediatric population are simple juvenile polyps and have no premalignant potential unless occurring as part of a polyposis syndrome. The majority are pedunculated with a moderate-to-long stalk and removal is performed largely as the polyps are causing symptoms, such as rectal bleeding, iron deficiency anemia or potentially intussusception. Mucosa adjacent to the juvenile polyp may have a characteristic appearance known as ''chicken skin mucosa,'' resulting from the presence of mucosal lipid-laden macrophages (5). An increasing fraction of pediatric patients are identified to have more than 1 polyp at the time of full colonoscopy and patients with polyposis syndromes, such as Juvenile Polyposis Coli (JPC) may have a large number of polyps identified at the time of colonoscopy (6).

Adenomas have been identified in pediatric patients and are associated with a higher risk of subsequent colon cancer development, and therefore, polyps removed at colonoscopy in the pediatric age group should be submitted for histologic evaluation to determine if patients need to enter more rigorous screening protocols and potentially undergo genetic evaluation for FAP, HNPCC or other conditions.

POLYPECTOMY TECHNIQUE

Before polypectomy or any type of electrosurgery, the patient must be cleansed of fecal debris. A poorly prepared colon limits visualization and increases the technical difficulty of the procedure. Excessive fecal debris or the use of certain gavage solutions, such as mannitol places the patient at risk for explosion during attempted thermal polypectomy (7,8). The patient's risk of bleeding should be assessed by history, and blood work if indicated including a complete blood count, coagulation profile, and if necessary, blood typing. For patients on antithrombotics including anticoagulants and antiplatelet agents, modification of their antithrombotic regimen in consultation with the patient's care team and in accordance with current guidelines may be required as polypectomy is considered a high risk for bleeding procedure (9).

Diminutive polyps of 3 mm or less in diameter are typically removed with biopsy forceps or alternatively cold snare technique. Cold snare technique can also be used for slightly larger sessile polyps up to about 5–7 mm (10–13). Use of hot biopsy forceps, popular in the past, is now recognized to be associated with a higher rate of procedure complications including significant bleeding and perforation and is currently not recommended (11,14). Although described more than 20 years ago, cold snare technique is increasingly utilized in adults for small diminutive sessile polyps and may be associated with a more superficial resection depth versus hot snare technique (10,15). Tenting of the polyp is not performed when using a cold snare technique and gentle pressure is applied to the snare tip to anchor it to the colonic mucosa typically a few millimeters distal (downstream) to the polyp to allow for resection

Received May 27, 2018; accepted October 26, 2019.
From the Department of Pediatric Gastroenterology and Nutrition, Cleveland Clinic Children's, Cleveland, OH.
Address correspondence and reprint requests to Marsha Kay, MD, Chair, Department of Pediatric Gastroenterology and Nutrition, Director Pediatric Endoscopy, Cleveland Clinic Children's, 9500 Euclid Avenue, Cleveland, OH 44195 (e-mail: kaym@ccf.org).
This article has been developed as a Journal CME Activity by NASPGHAN. Visit *http://www.naspghan.org/content/59/en/Continuing-Medical-Education-CME* to view instructions, documentation, and the complete necessary steps to receive CME credit for reading this article.
The authors report no conflicts of interest.

DOI: 10.1097/MPG.0000000000002591

of a small rim of surrounding normal mucosa in the case of adenomas (16). Aspiration of air during cold snare polypectomy is also not performed in order to avoid an inadvertent deeper submucosal resection. Snare closure when performing this technique is continuous until the polyp is guillotined utilizing a gentle ''push and cut'' technique compared with the ''lift and cut'' technique used with hot snares (11,12). Dedicated cold snares with different physical characteristics including a thinner and stiffer wire compared with standard snares utilized for electrocautery and which lack a connection for electrocoagulation have been developed and may assist in reducing the rate of stalling during polyp transection (10,11) (Fig. 1). Polyps still require retrieval for histologic analysis. Cold snare technique has not been studied in pediatric patients to date.

Large polyps (more than 5–7 mm in diameter) are usually removed with snare electrocautery, especially juvenile polyps, which tend to be very vascular. This is a monopolar technique, where the current passes from the active electrode (snare) to the target tissue and then courses through the path of least resistance to the neutral electrode (previously called the grounding pad) and then back to the electrosurgical unit. The minimal channel diameter for current polypectomy snares is 2.8 mm; therefore, the current minimum endoscope outer diameter for polypectomy is in the range of 9.0 mm. The snare is inserted into the endoscope with the wire loop retracted. The endoscope tip should be stabilized before advancing the polypectomy snare. The polyp, is optimally positioned in the 5–7 o'clock position (17). This position corresponds to where the snare or other instruments exit the colonoscope at the 5 o'clock position. After appropriate positioning of the polypectomy catheter or sheath, only the amount of snare necessary fully to encompass the polyp should be extended. The polyp is then lassoed and the sheath maneuvered to the stalk. The endoscopist should ensure that the snare encompasses only the polyp head and stalk, and that normal bowel is not trapped within the snare to avoid deep thermal injury or perforation. Polyps in a dependent position may be more difficult to access, and therefore, in some cases, the endoscope (or rarely if necessary the patient), and by extension, the polyp can be rotated to a more favorable position to perform polypectomy.

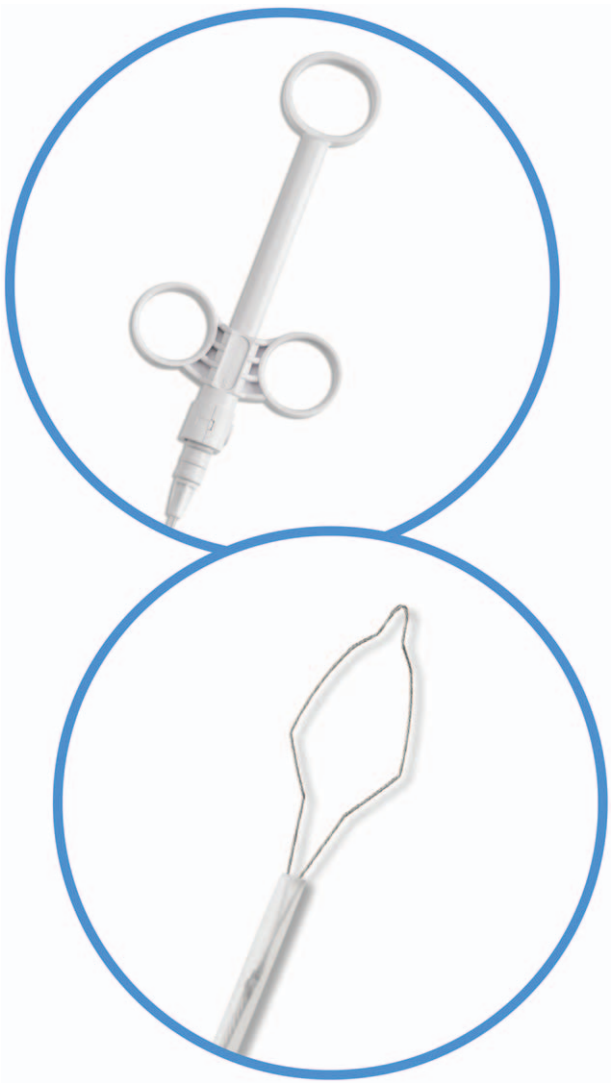

FIGURE 1. Snare and handle of a dedicated cold polypectomy snare. Note that there is no attachment for electrocautery. Dedicated cold snares typically have a thinner and stiffer wire compared to ''hot'' snares. Image courtesy of Steris/ US Endoscopy, Mentor, OH.

As most polyps in pediatric patients are pedunculated, that is, with a stalk, the snare should be positioned to perform electrocautery closer to the polyp head or at the mid-stalk rather than close to the bowel wall or base of the polyp stalk. This allows for grasping of the stalk and coagulation, injection or clipping if postpolypectomy bleeding occurs (18). In addition, this helps to decrease the risk of deep thermal injury to the bowel wall and perforation. This practice of ensnaring the polyp closer to the polyp head is in distinction to the practice of resection of primarily adenomas in the adult patient, which are usually sessile and for which the endoscopist is trying to achieve as complete a resection (translate to a deeper resection) as possible because of long-term risk of malignancy. In adults, argon plasma coagulation (APC) may also be utilized to fulgurate residual fragments of polyps not amenable to complete resection by snare technique (19).

The head of the pedunculated polyp should be lifted off the adjacent mucosa before electrocautery; contact between the polyp head and opposing mucosa should be avoided to prevent a mucosal burn on the opposite colonic wall. Our preference is to have the sheath of the snare be approximated to the polyp head and stalk as the polypectomy snare is initially closed, bringing the distal aspect of the snare toward the polyp head and stalk (18). After the polyp has been snared, a current is passed through the snare, which is slowly closed by the assistant. As the polyp coagulates, there is a whitish or blue/purplish discoloration of the polyp head. Too rapid snare closure results in bleeding from vessels in the stalk that have been amputated but not coagulated. Therefore, clear and closed loop communication between the endoscopist and assistant as to the rate of snare closure and the feel of snare closure as well as the feeling of resistance is required. Most endoscopists use pure coagulation current or a combination of coagulation and cutting settings (blended current) for snare polypectomy. Use of pure cutting current without coagulation will result in bleeding.

To remove large polyps of 2 cm or more in size, piecemeal resection may be necessary. This technique is used primarily if the head of the polyp cannot be encircled within the snare (13). After the head is reduced in size, it is usually possible to snare the stalk and safely remove the remainder of the polyp. Epinephrine injection (1:10,000 solution) of the head of a large pedunculated polyp, known as epinephrine volume reduction, can be performed at the time of colonoscope insertion, and may result in decreased size of the polyp head. This results in easier entrapment and snare polypectomy, which is typically performed

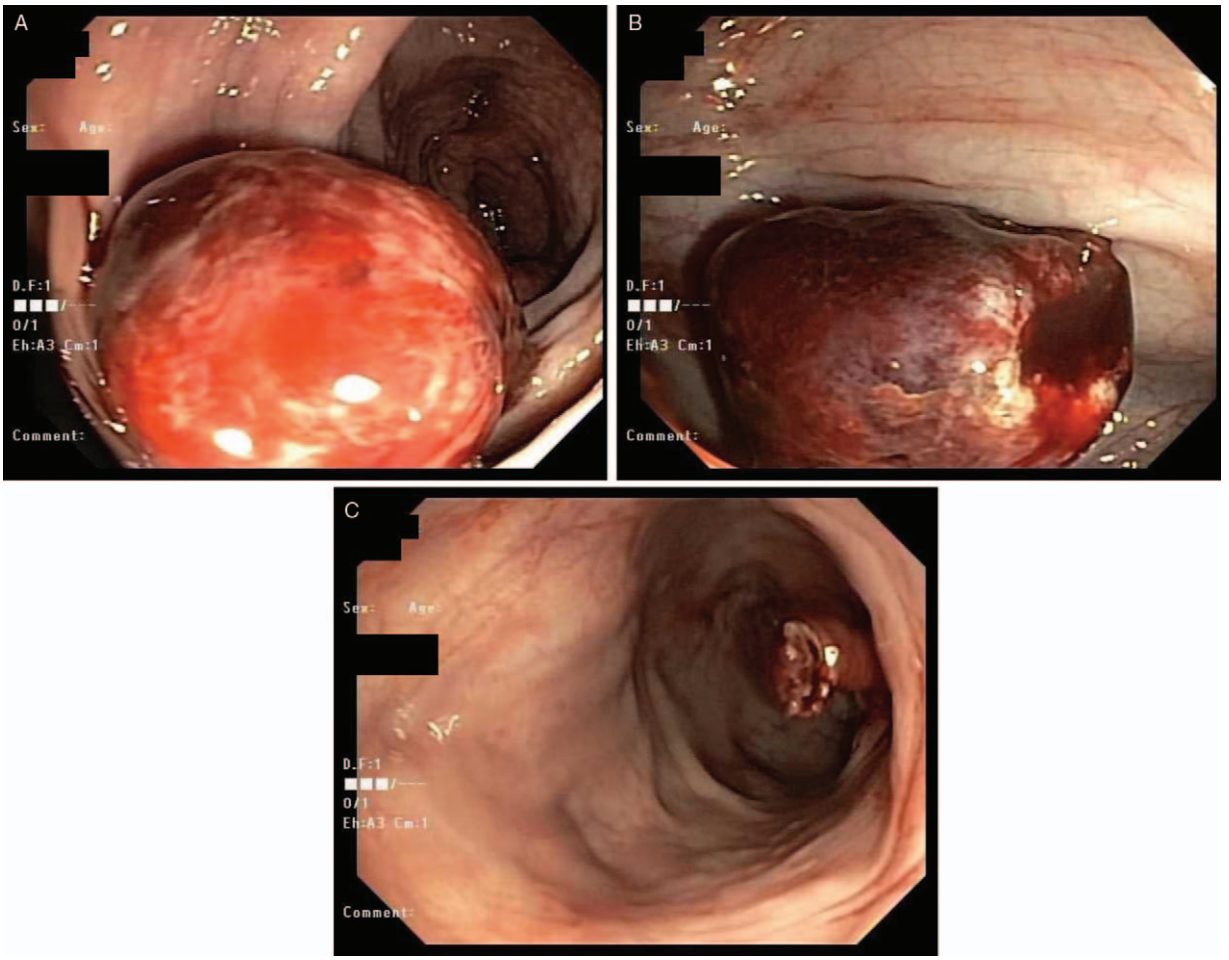

FIGURE 2. (A) Large pedunculated juvenile polyp in a patient with JPC with polyp size greater than 25 mm. Epinephrine volume reduction of the polyp head was performed at the time of colonoscope insertion resulting in a smaller size and easier snare polypectomy done upon colonoscope withdrawal. Note the coagulation of the polyp head (B) and stalk (C) following amputation. JPC = Juvenile Polyposis Coli.

at time of colonoscope withdrawal as several minutes are required following injection to observe the decrease in polyp head size (20) (Fig. 2).

ELECTROSURGICAL PRINCIPLES AND THEIR APPLICATION TO SNARE POLYPECTOMY

Electrosurgical currents are characterized by their respective crest factors and duty cycles and combined with the variable voltages delivered by an electrosurgical generator (ESU) result in delivery of power or thermal energy, which is measured in watts. Crest factor refers to the ratio of a current wave form's peak amplitude versus the average amplitude. Duty cycle refers to the percent of total time that electrical current is delivered. Cutting current is associated with a more rapid heat increase compared with coagulation current and this causes cellular water to boil and resultant cell rupture, which results in cleavage of tissue lines along the electrode. Cutting current has a lower crest factor (little variability) and a higher duty cycle. Pure cutting current has a duty cycle of 100% (21). Use of cutting current alone, particularly with vascular juvenile polyps, is likely to result in significant postpolypectomy bleeding.

In contrast, coagulation current induces a slower increase in temperature and causes cells to dehydrate and shrink without cutting, resulting in tissue desiccation and is associated with a higher crest factor and a lower duty cycle (shorter period of actual current delivery in a given application time) (18). Pure coagulation current has a duty cycle of 6%, whereas blended currents have a duty cycle in the range of 12% to 80% and the built in pauses with a lower duty cycle allow for cooling of the target tissue and promotion of more of a coagulation effect. Coagulation current alone without cutting may also be effective for polypectomy because of the cutting properties of the snare. Newer ESUs have microprocessor technology that allows for dispersive grounding pad sensing and feedback to the generator of changes in tissue impedance during energy delivery resulting in adjustment of generator output to the lowest effective output (ie, less energy delivery) while maintaining the same voltage as tissue is cut and coagulated, and therefore, are ''smarter'' than older ESUs (21,22). Settings are ESU-specific and ''smart'' ESUs often have suggested default settings for polypectomy, which can be modified based on patient-specific risk factors. Lower settings are typically utilized on the right side of the colon compared with the left because of the thinner colonic wall on the right. Increased resistance to cutting during polypectomy may indicate entrapment of the snare in the polyp/stalk, which may be better navigated by slight adjustment of snare positioning rather than increasing the ESU settings if standard settings are being utilized.

ADVANCED TECHNIQUES

Large-based or broad-based polyps must be removed with care. Transection of the polyp close to the bowel wall risks perforation. The colonic wall is thin, in the range of 1.7 to 2.2 mm, especially on the right side of the colon (17). Submucosal injection of saline (saline-assisted polypectomy) can be used to elevate sessile polyps onto a submucosal saline cushion, allowing for safer resection. This is performed utilizing sterile normal saline with or without epinephrine, which is typically injected to raise a sessile polyp before application of electrocautery, thereby increasing the distance between the base of the polyp and the serosa (17,23,24). If the polyp is large, injection should initially be performed behind the polyp (proximally) in order to avoid obscuring the view of the polyp by lifting it away. Signs of a good submucosal injection include raising of the polyp and lack of vascular markings within the injection site (23). If there is no submucosal bleb, the injection needle may have penetrated the serosa and may require repositioning. Care should be taken to avoid snaring submucosal tissue. In the case of large sessile polyps, the endoscopist must assess the risk of polypectomy and the nature of the information to be gained before deciding whether the polyp should be removed endoscopically or surgically.

Adult gastroenterology-advanced endoscopists may perform endoscopic mucosal resection (EMR) for large flat or sessile colonic lesions with mucosal extension that do not appear cancerous and endoscopic submucosal dissection (ESD) for lesions, which are potentially cancerous with submucosal extension but these techniques have yet to find applicability in the pediatric age groups (24,25). Often segmental resection or multiple biopsies of sessile or broad-based polyps remove adequate tissue for pathologic differentiation. Occasionally large polyps may need to be reduced in multiple sessions for complete obliteration. Endoscopists should consider prophylactically closing high-risk polypectomy sites via clipping either based on patient characteristics (need for antithrombotic therapy or bleeding issue and in those patients who may not hemodynamically tolerate a bleed) or based on site characteristics (large or deep defects, identification of a ''target sign'' or in locations difficult to re-access endoscopically (15,19).

Rarely, cancers may present as intraluminal polypoid lesions in childhood. Endoscopic resection of these lesion may be hazardous because of intramural extension or increased vascularity of these lesions. Therefore, in the case of polypoid lesions with an irregular appearance, endoscopic biopsy to determine tissue type and adjuvant imaging may be beneficial before attempted endoscopic resection to reduce the risk of uncontrollable bleeding or perforation (26).

TECHNICAL TIPS

When multiple polyps are encountered, the most proximal should be initially removed in order that subsequent colonoscope passage does not precipitate hemorrhage over the base or stalk of an already amputated polyp. In the patient with large numbers of polyps, representative polyps should be removed or biopsied for pathologic analysis. In patients with FAP and in some patients with JPC, there are too many polyps typically present to biopsy or remove all of them. In that setting larger polyps should be biopsied or removed for histologic analysis.

After amputation, polyps should be retrieved for histologic analysis. Very small polyps can be suctioned through the endoscope and retrieved in a trap. Large polyps can usually be retrieved with the snare, with standard or foreign-body forceps, such as the Pentapod forceps, or by using the Roth retrieval net (Steris, US Endoscopy, Mentor, OH) (27). In patients with multiple polyps requiring removal, serial passage of the endoscope and polyp retrieval typically working in the proximal colon and moving distally may be required. If the endoscopist is unable to retrieve the polyp, the patient can be given an enema or the parents can be asked to strain the stool and submit the tissue when passed later for analysis if provided with an appropriate specimen container.

POTENTIAL COMPLICATIONS AND ANCILLARY EQUIPMENT

Ancillary equipment should be available before starting polypectomy, including needles for injection of saline or epinephrine (1 : 10,000 final concentration), detachable polypectomy loops, and hemostatic clips. Detachable polypectomy loops should be used with caution because of the possibility of inadvertent transection of the polyp with loop closure or inadequate hemostasis as well as entanglement in the polypectomy snare if deployed before polypectomy (28). Clipping is now readily available at most centers and in addition to management of postpolypectomy bleeding, clips can be utilized to mark sites for subsequent surgery, especially in the case of a suspicious lesion. Clipping a pedunculated polyp stalk after amputation of the polyp head is a very effective method to control postpolypectomy bleeding. Some practitioners recommend prophylactic clip placement on large stalks before snare electrocautery (16).

In addition to bleeding, which can occur following cold or hot snare application, hot snare polypectomy can be complicated by either colonic perforation or a condition known as postpolypectomy syndrome because of serositis related to transmural injury or peritoneal injection without associated perforation (11,24). Imaging to rule out perforation is required as well as hospitalization, but patients can usually be managed conservatively in the setting of post polypectomy syndrome without the need for surgery (24). Patients with a colonic perforation following polypectomy require hospitalization, broad spectrum antibiotic administration as well as surgical consultation.

Take home points

1. The majority of polyps in pediatric patients are pedunculated juvenile polyps with a highly vascular stalk.
2. Snaring the polyp close to the head rather than close to the colonic wall allows for easier therapeutic intervention if postpolypectomy bleeding occurs.
3. Electrosurgical principles guide settings for polypectomy and electrocautery.
4. Saline-assisted polypectomy, epinephrine volume reduction, hemoclip application, and related techniques may reduce the risk of polypectomy-related complications.
5. Cold snare technique has replaced use of hot biopsy forceps in adults for removal of small sessile polyps.

REFERENCES

1. Syngal S, Brand RE, Church JM, et al., American College of Gastroenterology. ACG clinical guideline: genetic testing and management of hereditary gastrointestinal cancer syndromes. *Am J Gastroenterol* 2015;110:223–62.
2. ten Hove JR, Bernstein CN, Oldenburg B. Putting Evidence into Practice: IBD Surveillance, Chromoendoscopy and Future Directions. *Am J Gastroenterol* 2018;113:313–6.
3. Rex DK, Boland CR, Dominitz JA, et al. Colorectal cancer screening: recommendation for physicians and patients from the U.S. Multi-Society Task Force on Colorectal Cancer. *Am J Gastroenterol* 2017;112:1016–30.
4. Laine L, Kaltenbach T, Barkun A, et al., SCENIC Guideline Development Panel. SCENIC international consensus statement on surveillance and management of dysplasia in inflammaroty bowel disease. *Gastrointest Endosc* 2015;81:489.e26–501.e26.

5. Nowicki MJ, Bishop PR, Subramony C, et al. Colonic chicken-skin mucosa in children with polyps is not a preneoplastic lesion. *J Pediatr Gastroenterol Nutr* 2005;41:600–6.
6. Gupta SK, Fitzgerald JF, Croffie JM, et al. Experience with juvenile polyps in North American children: the need for pancolonoscopy. *Am J Gastroenterol* 2001;96:1695–7.
7. Bigard MA, Gaucher P, Lassalle C. Fatal colonic explosion during colonoscopic polypectomy. *Gastroenterology* 1979;77:1307–10.
8. ASGE Standards of Practice CommitteeFisher DA, Maple JT, et al. Complications of colonoscopy. *Gastrointest Endosc* 2011;74:745–52.
9. ASGE Standards of Practice Committee. The management of antithrombotic agents for patients undergoing GI endoscopy. *Gastrointest Endosc* 2016;83:3–16.
10. Suzuki S, Gotoda T, Kusano C, et al. Width and depth of resection for small colorectal polyps: hot versus cold snare polypectomy. *Gastrointest Endosc* 2018;87:1095–103.
11. von Renteln D, Pohl H. Pushing the limit: how to get the most out of cold snares. *Am J Gastroenterol* 2016;111:1217–9.
12. Hewett DG. Cold snare polypectomy: optimizing technique and technology (with videos). *Gastrointest Endosc* 2015;82:693–6.
13. Waye JD. Colonoscopic polypectomy. *Diagn Ther Endosc* 2000;6:111–24.
14. Metz AJ, Moss A, McLeod D, et al. A blinded comparison of the safety and efficacy of hot biopsy forceps electrocauterization and conventional snare polypectomy for diminutive colonic polypectomy in a porcine model. *Gastrointest Endosc* 2013;77:484–90.
15. Bourke MJ, Rex DK. Tips for better colonoscopy from two experts. *Am J Gastroenterol* 2012;107:1467–72.
16. Moss A, Nalankilli K. Standardization of polypectomy technique. *Best Pract Res Clin Gastroenterol* 2017;31:447–53.
17. Waye JD. Endoscopic mucosal resection of colon polyps. *Gastrointest Endosc Clin North Am* 2001;11:537–48.
18. Kay M, Wyllie R. Colonoscopy, polypectomy and related techniques. In: Wyllie R, Hyams JS, Kay M, eds. *Pediatric Gastrointestinal and Liver Disease.* 5th ed. Philadelphia: Elsevier; 2016:705–26.
19. Kedia P, Waye JD. Colon polypectomy: a review of routine and advanced techniques. *J Clin Gastroenterol* 2013;47:657–65.
20. Hogan RB, Hogan RB 3rd. Epinephrine volume reduction of giant colon polyp facilitates endoscopic assessment and removal. *Gastrointest Endosc* 2007;66:1018–22.
21. ASGE TECHNOLOGY COMMITTEE. Electrosurgical generators. *Gastrointest Endosc* 2013;78:197–208.
22. Morris ML, Bowers WJ. Math, myth and fundamentals of electrosurgery. *J Hepatol Gastroenterol* 2016;1:1–5.
23. Zuccaro GJ. The difficult colon polyp. *Am J Gastroenterol* 2004;99:11–2.
24. Burgess NG, Bahin FF, Bourke MJ. Colonic polypectomy (with videos). *Gastrointest Endosc* 2015;81:813–35.
25. Wallace MB. New strategies to improve polypectomy during colonoscopy. *Gastroenterol Hepatol* 2017;13(10 Suppl 3):3–10.
26. Liu S, Ginsberg JP, Mamula P. Transverse colon mass. *J Pediatr Gastroenterol Nutr* 2006;43:559–60.
27. Miller K, Waye JD. Polyp retrieval after colonoscopic polypectomy: use of the Roth Retrieval Net. *Gastrointest Endosc* 2001;54:505–7.
28. Matsushita M, Hajiro K, Takakuwa H, et al. Ineffective use of a detachable snare for colonoscopic polypectomy of large polyps. *Gastrointest Endosc* 1998;47:496–9.