

# Evaluation and Management of Postsurgical Patient With Hirschsprung Disease Neurogastroenterology & Motility Committee: Position Paper of North American Society of Pediatric Gastroenterology, Hepatology, and Nutrition (NASPGHAN)

\*Lusine Ambartsumyan, MD, †Dhiren Patel, MD, ‡Prasanna Kapavarapu, MD, §Ricardo A. Medina-Centeno, MD, ||Khalil El-Chammas, MD, ¶Julie Khlevner, MD, #Marc Levitt, MD, and \*\*\*Anil Darbari, MD, MBA

## ABSTRACT

Children with Hirschsprung disease have postoperative long-term sequelae in defecation that contribute to morbidity and mortality and significantly impact their quality of life. Pediatric patients experience ongoing long-term defecation concerns, which can include fecal incontinence (FI) and postoperative obstructive symptoms, such as constipation and Hirschsprung-associated enterocolitis. The American Pediatric Surgical Association has developed guidelines for management of these postoperative obstructive symptoms and FI. However, the evaluation and management of patients with postoperative defecation problems varies among different pediatric gastroenterology centers. This position paper from the Neurogastroenterology & Motility Committee of the North American Society for Pediatric Gastroenterology, Hepatology, and Nutrition reviews the current evidence and provides suggestions for the evaluation and management of postoperative patients with Hirschsprung disease who present with persistent defecation problems.

**Key Words:** aganglionosis, anorectal manometry, colonic manometry, constipation, dysmotility, fecal incontinence, Hirschsprung associated enterocolitis, Hirschsprung disease, pediatric neurogastroenterology and motility program

(*JPGN* 2023;76: 533–546)

**H**irschsprung disease (HD) is a congenital abnormality of the enteric nervous system characterized by the absence of

Received August 22, 2022; accepted January 19, 2023.

From the \*Division of Gastroenterology and Nutrition, Seattle Children's Hospital, University of Washington School of Medicine, Seattle, WA, the †Division of Pediatric Gastroenterology, Hepatology and Nutrition, Cardinal Glennon Children's Medical Center, Saint Louis University School of Medicine, St Louis, MO, the ‡Division of Pediatric Gastroenterology, Hepatology and Nutrition, Children's Hospital of Philadelphia, Philadelphia, PA, the §Division of Gastroenterology, Hepatology and Nutrition, Phoenix Children's, College of Medicine, University of Arizona, Tucson, AZ, the ||Division of Gastroenterology, Cincinnati Children's Hospital Medical Center, University of Cincinnati College of Medicine, Cincinnati, OH, the ¶Division of Gastroenterology, Hepatology and Nutrition, Columbia University Vagelos College of Physicians and Surgeons, New York, NY, the #Division of Colorectal and Pelvic Reconstruction, Children's National Hospital, Washington, DC, and the \*\*Division of Gastroenterology and Nutrition, Children's National Hospital, Washington, DC. Address correspondence and reprint requests to Lusine Ambartsumyan, MD, Associate Professor, Pediatrics, University of Washington School of Medicine, Director, Gastrointestinal Motility Program, Division of

## What Is Known

- Pediatric patients with Hirschsprung disease (HD) can experience long-term defecation disorders after their pull-through surgery including fecal incontinence and obstructive symptoms such as constipation and Hirschsprung-associated enterocolitis.
- The evaluation and management of patients with postoperative defecation problems varies among different pediatric gastroenterology centers.

## What Is New

- This position paper offers evidence-based general principles for the evaluation and management of postoperative patients with HD who present with defecation problems.
- It demonstrates the indispensable collaborative effort between Gastroenterology and Surgery subspecialties in the care of patients with HD.

ganglion cells within the submucosal and myenteric plexuses (1). The aganglionic segment fails to relax during peristalsis producing a functional obstruction. Patients commonly present in the first

Gastroenterology and Hepatology, Seattle Children's Hospital, 4800 Sand Point Way NE, Seattle, WA 98105 (e-mail: lusine.ambartsumyan@seattlechildrens.org).

The authors report no conflicts of interest.

This article has been developed as a Journal CME and MOC Part II Activity by NASPGHAN. Visit <https://learnonline.naspgan.org/> to view instructions, documentation, and the complete necessary steps to receive CME and MOC credits for reading this article.

Disclaimer: NASPGHAN is not responsible for the practices of physicians and provides guidelines and position papers as indicators of best practice only. Diagnosis and treatment is at the discretion of physicians.

Supplemental digital content is available for this article. Direct URL citations appear in the printed text, and links to the digital files are provided in the HTML text of this article on the journal's Web site ([www.jpjn.org](http://www.jpjn.org)).

Copyright © 2023 by European Society for Pediatric Gastroenterology, Hepatology, and Nutrition and North American Society for Pediatric Gastroenterology, Hepatology, and Nutrition.

DOI: 10.1097/MPG.00000000000003717

year of life with delayed passage of meconium, feeding intolerance, abdominal distention, vomiting, Hirschsprung-associated enterocolitis, and intestinal obstruction (1–3). Hirschsprung-associated enterocolitis is the most recognized complication of HD with a mortality rate of 1%–10% and may present preoperatively in up to 60% of patients (4–8). Patients undergo pull-through surgery after histopathological confirmation of the diagnosis. There are 3 well-described pull-through techniques: Swenson, Yancey/Soave, and Duhamel (Fig. 1). The goal of surgery is to remove the aganglionic segment of bowel, relieve the functional obstruction, and preserve the continence mechanism. Comprehensive review of the epidemiology, clinical presentation, diagnostic testing, and surgical treatment of HD can be found in the Supplemental Digital Content, <http://links.lww.com/MPG/D60>.

Advances in diagnostic and surgical techniques have improved outcomes, but a significant number of patients continue to struggle with postoperative defecation disorders that negatively impact their quality of life (9). Children with HD may experience fecal incontinence (FI) and/or postoperative obstructive symptoms such as constipation, undernutrition, and Hirschsprung-associated enterocolitis (10). Timely recognition, evaluation, and management of a postsurgical patient with these symptoms is essential to decrease their morbidity and mortality. The American Pediatric Surgical Association recently developed guidelines for the management of postoperative obstructive symptoms and FI (6,11). However, the evaluation and management of a postsurgical patient with HD who presents with symptoms varies considerably among different Pediatric Gastroenterology Centers. The objective of this societal position paper is to review the current literature and provide suggestions for pediatricians and pediatric gastroenterologists regarding the evaluation and management of the postsurgical patient with HD who presents with postoperative sequelae and defecation problems.

**METHODS**

A literature search was conducted using PubMed/MEDLINE/EMBASE databases applying the following terms: Hirschsprung disease, Hirschsprung, aganglionic megacolon, congenital megacolon, rectosigmoid colon aganglionosis, rectosigmoid aganglionosis, congenital intestinal aganglionosis, colonic aganglionosis, and Hirschsprung associated enterocolitis. Literature searches

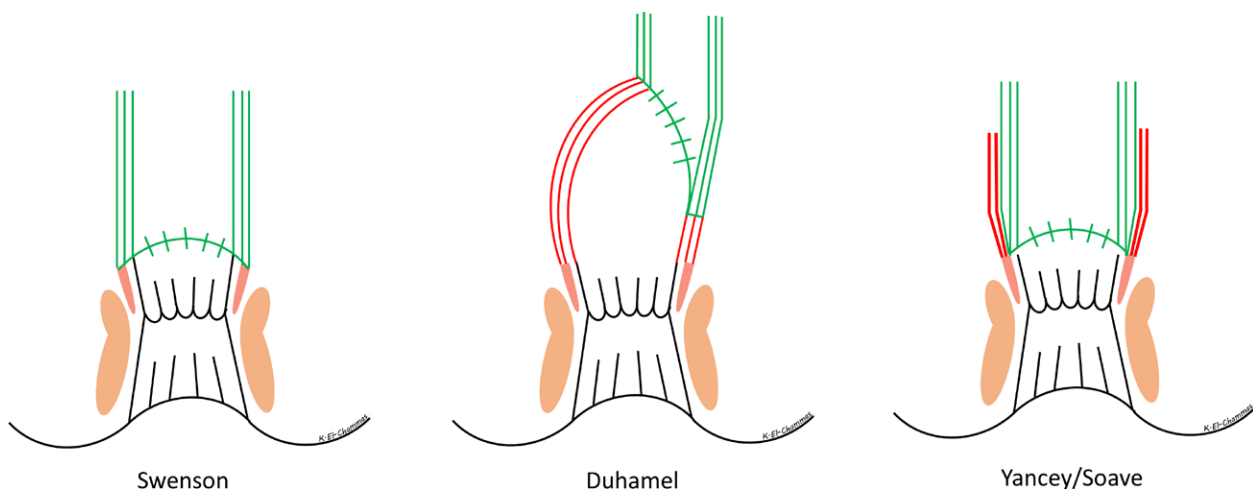
were conducted through August 2022. Non-English literature was excluded. The authors of this position paper contributed, reviewed, and edited the content of this position paper. Recommendations and best practices expressed in this position paper are devised from the available literature and the expert opinion of the North American Society for Pediatric Gastroenterology, Hepatology, and Nutrition Neurogastroenterology & Motility special interest group members. The authors used electronic and phone communication to resolve disagreement, reach consensus, and modify the recommendations and best practices of this position paper.

**POSTOPERATIVE COMPLICATIONS OF HD**

The majority of HD patients following surgery recover well, stool spontaneously, and have bowel control. Despite significant development in the understanding of the pathophysiology and improvements in the operative management, HD for some patients remains a lifelong condition with multiple late postoperative morbidities including obstructive symptoms, Hirschsprung-associated enterocolitis, undernutrition, constipation, FI, and psychosocial issues (12). These complications are not uncommon, occur in infancy and can extend into adulthood (10). Long-term postoperative problems include Hirschsprung-associated enterocolitis (25%–37%) (8) and disorders of defecation such as constipation (6%–40%) (13–16) and FI (8%–74%) (14,17,18). The incidence of postoperative problems varies in the literature because of heterogeneous clinical definitions and study end points, study methodology, surgical technique/medical treatment, and clinical length of follow-up (14).

A recent study aiming to evaluate quality of life outcomes using validated functional and quality of life questionnaires in HD patients between 2 and 10 years of age showed that patients with HD scored significantly lower in psychosocial quality of life compared to healthy children. Furthermore, FI, constipation, and dysfunctional elimination significantly decreased the total quality of life score and FI alone decreased physical quality of life in the studied patient population (9). This data supports the importance of long-term care and the involvement of a psychologist or mental health professional in the management of children with HD to improve social and emotional quality of life outcomes.

Given multiple complexities associated with HD and the reported deterioration of functional outcome and quality of life



**FIGURE 1.** Diagrams of 3 common pull-through operations for Hirschsprung disease. From left to right: full-thickness rectosigmoid dissection (Swenson), a recto-rectal pouch procedure (Duhamel), an endorectal dissection (Soave).

with age (19), children with HD should be followed closely by a multi-disciplinary care team through adulthood (20) consisting of providers who have expertise in HD; a colorectal surgeon, gastroenterologist/neurogastroenterologist, dietitian, nurse/advanced practice nurse, social worker, and a psychologist (21). A multi-disciplinary and collaborative team approach in this specialized patient population allows for combined medical and surgical decision, facilitates therapy, and can improve patient outcomes (22).

## OVERVIEW OF ASSESSMENT OF A SYMPTOMATIC POSTSURGICAL PATIENT

1. Children who experience postoperative problems should have a detailed history to assess for new onset or worsening symptoms with emphasis on identifying postoperative complications.
2. Thorough physical examination should be performed including growth parameters, abdominal examination, and perineal/rectal examination if possible.
3. The original pathology should be reviewed by an experienced pathologist to ensure that there is no residual aganglionosis or transition zone pull-through. If the pathology is inadequate or not available, a re-biopsy can be done at the time of rectal exam under anesthesia to ensure normal enteric innervation of the pull-through bowel.
4. Diagnostic imaging, including abdominal X-ray and contrast enema, should be considered in order to evaluate for mechanical or anatomical abnormalities.
5. Rectal exam under anesthesia should be performed by an experienced surgeon to assess for mechanical causes for obstruction and to evaluate the integrity of the anorectum.
6. Once the anatomic and pathologic evaluation has been completed and is negative, then a functional assessment of the anorectum and colon should be considered at a designated Neurogastroenterology & Motility Center.
7. Anorectal Manometry (ARM) is used to evaluate the voluntary (sensation, squeeze, and ability to bear down) and the involuntary (resting anal pressure and the presence and characteristics of the recto-anal inhibitory reflex) properties of the anorectum (23). Some children may have elevated intra-anal pressures and benefit from botulinum toxin injection into the anal sphincter. Others may have abnormal (deficient) intra-anal pressures or squeeze pressures indicative of damage to the anal sphincter complex.
8. Colonic manometry (CM) is used to evaluate the neuromuscular integrity of the colon and for planning medical and surgical management (23–26). CM by a neurogastroenterology and motility expert should be considered in patients who continue to have symptoms refractory to treatment in whom all anatomic and pathologic causes for obstruction have been ruled out.

## Postoperative Obstructive Symptoms (Fig. 2)

*An 18-month-old female with HD, who has undergone a one-stage Yancey/Soave pull-through at 2 weeks of life, presents with failure to thrive, constipation, and recurrent Hirschsprung-associated enterocolitis.*

### History

Patients with postoperative obstructive symptom may present with abdominal distention, vomiting, failure to thrive, or recurrent Hirschsprung-associated enterocolitis (6,17,27). They may have severe constipation, with or without associated FI that is refractory to laxative treatment rendering some patients dependent on rectal

therapy or trans-anal irrigations. Others may present with recurrent or chronic enterocolitis, also concerning for an obstructive etiology. Mechanical or functional obstruction may lead to stasis, bacterial overgrowth, and increased risk of bacterial translocation and enterocolitis (28). Thus, in patients with recurrent or chronic Hirschsprung-associated enterocolitis it is important to initiate a timely work-up to evaluate for underlying mechanical, histological, and functional etiologies.

### Histopathology

The histological evaluation is necessary for all patients with HD who have undergone corrective surgery and continue to have postoperative problems. Histopathological etiologies of a defecation disorder include residual or acquired aganglionosis, skip area, and a transition zone pull-through (28–30). The original pathology should be reviewed by an experienced pathologist who is well versed in the diagnosis of HD and the above-listed pathological aberrations. A detailed discussion differentiating these etiologies is beyond the scope of this paper and can be reviewed in Kapur et al (28). It is important to note that if a histological review is not possible or if, once completed, it is inconclusive, then a repeat full thickness biopsy should be done at the time of the rectal exam under anesthesia to ensure normal enteric innervation of the pull-through bowel (6).

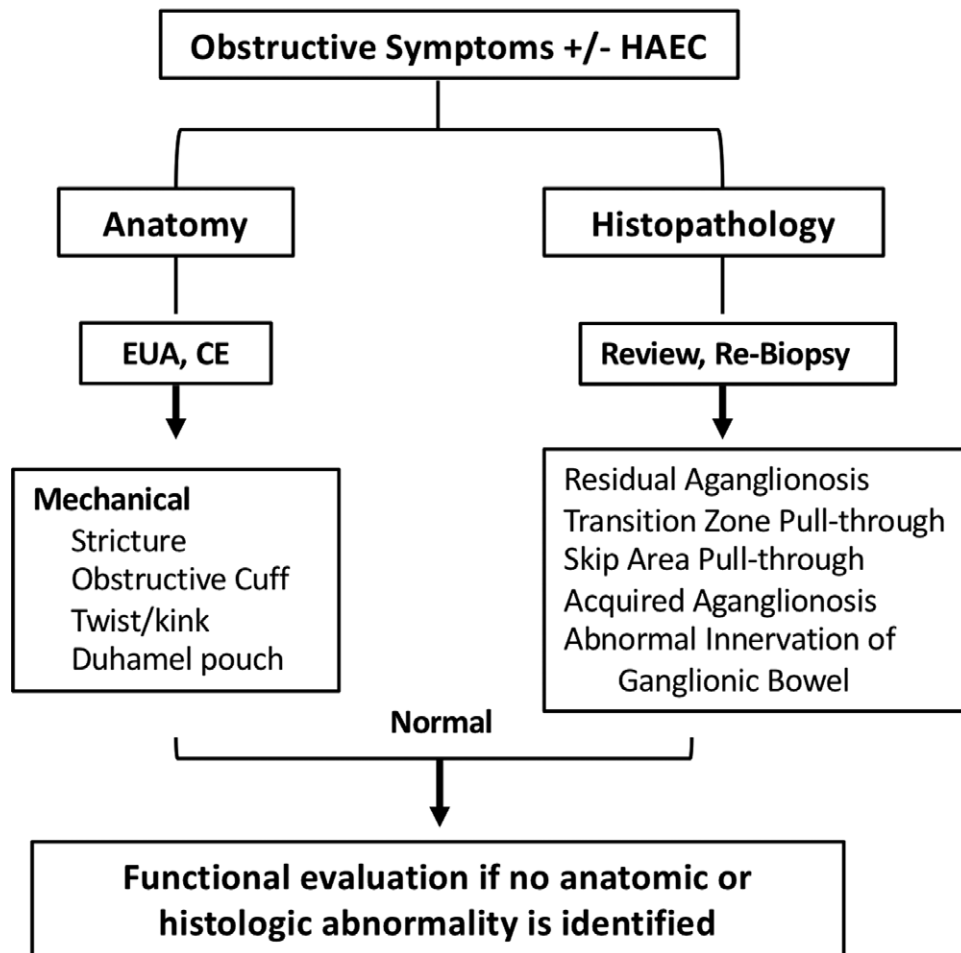
### Anatomy

Children with HD who have undergone corrective surgery and present with obstructive symptoms warrant an evaluation of their anatomy looking for mechanical causes of obstruction (Fig. 3). An anastomotic stricture can be identified on digital rectal examination or during rectal exam under anesthesia (6,27). The contrast enema may show a narrowing of the lumen at the anastomotic site with proximal dilatation (27). A tight muscular cuff, in patients who had a Yancey/Soave procedure, can be palpated on a rectal exam under anesthesia, and can be further delineated by a widened presacral space on a contrast enema (31). A kink or a twist of the pull-through colon may be identified on rectal exam under anesthesia or seen on a contrast enema (32,33). Patients who have had the Duhamel procedure may have a retained spur that can lead to stool impacting in the native rectum, and because of the spur this stool presses back onto the sacrum, obstructing the ganglionated pull-through. Also, the Duhamel pouch can become dilated with retained stool and cause an obstruction; both scenarios can be characterized on the contrast enema (34,35). Additionally, some patients may have a retained aganglionic segment or transition zone pull through that can be suspected on the contrast enema (34) and confirmed by repeat biopsy.

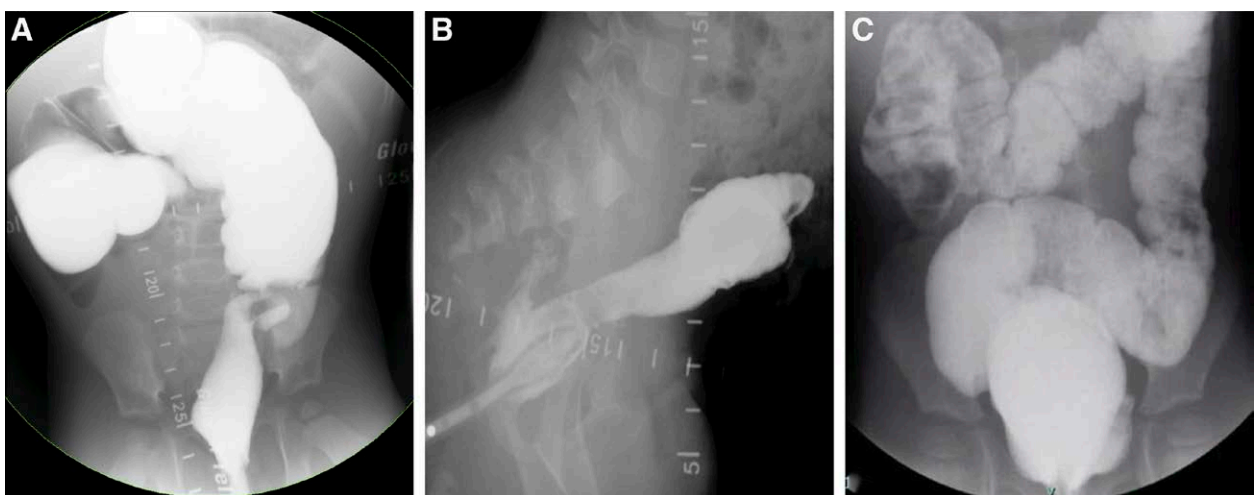
### Management

#### *Hirschsprung-Associated Enterocolitis*

Patients with Trisomy 21 and congenital malformations, prior history of Hirschsprung-associated enterocolitis, long-segment disease, and those with obstructive symptoms are at increased risk of developing Hirschsprung-associated enterocolitis (8,36,37). The presentation can range from mild nonspecific symptoms to abdominal distention, fever, diarrhea, rectal bleeding, vomiting, lethargy, and septic shock (8). Early recognition and prompt intervention with hydration, antibiotics, and rectal irrigations are the mainstay of management. Gosain et al (8) developed a guideline for diagnosis and grading of Hirschsprung-associated enterocolitis (probable, definite, severe) based on clinical history, physical examination, and radiographic findings. They proposed a guideline for management based on the diagnostic grading. Please refer to



**FIGURE 2.** Diagnostic approach to a postsurgical patient with Hirschsprung disease who has persistent obstructive symptoms and/or Hirschsprung associated enterocolitis (HAEC). CE = contrast enema; EUA = rectal exam under anesthesia.



**FIGURE 3.** Mechanical causes of obstruction on contrast enema. (A) Twisted pull-through. (B) Retained Soave cuff as evidenced by increase in pre-sacral space with fistula to a presacral abscess. (C) Retained transition zone with a distal pull-through.

Downloaded from http://journals.lww.com/jpgn by BHDMSepHKav1zEoum1tQIN4akJLhEz9sH04XM10hC0ywcX1AW nYQp/1QrHID3D00DFRy7vSF14C13V/C4/OAV/VDa8K2+Ya6H515KE= on 03/22/2023

the published guidelines by Gosain et al (8) for a comprehensive review of diagnosis and management of Hirschsprung-associated enterocolitis.

### Obstructive Symptoms

Stimulant laxatives should be used in postoperative patients with obstructive symptoms for whom no anatomic or pathologic explanation of obstruction has been identified (Table 1). The goal of treatment is to improve colonic emptying and to effectively decompress the colon in order to decrease the risk of Hirschsprung-associated enterocolitis and to prevent progressive neuromuscular

compromise of the large bowel. Sennosides and bisacodyl are stimulant laxative with primary colonic site of action that increase fluid secretion, decrease colonic transit, and alter colonic motility (38–40). Both have been shown to be safe and effective in the short- and long-term management of constipation (40–44). Please refer to Table 1 for optimal dosing suggestions. The dose should be tailored to achieve adequate colonic emptying with minimal intolerable symptoms such as cramping. If a patient is refractory to oral laxative therapy with significant obstructive symptoms (recurrent Hirschsprung-associated enterocolitis, continued constipation/FI) then referral to a Neurogastroenterology & Motility Center should be considered.

TABLE 1. Dosages of frequently used oral and rectal medications (including antegrade enemas)

Medication	Dosages
<b>Oral stimulants</b>	
Sennosides	Tablet (8.6 mg/tab)/liquid (8.8 mg/5 mL)/chewable (15 mg/chew): 1 mo to < 2 y: 2.2 mg QD–8.8 mg QD 2 y to < 6 y: 4.4 mg QD–17.6 mg QD 6 y to < 12 y: 8.8 mg QD–35.2 mg QD >12 y: 17.6 mg QD–70.4 mg QD
Bisacodyl	Tablet (5 mg/tab) 3–10 y: 5 mg QD 10 to <12 y: 5–10 mg QD >12 y: 5–15 mg QD
<b>Anti-motility agents</b>	
Loperamide	0.1–0.8 mg/kg/d divided TID to QID (max 16 mg/d)
Atropine/diphenoxylate	0.3–0.4 mg/kg/d divided QID (max 10 mg/d diphenoxylate)
Hyoscyamine	Oral drops, elixir, tablet (sublingual) Dosing based on weight and age
Dicyclomine	10 mg PO TID–QID (max 40 mg/d) (children >8 y)
Cholestyramine	Toddler 2 g QID Child 2 g BID to 4 g TID Adolescent 4 g BID to 4 g TID/QID
<b>Suppositories/low volume enemas</b>	
Glycerin	Suppository Infants to 6 y: pediatric 1 g > 2 w > 6 y: adult 2 g Enema Infants to 6 y: PediaLax 2.8 g (4mL) >6 y: Fleet 5.4 g (7.5 mL)
Bisacodyl	Suppository/enema 2–8 y: 5 mg QD >8 y and adolescents: 5–10 mg QD
Docusate	Enema 2 to < 12 y: 100 mg/5 mL QD, 283 mg/5 mL QD >12 y: 283 mg/5 mL QD to TID
<b>High volume enemas/ACE solution</b>	
<b>Solution</b>	
Normal Saline	
GoLyteLy	
Tap Water	
<b>Additives</b>	
Glycerin	Start with 5% concentration and can increase to max of 15% (ie, 20 mL glycerin/400 mL of normal Saline → 60 mL glycerin/400 mL normal Saline)
Castile Soap	Typically, castile soap is maxed out at 18–20 mL
Bisacodyl	Can be given 10–15 min pre or post enema/ACE solution. Some centers mix the bisacodyl into the flush which can dilute the bisacodyl.

BID = twice a day; QD = once a day; QID = four times a day; TID = three times a day.

## Role of a Neurogastroenterology & Motility Expert

### Evaluation

Abnormalities of anorectal function can lead to functional obstruction and include non-relaxing internal anal sphincter (IAS), withholding, and poor pelvic floor dysfunction (45–47). In HD, the aganglionic segment begins at the IAS and extends proximally; thus, despite surgical correction patients always have an absent recto-anal inhibitory reflex (non-relaxing IAS) and dysfunction of the anal sphincter must be anticipated. Some can overcome the sphincter dysfunction and others are unable to compensate for the altered defecation dynamics and continue to struggle with functional obstruction and obstructive symptoms. These patients should undergo ARM in order to evaluate the resting intra-anal pressures (23,48,49).

### Management

Normal or elevated IAS pressures in the setting of obstructive symptoms warrants IAS botulinum toxin administration into the anal sphincter (6,48–51). Different cut-off values for “normal” IAS pressures for administration of botulinum toxin have been used in pediatric studies (>50 mmHg (49), >60 mmHg (48), and >80 mmHg) (51). IAS botulinum toxin has been shown to improve stooling, decrease obstructive symptoms, Hirschsprung-associated enterocolitis episodes, and associated hospitalizations (48,50,52–54). In their pediatric cohort, Chumpitazi et al (48) reported improvement in bowel movement frequency and obstructive symptoms in 90% of their HD patients within 2 weeks of injection with a mean duration of improvement lasting nearly 10 months. A recent systematic review and meta-analysis revealed that IAS botulinum toxin injections were effective in treating obstructive symptoms in 66% of pooled patients for whom a mean duration of improvement lasted 6.4 months requiring an average of 2.6 procedures (55). A reduction in mean IAS pressures on ARM following IAS botulinum toxin injections were reported in 3 studies, whereas manometric findings were not reported in the remaining 11 studies (52). On the contrary, no difference in mean intra-anal pressures on ARM were observed at 2 weeks and 3 months following IAS botulinum toxin administration in 15 post pull-through HD patients with persistent constipation (56).

The dose, frequency, and technique of IAS botulinum toxin administration varies in the literature. Langer et al recommend a total dose of 60–100 units diluted in 1.0 mL of normal saline (maximum concentration of 100 U/mL) to be given in multiple injections of 0.1 mL circumferentially at the level of the dentate line (6). Adverse events associated with IAS botulinum toxin administration include anal pain and temporary FI in 17% of patients (48,52,55). IAS botulinum toxin injections are favored as initial treatment option over IAS myectomy/myotomy given the increased risk of long-term incontinence with these procedures (57,58). Lack of response to IAS botulinum toxin may indicate that abnormal anorectal function may not be the sole reason for the obstructive symptoms and there may be underlying colonic dysfunction.

Recommendations for a patient with postoperative obstructive symptoms:

1. The evaluation of children with postoperative obstructive symptoms should begin with a detailed history and physical examination.
2. Diagnostic testing, such as contrast enema, should be performed to evaluate for mechanical causes of obstruction.
3. The original pathology should be reviewed by an experienced pathologist to ensure that there is no residual aganglionosis or transition zone pull-through. If the pathology is inadequate or not available, a re-biopsy can be done at the time of rectal exam

under anesthesia to ensure normal enteric innervation of the pull-through bowel.

4. Rectal exam under anesthesia should be performed to evaluate for mechanical causes of obstruction.
5. Children with a negative anatomic and pathologic evaluation should be started on daily stimulant laxatives. The dose should be tailored to achieve adequate colonic emptying.
6. Children who are compliant but are not responsive to oral laxative therapy should be referred to a Neurogastroenterology & Motility Center for evaluation and management.
7. Children with obstructive symptoms who have normal or elevated IAS pressures on ARM should receive IAS botulinum toxin administration into the anal sphincter.

### Postoperative Constipation

*5-Year-old male with HD who has undergone a 1-stage Swenson pull-through at 10 days of life presents with constipation and FI. The anatomical evaluation was normal with an intact dentate line.*

### History

Patients with postoperative constipation present with signs and symptoms of constipation supported by history, physical examination, and radiographic findings. In patients who present with FI it is important to differentiate between FI associated with stool retention and non-retentive FI. This distinction is important as patients who have FI associated with stool retention are considered to have obstructive symptomatology and warrant an appropriate diagnostic workup and treatment. Patients with retentive FI may have abdominal distention, emesis, poor growth, recurrent fecal impactions necessitating cleanouts, small smears, and/or constant fecal leaking throughout the day. Their physical examination is notable for significant rectal and/or abdominal stool accumulation. If the history and the physical examination are not sufficient to differentiate between retentive and non-retentive FI then a radiopaque marker study may be helpful to evaluate the colonic transit. While the studies in pediatrics are limited and normative pediatric data is lacking (59–61), the radiopaque marker study can serve as an adjunct to the history and physical examination. There are different protocols used in adults of which the single capsule technique is the least cumbersome. Patients are instructed to swallow 1 capsule containing 24 radiopaque markers on day 0 and obtain an abdominal X-ray on day 5 (120 hours). Abnormal colonic transit is defined as  $\geq 20\%$  retention of markers ( $\geq 5$  markers) on the day 5 abdominal X-ray (62). The retention of the markers in the rectum or the colon implies outlet obstruction and slow colonic transit, respectively and is suggestive of retentive FI. The appropriate passage of markers indicates normal colonic transit and is supportive of non-retentive FI.

### Histopathology

Evaluation of the original pathology by an experienced pathologist is necessary to exclude residual aganglionosis and a transition zone pull-through. If the histological review is inconclusive or the original biopsies are not available for review, then a repeat biopsy should be done at the time of the rectal exam under anesthesia to ensure normal enteric innervation of the pull-through bowel (6).

### Anatomy

Patients who present with FI associated with stool retention warrant a contrast enema and a rectal exam under anesthesia to evaluate for an underlying mechanical causes of obstruction as described in the previous section. Significant stool retention secondary to mechanical obstruction would then lead to overflow FI. These patients may also have a compromised anal canal and/or

disrupted integrity of the anorectum that can be evaluated on rectal exam under anesthesia. Iatrogenic damage to the dentate line or the anal sphincters during pull-through surgery would also predispose patients to FI in the setting of obstructive symptomatology.

## Management

The goals of treatment are to optimize colonic emptying, preserve colonic neuromuscular integrity, and achieve fecal continence. If the patient has a fecal impaction, they should undergo fecal disimpaction prior to initiation or escalation of medications. Osmotic laxatives, such as polyethylene glycol, lactulose, or milk of magnesia, should be used with caution when used for maintenance therapy as they make the stools looser and may worsen FI (63). As mentioned above, stimulant laxative, sennosides, and bisacodyl are the mainstay of maintenance treatment. Higher doses may be necessary to achieve optimum colonic emptying. However, at higher doses patients may have looser stools and an increase in FI. Therefore, soluble fiber can be used as a bulking agent to change the consistency of the stool and yet ensure that there is adequate colonic emptying. Of note, significant skin blistering and perianal rash are rarely associated with high doses of sennosides and are thought to be due to increased skin to stool contact (42,64). Patients should be followed closely in the outpatient setting to ensure (a) clinical improvement of constipation and resolution of FI and (b) radiographic improvement of fecal loading and colonic caliber. If there is lack of clinical and/or radiographic improvement, then referral to a Neurogastroenterology & Motility Center may be considered to assess anorectal and colonic function.

## Role of a Neurogastroenterology & Motility Expert

### Evaluation

Functional obstruction in a postsurgical patient with HD presenting with obstructive symptoms may be secondary to abnormal anorectal and/or colonic function. Abnormalities of anorectal function include non-relaxing IAS, withholding, and poor pelvic floor dysfunction (45–47). As mentioned above, patients who have obstructive symptoms and have normal or elevated IAS pressures (>50 mmHg) should undergo IAS botulinum toxin administration. Abnormal defecation dynamics and stool withholding behavior can exist in isolation or in conjunction with elevated intra-anal pressures and colonic dysfunction (47,51,65). Constipation and painful defecation in the setting of a non-relaxing IAS can create maladaptive behaviors and further worsen underlying obstructive symptoms (46). It is important to recognize these key contributors and address them concurrent with other treatments such as laxatives and IAS botulinum toxin. Studies implementing multi-disciplinary behavioral treatment operating within the principles of the biopsychosocial model of care which utilize medical intervention, behavioral therapy, and physiotherapy have shown significant improvement in defecation symptoms specifically in children with HD (45,46).

Abnormal colonic function should be suspected in patients with continued obstructive symptoms who (a) are compliant but have inadequate response to recommended laxative therapy (Table 1), (b) have low/reassuring intra-anal pressures on ARM, (c) do not clinically improve following IAS botulinum toxin administrations, (d) are reliant on rectal therapy and (e) are failing rectal or antegrade enemas. CM to further delineate colonic dysfunction could be considered only after an anatomic or pathologic cause has been ruled out. In patients with obstructive symptoms, including constipation with or without retentive FI, findings on CM can range from normal to segmental or total colonic dysmotility. In their pediatric cohort, Martin et al described 2 patients with HD who had obstructive symptoms, were found to have global colonic dysmotility, and underwent a diverting ileostomy (66). They reported

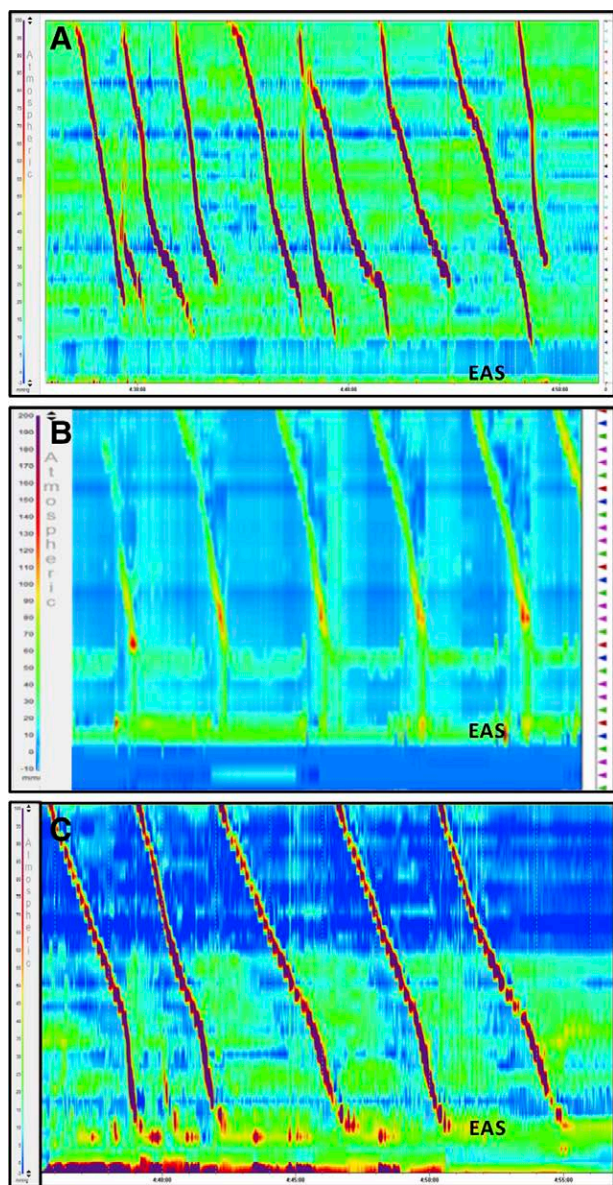
that a repeat CM showed improvement in motility in both patients supportive of ostomy takedown. Improved colonic dilation and manometry findings have been described in patients with refractory constipation who had a diverting ostomy (67,68). Di Lorenzo (51) et al used CM to investigate persistent postoperative gastrointestinal symptoms in children with HD. They identified 4 manometric patterns and implemented corresponding treatment that resulted in improved clinical symptoms and quality of life parameters. Three of the 4 patterns were more supportive of findings in children with obstructive symptoms. Patients with a pattern of normal CM associated with stool withholding were given stool softeners and behavioral modification. Patients with normal CM and hypertensive IAS (>80 mmHg) underwent IAS botulinum toxin. Lastly, those with a pattern of segmental or total colonic dysmotility associated with constipation were recommended to have a surgical resection of the dysmotile segment.

Further studies are needed to fully elucidate the utility of CM in postsurgical HD patients with obstructive symptoms in whom an anatomic and pathologic cause has been ruled out. If CM were to be done in a patient with a distal obstruction, the findings may show colonic dysmotility when in fact the colon would function well if the distal obstruction was removed (ie, with a redo of the pull-through). A recent systematic review identified 5 studies that describe CM in children with HD (69). The authors concluded that the studies are hampered by heterogeneous cohorts, variable study design, a lack of standardized manometric definitions, and a lack of validated symptom severity and outcome measures (69). Our knowledge regarding CM primarily derives from investigating patients with refractory constipation. CM should be considered prior to surgical decision-making in the appropriate clinical setting.

In a retrospective pediatric study, Mugie et al demonstrated that abnormal CM was associated with poor antegrade continence enema (ACE) outcomes; 8 out of 99 patients had HD (70). In a similar study, van den Berg et al reported that the presence and absence of high amplitude propagating contractions (HAPCs) was a predictor of cecostomy success and failure, respectively; 2 out of 32 patients had HD (71). Studies in pediatrics have also shown improvement in CM parameters following ACE (72,73). Both studies consisted of heterogeneous patient groups with very small numbers of HD patients in each study. CM may be repeated if the patient is not successful with an ACE and an ileostomy is being considered. In patients with total colonic dysmotility, especially in the setting of colonic dilation, a diverting ileostomy should be considered. Re-anastomosis can be done in patients who have return of colonic motility on CM and complete resolution of their obstructive symptoms following the diversion (Fig. 4). Thus, CM may provide valuable baseline information regarding colonic motility prior to surgical intervention in the appropriate clinical setting.

### Management

If a patient is refractory to oral laxative therapy, then a retrograde enema program is helpful as it provides a mechanical way to empty the colon and avoids oral medications. Rectal therapies include suppositories (glycerin, bisacodyl), low-volume enemas (sodium phosphate, glycerin, docusate, bisacodyl), and high-volume enemas administered via continence enema catheter or a trans-anal irrigation system. High-volume enemas consist of an enema solution [10–20 mL/kg (maximum of 1 L) of tap water, normal saline, or GoLyte] (74,75) mixed with additives (glycerin or castile soap) (70,76–78). To date there are no pediatric guidelines or recommendations regarding weight-based dosing for additives or optimum concentration of the enema solution. Solutions that are hyperosmolar may cause electrolyte derangements and chemical colitis (79). Caution should be taken in children with HD who have obstructive physiology and are at risk of enema retention due



**FIGURE 4.** High resolution colonic manometry. (A) Normal colonic manometry with HAPCs propagating from cecum to rectosigmoid junction. (B) Abnormal colonic manometry with termination of the HAPCs at the descending colon. (C) Abnormal colonic manometry with termination of the HAPCs at the EAS. EAS = external anal sphincter; HAPCs = high amplitude propagating contractions.

to anorectal and/or colonic dysfunction. Retention of a “normal saline” or sodium phosphate enema may cause hyperphosphatemia, hypocalcemia, and hypokalemia (80,81). Additionally, high-volume enemas containing tap water have been reported to cause shifts in electrolytes and hyponatremia (82,83).

Rectal high-volume enemas in children with HD have been historically implemented by colorectal centers as a structured bowel management program (76,84). They have been shown to improve FI and quality of life in children with organic and functional constipation and FI in patients with HD (76,77,85–89). High-volume rectal enemas have also been used to care for children with neurogenic bowel, anorectal malformations, and functional FI. Given the

variability in practice between specialties and centers, Mosiello et al (74) conducted a consensus review of trans-anal irrigations and published best-practice recommendations. Patients who are doing well on rectal enemas but desire to have independence and/or prefer an alternate route for administration of high-volume enemas (antegrade) should be considered for ACE.

ACEs in children with organic and functional defecation disorders have been shown to improve quality of life, bowel movements, and FI with long-term success reported between 69% and 91% (70,75,90–92). In patients with obstructive symptoms, who continue to have retentive FI despite optimization of the retrograde enema, ACE should be considered prior to surgical resection. This specifically pertains to patients in whom an anatomical and pathological cause has been ruled out and a redo surgery is not indicated. Of note, failure of retrograde enemas or of a structured bowel management program has not been shown to correlate with failure of antegrade enemas. In fact, Siddiqui et al (75) reported success with ACE in 68% of their patient cohort who were referred for evaluation and had failed a structured bowel management program. It is important to examine compliance, technique, and psychosocial barriers that may hamper response to treatment. Ultimately, ARM and CM should be considered in those who fail retrograde and antegrade enemas.

Recommendations for the approach of a patient with postoperative constipation:

1. The evaluation of children with postoperative constipation and FI should begin with a detailed history and physical examination.
2. Diagnostic testing, including abdominal X-ray and radiopaque marker study, can be used to differentiate between retentive and non-retentive FI.
3. Contrast enema should be performed to evaluate for mechanical causes of obstruction.
4. The original pathology should be reviewed by an experienced pathologist to ensure that there is no residual aganglionosis or transition zone pull-through. If the pathology is inadequate or not available, a re-biopsy can be done at the time of rectal exam under anesthesia to ensure normal enteric innervation of the pull-through bowel.
5. Rectal exam under anesthesia should be performed to evaluate for mechanical causes of obstruction.
6. Children with a negative anatomic and pathologic evaluation should be started on daily stimulant laxatives.
7. Children with fecal impaction should undergo fecal disimpaction prior to initiation or escalation of daily stimulant medications. The dose of daily stimulant medications should be tailored to achieve adequate colonic emptying.
8. Children who are compliant but are not responsive to oral laxatives therapy should be referred to a Neurogastroenterology & Motility Center for evaluation and management.
9. Functional assessment of the anorectum and the colon should be considered using anorectal and CM respectively.
10. Management should entail escalation of daily stimulant medication and implementation of high volume retrograde and antegrade enemas that facilitate colonic emptying

### Postoperative FI (Fig. 5)

*8-Year-old male with HD who has undergone a 2-stage Soave pull-through, with initial colostomy in the newborn period, and then colostomy pull-through at 6 months presents with FI. The anatomical evaluation was abnormal demonstrating near complete loss of dentate line.*



## History

As previously mentioned, it is important to differentiate between FI associated with stool retention and non-retentive FI as the evaluation and management between these two entities is different. Patients with non-retentive FI do not have the above-mentioned obstructive symptoms, fecal loading on physical examination, or radiographic findings. Patients may have small volume incontinence throughout the day, larger volume stool accidents post-prandially, or they may complain of worsening FI following a laxative trial. Patients may report more accidents overnight when they are not utilizing the voluntary sphincters. The perianal examination may be notable for perianal rash/excoriation, patulous or “open” sphincter, visualization of the rectal mucosa upon inspection, and asymmetrical reggae with abnormally gaping anal sphincter and poor tone and squeeze on digital rectal examination (93,94).

## Histopathology

A histological evaluation is important to exclude residual aganglionosis and transition zone pull-through. If the original pathology slides from resection margins are not available, then full thickness rectal biopsy should be performed at the time of the rectal exam under anesthesia if unable to discern with certainty on history and radiographic studies between FI associated with stool retention and non-retentive FI. Patients with transition zone pull-through or retained aganglionic segment rarely if ever will present with non-retentive FI.

## Anatomy

The anatomical evaluation should start with a rectal exam under anesthesia by an experienced surgeon to assess the integrity of the anorectum. The primary aim is to evaluate the anal sphincter complex comprised of the IAS and the external anal sphincter (EAS). A patulous or “open” anus, low intra-anal tone on digital examination, and asymmetrical ruggae indicate compromise of the anal sphincter complex likely from excessive stretching or during the rectal dissection at time of endo-rectal pull-through, previous sphincterotomy or myectomy (11,32,93). Excessive stretching of the sphincter complex and IAS myotomy at time of the procedure have been implicated in low intra-anal pressures and squeeze pressures on ARM in children with HD who have defecation problems (95). The presence of scar tissue within the IAS and EAS on anal endosonography has been associated impaired sphincter muscle function (low intra-anal pressures and squeeze pressures on ARM) (96) and with clinical symptoms of FI in children (97). The secondary aim of the rectal exam under anesthesia is to evaluate the anal canal with specific attention to the location of the anastomosis (ie, proximity to the dentate line, anoderm, skin) and the integrity of the dentate line (11,32,93,94,98). Damage to the dentate line may disrupt sensation and potentially increase risk of FI given the poor ability of the patient to discern between gas, liquid, or solid stool (93,94,98) (Fig. 6). In their pediatric cohort, Bischoff et al (94) reported that nearly 52% of patients with HD evaluated for FI had a damaged anal canal and 21% had a patulous anus who presented with refractory FI.

## Management

Postsurgical patients with HD who present with FI and are found to have compromised sphincter complex and anal canal on rectal exam under anesthesia have impaired sphincter function and sensation respectively; they have decreased potential for bowel control (11,87,93,94). Conversely, patients who have a normal sphincter complex and anal canal on rectal exam under anesthesia without evidence of mechanical/histological abnormalities and without evidence of stool retention are expected to have the

potential for bowel control. The goals of treatment are predictable bowel movements, social continence, and independence (63). Treatments range from diet, behavioral modification, and antimitility agents that modify stool consistency and transit to small volume retrograde and antegrade enemas that facilitate colonic emptying (11,63,76,77,85,87,93).

Constipating diet and soluble fiber (pectin, psyllium, gum) can be used to increase stool consistency and bulk. In a randomized placebo-controlled study, Bliss et al (99) reported that the use of fiber supplementation effectively reduced FI by half. It is important to ensure that the soluble fiber formulations do not contain sugar alcohol additives as these can cause an osmotic laxative effect. Coarse or large particle insoluble fiber can bulk the stool but should be avoided as it can make the stools looser and worsen FI (100). Patients should be encouraged to have timed toilet sitting, specifically after each meal and to try to limit the amount of snacking in between meals, with the aim of decreasing the gastrocolonic reflex and colonic contractions post-prandially to a minimum throughout the day. If there is lack of clinical improvement, referral to a Neurogastroenterology & Motility Center should be considered to assess anorectal and colonic function.

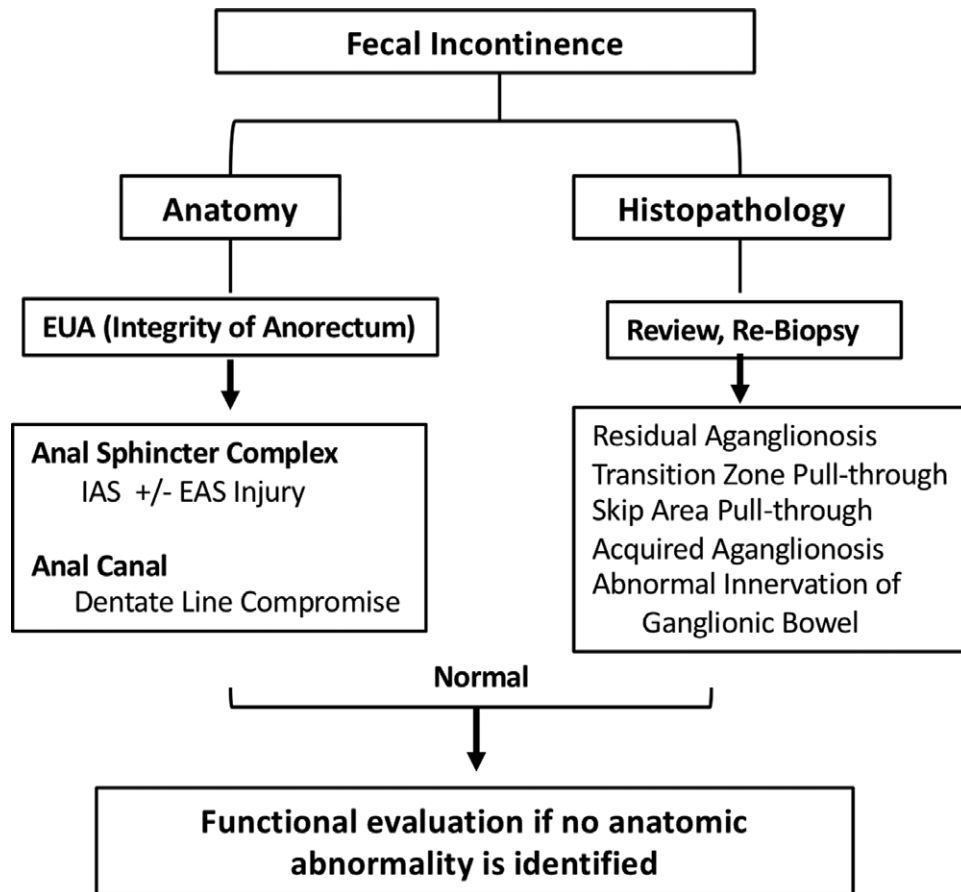
## Role of a Neurogastroenterology & Motility Expert

### Evaluation

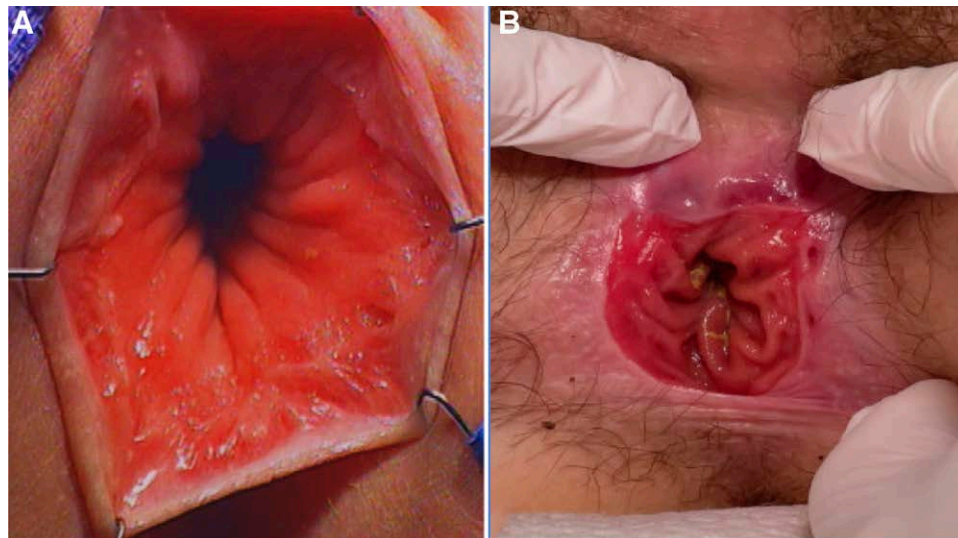
Abnormal anorectal and colonic function should be suspected in patients with non-retentive FI who have a normal anal canal and preserved sphincter complex on rectal exam under anesthesia and yet continue to have FI despite optimization of medical therapy. ARM in patients with non-retentive FI helps to investigate the physiologic integrity of the anal sphincter complex, IAS, and EAS. This evaluation is important because the intra-anal pressures at rest are comprised of the IAS (70%–80%), the EAS (15%), and the hemorrhoidal cushion (5%) (101,102). Low intra-anal pressures at rest during manometry with the ability to generate normal squeeze pressures indicate compromise of the IAS with preserved EAS function. However, low intra-anal pressures in conjunction with an abnormal squeeze indicate compromise of the IAS and the EAS (Fig. 7). Low intra-anal pressures at rest have been described in postsurgical patients with HD who present with FI (65,95,103). Conversely, there are studies that have not found a correlation between intra-anal pressures and FI (96,104). Pediatric studies are limited by heterogeneous patient populations, variable methodologies, and definitions for continence. Moreover, these studies highlight that FI in postsurgical patients with HD may be multifactorial including aberrations in anorectal and colonic function (65,103,104).

Abnormal colonic function should be suspected in patients with continued FI who (a) have normal anorectal function and are not responsive to medical therapy or (b) have abnormal anorectal function (with or without compromise of the anal sphincter complex or dentate line) and are not responsive to medical therapy. In patients with FI abnormal CM findings include migration of HAPCs through the neorectum to the anal sphincter (51,105) and increased frequency of HAPCs during fasting and in the post-prandial state indicative of colonic hyperactivity (105,106) (Fig. 6C). It is important to identify these patterns on CM since management does not involve the use of laxatives and in fact the use of laxatives may worsen FI. Treatments aim to reduce the frequency and amplitude of HAPCs (anticholinergics and antidiarrheal).

In health, HAPCs originate in the proximal colon, propagate aborally, and terminate at the level of sigmoid colon without traversing the rectum. In patients with HD, resection of



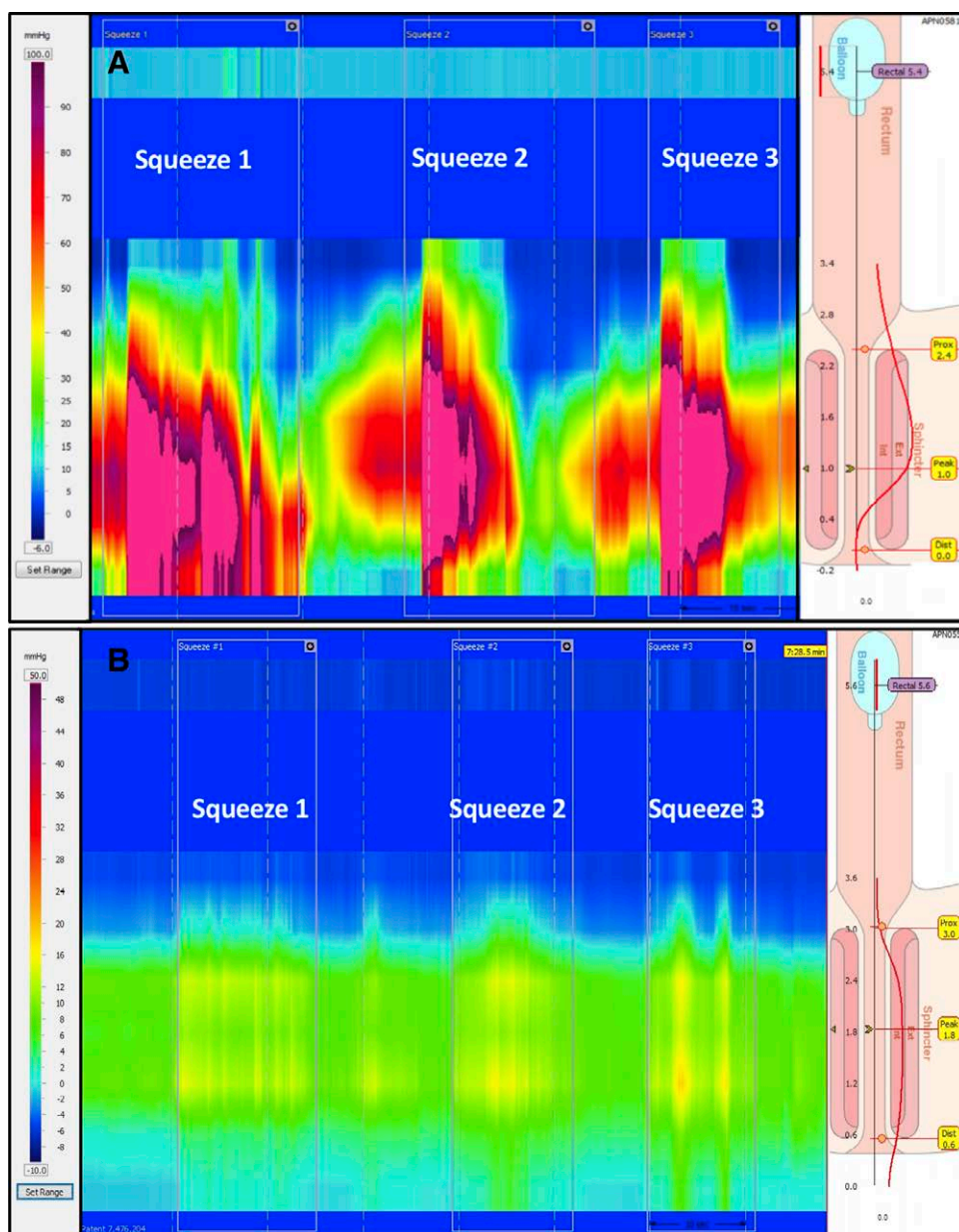
**FIGURE 5.** Diagnostic approach to a postsurgical patient with Hirschsprung disease who presents with fecal incontinence. EAS = external anal sphincter; EUA = rectal exam under anesthesia; IAS = internal anal sphincter.



**FIGURE 6.** Examination of the anus. (A) Normal dentate line. (B) Complete loss of dentate line resulting from a pull-through started too low.

the aganglionic segment and pull through of ganglionic bowel removes the sigmoid “break” and the rectum which serves a reservoir function, and thus predisposes the HAPCs to traverse the neo-rectum and reach the anus resulting in incontinence.

As mentioned earlier, Di Lorenzo et al (51) identified 4 colonic manometric patterns in their pediatric cohort of postsurgical HD patients who presented with defecation problems. One of the patterns describes patients who had migration of HAPCs though



**FIGURE 7.** High resolution anorectal manometry. (A) Normal intra-anal pressures and squeeze. (B) Low intra-anal pressures and poor squeeze effort.

the neorectum to the anal sphincter and had associated FI. These patients received anticholinergics and loperamide to decrease the HAPCs (51). Kaul et al (105) reported increased number of HAPCs per min during fasting and in the post-prandial period when they compared postsurgical HD with FI who had HAPCs on CM to children with chronic constipation with normal CM. Similarly, to Di Lorenzo et al, they observed that in that subgroup the HAPCs originated in the right colon and migrated to the anus (105). The authors hypothesized that the loss of inhibitory neuronal mechanisms after the pull through and subsequent loss of rectal antagonizing forces could allow colonic contractions to travel through the neorectum and to the anus resulting in FI. Similar findings were observed by Jacobs et al, who reported significantly increased number of HAPCs per hour during fasting

and the postprandial period in the HD with FI cohort when compared to the HD with constipation cohort (106).

Additional studies are needed to further clarify the utility of CM in postsurgical HD patients with FI that is not secondary to stool retention. These patients may have a normal or a compromised anorectum (anal sphincter complex, anal canal) in the setting of normal or abnormal anorectal function. CM should be considered in those who continue to have FI despite appropriate therapy.

#### Management

Anti-motility agents, such as loperamide (opioid receptor agonist), cholestyramine (bile acid sequestrant), and hyoscyamine (anticholinergic) can be used to modify colonic transit and

are useful in such cases (Table 1). Loperamide has been shown to increase IAS tone and to decrease small bowel and colonic transit (107–110). A judicious dose escalation and monitoring for anticholinergic side effects should be considered. Cholestyramine binds to bile acid and forms insoluble complexes that decrease colonic water content and transit (76,85,107,111).

Patients who are not continent with the above-mentioned interventions require the addition of low volume retrograde enemas to ensure distal colonic emptying in conjunction with thickening stool and decreasing transit (11,63,76,77,85,87,93). Stimulant suppositories and low volume over the counter enemas such as bisacodyl, glycerin, and docusate may not be possible in patients who have significant compromise of their sphincter complex as they may not be able to hold the enema to ensure maximum effect (Table 1). These patients benefit from low volume enemas using continence enema catheter (#24/26 French non-latex urinary Foley with distal balloon) or a trans-anal irrigation system. Low volume retrograde enemas may need to be administered twice a day to ensure adequate emptying as other methods ensure daytime constipation. Ultimately, if patients are not able to be independent via rectal route and/or prefer a different route of administration, then an ACE should be considered. Laxatives and/or surgical resection in this group of patients is not warranted. Rarely patients who have failed the above modalities may be considered for a permanent stoma in order to achieve continence and improve quality of life. In cases of iatrogenic sphincter injury, a new option to perform sphincter reconstruction has been recently published (112).

Recommendations for a patient with postoperative FI:

1. The evaluation of children with postoperative FI should begin with a detailed history and physical examination.
2. Diagnostic testing including abdominal X-ray and radiopaque marker study can be used to differentiate between retentive and non-retentive FI.
3. Rectal exam under anesthesia should be performed to assess the integrity of the anorectum, specifically the anal sphincter complex and the dentate line.
4. Initial management should involve constipating diet and soluble fiber to increase stool consistency and bulk. Children should be encouraged to have timed toilet seating after each meal and to limit snacking between meals.
5. Children who are compliant but are not responsive to the changes in diet and behavior should be referred to a Neurogastroenterology & Motility Center for evaluation and management.
6. Functional assessment of the anorectum and the colon should be considered using anorectal and CM respectively.
7. Management should entail initiation of antimotility agents that modify stool consistency and transit and implementation of low volume retrograde and antegrade enemas that facilitate colonic emptying.

## CONCLUSIONS

Postoperative defecation problems in children with HD are common and negatively impact a patient's quality of life and result in significant morbidity. A methodical and timely evaluation is necessary to exclude anatomic and pathologic causes of FI and obstructive symptoms. Then, a functional assessment of the anorectum and colon can be pursued to identify aberrations in neuromuscular function. The goals of management are to facilitate colonic emptying and ensure a state of homeostasis thereby decreasing obstructive symptoms and achieving fecal continence.

## REFERENCES

1. Heuckeroth RO. Hirschsprung disease – integrating basic science and clinical medicine to improve outcomes. *Nat Rev Gastroenterol Hepatol* 2018;15:152–67.
2. Langer JC. Hirschsprung disease. *Curr Opin Pediatr* 2013;25:368–74.
3. Nurko S. Motility disorders in children. *Pediatr Clin North Am* 2017;64:593–612.
4. Demehri FR, Halaweish IF, Coran AG, Teitelbaum DH. Hirschsprung-associated enterocolitis: pathogenesis, treatment and prevention. *Pediatr Surg Int* 2013;29:873–81.
5. Jiao CL, Chen XY, Feng JX. Novel Insights into the pathogenesis of Hirschsprung's-associated enterocolitis. *Chin Med J (Engl)* 2016;129:1491–7.
6. Langer JC, Rollins MD, Levitt M, et al. Guidelines for the management of postoperative obstructive symptoms in children with Hirschsprung disease. *Pediatr Surg Int* 2017;33:523–6.
7. Gosain A. Established and emerging concepts in Hirschsprung's-associated enterocolitis. *Pediatr Surg Int* 2016;32:313–20.
8. Gosain A, Frykman PK, Cowles RA, et al. Guidelines for the diagnosis and management of Hirschsprung-associated enterocolitis. *Pediatr Surg Int* 2017;33:517–21.
9. Collins L, Collis B, Trajanovska M, et al. Quality of life outcomes in children with Hirschsprung disease. *J Pediatr Surg* 2017;52:2006–10.
10. Dai Y, Deng Y, Lin Y, Ouyang R, Li L. Long-term outcomes and quality of life of patients with Hirschsprung disease: a systematic review and meta-analysis. *BMC Gastroenterol* 2020;20:67.
11. Saadai P, Trappey AF, Goldstein AM, et al. Guidelines for the management of postoperative soiling in children with Hirschsprung disease. *Pediatr Surg Int* 2019;35:829–34.
12. Ahmad H, Levitt MA, Yacob D, et al. Evaluation and management of persistent problems after surgery for Hirschsprung disease in a child. *Curr Gastroenterol Rep* 2021;23:18.
13. Zimmer J, Tomuschat C, Puri P. Long-term results of transanal pull-through for Hirschsprung's disease: a meta-analysis. *Pediatr Surg Int* 2016;32:743–9.
14. Engum SA, Grosfeld JL. Long-term results of treatment of Hirschsprung's disease. *Semin Pediatr Surg* 2004;13:273–85.
15. Menezes M, Corbally M, Puri P. Long-term results of bowel function after treatment for Hirschsprung's disease: a 29-year review. *Pediatr Surg Int* 2006;22:987–90.
16. Meinds RJ, van der Steeg AFW, Sloots CEJ, et al. Long-term functional outcomes and quality of life in patients with Hirschsprung's disease. *Br J Surg* 2019;106:499–507.
17. Calkins CM. Hirschsprung disease beyond infancy. *Clin Colon Rectal Surg* 2018;31:51–60.
18. Wester T, Granstrom AL. Hirschsprung disease—bowel function beyond childhood. *Semin Pediatr Surg* 2017;26:322–7.
19. Thakkar HS, Bassett C, Hsu A, et al. Functional outcomes in Hirschsprung disease: a single institution's 12-year experience. *J Pediatr Surg* 2017;52:277–80.
20. Smith C, Ambartsumyan L, Kapur RP. Surgery, surgical pathology, and postoperative management of patients with Hirschsprung disease. *Pediatr Dev Pathol* 2020;23:23–39.
21. Vilanova-Sanchez A, Halleran DR, Reck-Burneo CA, et al. A descriptive model for a multidisciplinary unit for colorectal and pelvic malformations. *J Pediatr Surg* 2019;54:479–85.
22. Kastenberg ZJ, Wall N, Malhotra N, et al. The effect of multidisciplinary colorectal center development on short-term hospital readmissions for patients with anorectal malformations or Hirschsprung disease. *J Pediatr Surg* 2020;55:541–4.
23. Rodriguez L, Sood M, Di Lorenzo C, Saps M. An ANMS-NASPGHAN consensus document on anorectal and colonic manometry in children. *Neurogastroenterol Motil* 2017;29. doi: 10.1111/nmo.12944.
24. Camilleri M, Bharucha AE, di Lorenzo C, et al. American Neurogastroenterology and Motility Society consensus statement on intraluminal measurement of gastrointestinal and colonic motility in clinical practice. *Neurogastroenterol Motil* 2008;20:1269–82.
25. Di Lorenzo C, Flores AF, Reddy SN, Hyman PE. Use of colonic manometry to differentiate causes of intractable constipation in children. *J Pediatr* 1992;120:690–5.

26. Pensabene L, Youssef NN, Griffiths JM, Di Lorenzo C. Colonic manometry in children with defecatory disorders. role in diagnosis and management. *Am J Gastroenterol* 2003;98:1052–7.
27. Dasgupta R, Langer JC. Evaluation and management of persistent problems after surgery for Hirschsprung disease in a child. *J Pediatr Gastroenterol Nutr* 2008;46:13–9.
28. Kapur RP, Smith C, Ambartsumyan L. Postoperative pullthrough obstruction in Hirschsprung disease: etiologies and diagnosis. *Pediatr Dev Pathol* 2020;23:40–59.
29. Friedmacher F, Puri P. Residual aganglionosis after pull-through operation for Hirschsprung's disease: a systematic review and meta-analysis. *Pediatr Surg Int* 2011;27:1053–7.
30. Coe A, Collins MH, Lawal T, Loudon E, Levitt MA, Pena A. Reoperation for Hirschsprung disease: pathology of the resected problematic distal pull-through. *Pediatr Dev Pathol* 2012;15:30–8.
31. Dickie BH, Webb KM, Eradi B, Levitt MA. The problematic Soave cuff in Hirschsprung disease: manifestations and treatment. *J Pediatr Surg* 2014;49:77–80; discussion 80.
32. Levitt MA, Dickie B, Pena A. Evaluation and treatment of the patient with Hirschsprung disease who is not doing well after a pull-through procedure. *Semin Pediatr Surg* 2010;19:146–53.
33. Ahmad H, Halleran DR, Quintanilla R, Gasior AC, Wood RJ, Levitt MA. A Hirschsprung pull-through, "with a Twist". *European J Pediatr Surg Rep* 2020;8:e95–8.
34. Garrett KM, Levitt MA, Pena A, Kraus SJ. Contrast enema findings in patients presenting with poor functional outcome after primary repair for Hirschsprung disease. *Pediatr Radiol* 2012;42:1099–106.
35. Chatoorgoon K, Pena A, Lawal TA, Levitt M. The problematic Duhamel pouch in Hirschsprung's disease: manifestations and treatment. *Eur J Pediatr Surg* 2011;21:366–9.
36. Le-Nguyen A, Righini-Grunder F, Piché N, Faure C, Aspirot A. Factors influencing the incidence of Hirschsprung associated enterocolitis (HAEC). *J Pediatr Surg* 2019;54:959–63.
37. Chung PHY, Yu MON, Wong KKY, Tam PKH. Risk factors for the development of post-operative enterocolitis in short segment Hirschsprung's disease. *Pediatr Surg Int* 2019;35:187–91.
38. Kon R, Ikarashi N, Nagoya C, et al. Rheinanthrone, a metabolite of sennoside A, triggers macrophage activation to decrease aquaporin-3 expression in the colon, causing the laxative effect of rhubarb extract. *J Ethnopharmacol* 2014;152:190–200.
39. Manabe N, Cremonini F, Camilleri M, Sandborn WJ, Burton DD. Effects of bisacodyl on ascending colon emptying and overall colonic transit in healthy volunteers. *Aliment Pharmacol Ther* 2009;30:930–6.
40. Kienzle-Horn S, Vix JM, Schuijt C, Peil H, Jordan CC, Kamm MA. Efficacy and safety of bisacodyl in the acute treatment of constipation: a double-blind, randomized, placebo-controlled study. *Aliment Pharmacol Ther* 2006;23:1479–88.
41. Santos-Jasso KA, Arredondo-Garcia JL, Maza-Vallejos J, Lezama-Del Valle P. Effectiveness of Senna vs polyethylene glycol as laxative therapy in children with constipation related to anorectal malformation. *J Pediatr Surg* 2017;52:84–8.
42. Vilanova-Sanchez A, Gasior AC, Toocheck N, et al. Are Senna based laxatives safe when used as long term treatment for constipation in children? *J Pediatr Surg* 2018;53:722–7.
43. Kamm MA, Mueller-Lissner S, Wald A, Richter E, Swallow R, Gessner U. Oral bisacodyl is effective and well-tolerated in patients with chronic constipation. *Clin Gastroenterol Hepatol* 2011;9:577–83.
44. Bonilla S, Nurko S, Rodriguez L. Long-term use of bisacodyl in pediatric functional constipation refractory to conventional therapy. *J Pediatr Gastroenterol Nutr* 2020;71:288–91.
45. van Kuyk EM, Brugman-Boezeman AT, Wissink-Essink M, Oerlemans HM, Severijnen RS, Bleijenberg G. Defecation problems in children with Hirschsprung's disease: a prospective controlled study of a multidisciplinary behavioural treatment. *Acta Paediatr* 2001;90:1153–9.
46. van Kuyk EM, Brugman-Boezeman AT, Wissink-Essink M, Severijnen RS, Festen C, Bleijenberg G. Defecation problems in children with Hirschsprung's disease: a biopsychosocial approach. *Pediatr Surg Int* 2000;16:312–6.
47. Meinds RJ, Eggink MC, Heineman E, Broens PM. Dyssynergic defecation may play an important role in postoperative Hirschsprung's disease patients with severe persistent constipation: analysis of a case series. *J Pediatr Surg* 2014;49:1488–92.
48. Chumpitazi BP, Fishman SJ, Nurko S. Long-term clinical outcome after botulinum toxin injection in children with nonrelaxing internal anal sphincter. *Am J Gastroenterol* 2009;104:976–83.
49. Chumpitazi BP, Nurko S. Defecation disorders in children after surgery for Hirschsprung disease. *J Pediatr Gastroenterol Nutr* 2011;53:75–9.
50. Soh HJ, Nataraja RM, Pacilli M. Prevention and management of recurrent postoperative Hirschsprung's disease obstructive symptoms and enterocolitis: systematic review and meta-analysis. *J Pediatr Surg* 2018;53:2423–9.
51. Di Lorenzo C, Solzi GF, Flores AF, Schwankovsky L, Hyman PE. Colonic motility after surgery for Hirschsprung's disease. *Am J Gastroenterol* 2000;95:1759–64.
52. Wester T, Granstrom AL. Botulinum toxin is efficient to treat obstructive symptoms in children with Hirschsprung disease. *Pediatr Surg Int* 2015;31:255–9.
53. Patrus B, Nasr A, Langer JC, Gerstle JT. Intrasphincteric botulinum toxin decreases the rate of hospitalization for postoperative obstructive symptoms in children with Hirschsprung disease. *J Pediatr Surg* 2011;46:184–7.
54. Louis-Borrione C, Faure A, Garnier S, et al. Neurostimulation-guided anal intrasphincteric botulinum toxin injection in children with hirschsprung disease. *J Pediatr Gastroenterol Nutr* 2019;68:527–32.
55. Roorda D, Abeln ZA, Oosterlaan J, van Heurn LW, Derikx JP. Botulinum toxin injections after surgery for Hirschsprung disease: systematic review and meta-analysis. *World J Gastroenterol* 2019;25:3268–80.
56. Youn JK, Han JW, Oh C, Kim SY, Jung SE, Kim HY. Botulinum toxin injection for internal anal sphincter achalasia after pull-through surgery in Hirschsprung disease. *Medicine (Baltim)* 2019;98:e17855e17855.
57. Wildhaber BE, Pakarinen M, Rintala RJ, Coran AG, Teitelbaum DH. Posterior myotomy/myectomy for persistent stooling problems in Hirschsprung's disease. *J Pediatr Surg* 2004;39:920–6; discussion 920.
58. Heikkinen M, Lindahl H, Rintala RJ. Long-term outcome after internal sphincter myectomy for internal sphincter achalasia. *Pediatr Surg Int* 2005;21:84–7.
59. de Lorijn F, van Wijk MP, Reitsma JB, van Ginkel R, Taminiau JAJM, Benninga MA. Prognosis of constipation: clinical factors and colonic transit time. *Arch Dis Child* 2004;89:723–7.
60. Gutierrez C, Marco A, Nogales A, Tebar R. Total and segmental colonic transit time and anorectal manometry in children with chronic idiopathic constipation. *J Pediatr Gastroenterol Nutr* 2002;35:31–8.
61. Benninga MA, Voskuijl WP, Akkerhuis GW, Taminiau JA, Buller HA. Colonic transit times and behaviour profiles in children with defecation disorders. *Arch Dis Child* 2004;89:13–6.
62. Kim ER, Rhee PL. How to interpret a functional or motility test – colon transit study. *J Neurogastroenterol Motil* 2012;18:94–9.
63. Ambartsumyan L, Nurko S. Review of organic causes of fecal incontinence in children: evaluation and treatment. *Expert Rev Gastroenterol Hepatol* 2013;7:657–67.
64. Cogley K, Echevarria A, Correa C, De la Torre-Mondragon L. Contact burn with blister formation in children treated with sennosides. *Pediatr Dermatol* 2017;34:e85–8.
65. Tran VQ, Mahler T, Bontems P, et al. Interest of anorectal manometry during long-term follow-up of patients operated on for Hirschsprung's disease. *J Neurogastroenterol Motil* 2018;24:70–8.
66. Martin MJ, Steele SR, Noel JM, Weichmann D, Azarow KS. Total colonic manometry as a guide for surgical management of functional colonic obstruction: preliminary results. *J Pediatr Surg* 2001;36:1757–63.
67. Villarreal J, Sood M, Zangen T, et al. Colonic diversion for intractable constipation in children: colonic manometry helps guide clinical decisions. *J Pediatr Gastroenterol Nutr* 2001;33:588–91.
68. Christison-Lagay ER, Rodriguez L, Kurtz M, St Pierre K, Doody DP, Goldstein AM. Antegrade colonic enemas and intestinal diversion are highly effective in the management of children with intractable constipation. *J Pediatr Surg* 2010;45:213–9; discussion 219.
69. Evans-Barns HME, Swannjo J, Trajanovska M, et al. Post-operative colonic manometry in children with Hirschsprung disease: a systematic review. *Neurogastroenterol Motil* 2021;33:e14201.
70. Mugie SM, Machado RS, Mousa HM, et al. Ten-year experience using antegrade enemas in children. *J Pediatr* 2012;161:700–4.
71. van den Berg MM, Hogan M, Caniano DA, Di Lorenzo C, Benninga MA, Mousa HM. Colonic manometry as predictor of cecostomy success

- in children with defecation disorders. *J Pediatr Surg* 2006;41:730–6; discussion 730.
72. Aspirot A, Fernandez S, Di Lorenzo C, Skaggs B, Mousa H. Antegrade enemas for defecation disorders: do they improve the colonic motility? *J Pediatr Surg* 2009;44:1575–80.
  73. Rodriguez L, Nurko S, Flores A. Factors associated with successful decrease and discontinuation of antegrade continence enemas (ACE) in children with defecation disorders: a study evaluating the effect of ACE on colon motility. *Neurogastroenterol Motil* 2013;25:140–e81.
  74. Mosiello G, Marshall D, Rolle U, et al. Consensus review of best practice of transanal irrigation in children. *J Pediatr Gastroenterol Nutr* 2017;64:343–52.
  75. Siddiqui AA, Fishman SJ, Bauer SB, Nurko S. Long-term follow-up of patients after antegrade continence enema procedure. *J Pediatr Gastroenterol Nutr* 2011;52:574–80.
  76. Bischoff A, Levitt MA, Bauer C, Jackson L, Holder M, Pena A. Treatment of fecal incontinence with a comprehensive bowel management program. *J Pediatr Surg* 2009;44:1278–83; discussion 1283.
  77. Levitt MA, Martin CA, Olesovich M, Bauer CL, Jackson LE, Pena A. Hirschsprung disease and fecal incontinence: diagnostic and management strategies. *J Pediatr Surg* 2009;44:271–7; discussion 277.
  78. Bani-Hani AH, Cain MP, King S, Rink RC. Tap water irrigation and additives to optimize success with the Malone antegrade continence enema: the Indiana University algorithm. *J Urol* 2008;180(4 Suppl):1757–60; discussion 1760.
  79. Sheibani S, Gerson LB. Chemical colitis. *J Clin Gastroenterol* 2008;42:115–21.
  80. Ladenhauf HN, Stundner O, Spreitzhofer F, Deluggi S. Severe hyperphosphatemia after administration of sodium-phosphate containing laxatives in children: case series and systematic review of literature. *Pediatr Surg Int* 2012;28:805–14.
  81. Mendoza J, Legido J, Rubio S, Gisbert JP. Systematic review: the adverse effects of sodium phosphate enema. *Aliment Pharmacol Ther* 2007;26:9–20.
  82. Chertow GM, Brady HR. Hyponatraemia from tap-water enema. *Lancet* 1994;344:748748.
  83. Meier DE, Foster ME, Guzzetta PC, Coln D. Antegrade continent enema management of chronic fecal incontinence in children. *J Pediatr Surg* 1998;33:1149–51; discussion 1151.
  84. Pena A, Guardino K, Tovilla JM, Levitt MA, Rodriguez G, Torres R. Bowel management for fecal incontinence in patients with anorectal malformations. *J Pediatr Surg* 1998;33:133–7.
  85. Bischoff A, Levitt MA, Pena A. Bowel management for the treatment of pediatric fecal incontinence. *Pediatr Surg Int* 2009;25:1027–42.
  86. Bischoff A, Brisighelli G, Dickie B, Frischer J, Levitt MA, Pena A. Idiopathic constipation: A challenging but manageable problem. *J Pediatr Surg* 2018;53:1742–7.
  87. Levitt M, Pena A. Update on pediatric faecal incontinence. *Eur J Pediatr Surg* 2009;19:1–9.
  88. Kilpatrick JA, Zobell S, Leeflang EJ, Cao D, Mammen L, Rollins MD. Intermediate and long-term outcomes of a bowel management program for children with severe constipation or fecal incontinence. *J Pediatr Surg* 2020;55:545–8.
  89. Gabr AA, Gad MA, Shalaby A. Quality of life in children with pseudo-incontinence after implementing a bowel management program in Egypt. *J Pediatr Surg* 2020;55:261–4.
  90. Hoekstra LT, Kuijper CF, Bakx R, Heij HA, Aronson DC, Benninga MA. The Malone antegrade continence enema procedure: the Amsterdam experience. *J Pediatr Surg* 2011;46:1603–8.
  91. Har AF, Rescorla FJ, Croffie JM. Quality of life in pediatric patients with unremitting constipation pre and post Malone Antegrade Continence Enema (MACE) procedure. *J Pediatr Surg* 2013;48:1733–7.
  92. Li C, Shanahan S, Livingston MH, Walton JM. Malone appendicostomy versus cecostomy tube insertion for children with intractable constipation: a systematic review and meta-analysis. *J Pediatr Surg* 2018;53:885–91.
  93. Levitt MA, Dickie B, Pena A. The Hirschsprungs patient who is soiling after what was considered a “successful” pull-through. *Semin Pediatr Surg* 2012;21:344–53.
  94. Bischoff A, Frischer J, Knod JL, et al. Damaged anal canal as a cause of fecal incontinence after surgical repair for Hirschsprung disease – a preventable and under-reported complication. *J Pediatr Surg* 2017;52:549–53.
  95. Heikkinen M, Rintala R, Luukkonen P. Long-term anal sphincter performance after surgery for Hirschsprung’s disease. *J Pediatr Surg* 1997;32:1443–6.
  96. Bjornland K, Diseth TH, Emblem R. Long-term functional, manometric, and endosonographic evaluation of patients operated upon with the Duhamel technique. *Pediatr Surg Int* 1998;13:24–8.
  97. Stensrud KJ, Emblem R, Bjornland K. Anal endosonography and bowel function in patients undergoing different types of endorectal pull-through procedures for Hirschsprung disease. *J Pediatr Surg* 2015;50:1341–6.
  98. De la Torre L, Cogley K, Santos K, Morales O, Calisto J. The anal canal is the fine line between “fecal incontinence and colitis” after a pull-through for Hirschsprung disease. *J Pediatr Surg* 2017;52:2011–7.
  99. Bliss DZ, Jung HJ, Savik K, et al. Supplementation with dietary fiber improves fecal incontinence. *Nurs Res* 2001;50:203–13.
  100. McRorie JW, Jr, McKeown NM. Understanding the physics of functional fibers in the gastrointestinal tract: an evidence-based approach to resolving enduring misconceptions about insoluble and soluble fiber. *J Acad Nutr Diet* 2017;117:251–64.
  101. Duthie HL, Watts JM. Contribution of the external anal sphincter to the pressure zone in the Anal Canal. *Gut* 1965;6:64–8.
  102. Raizada V, Mittal RK. Pelvic floor anatomy and applied physiology. *Gastroenterol Clin North Am* 2008;37:493–509, vii.
  103. Keshtgar AS, Ward HC, Clayden GS, de Sousa NM. Investigations for incontinence and constipation after surgery for Hirschsprung’s disease in children. *Pediatr Surg Int* 2003;19:4–8.
  104. Catto-Smith AG, Trajanovska M, Taylor RG. Long-term continence after surgery for Hirschsprung’s disease. *J Gastroenterol Hepatol* 2007;22:2273–82.
  105. Kaul A, Garza JM, Connor FL, et al. Colonic hyperactivity results in frequent fecal soiling in a subset of children after surgery for Hirschsprung disease. *J Pediatr Gastroenterol Nutr* 2011;52:433–6.
  106. Jacobs C, Wolfson S, Di Lorenzo C, Cocjin J, Monagas J, Hyman P. Effect of colon transection on spontaneous and meal-induced high-amplitude—propagating contractions in children. *J Pediatr Gastroenterol Nutr* 2015;60:60–4.
  107. Halverson AL. Nonoperative management of fecal incontinence. *Clin Colon Rectal Surg* 2005;18:17–21.
  108. Ehrenpreis ED, Chang D, Eichenwald E. Pharmacotherapy for fecal incontinence: a review. *Dis Colon Rectum* 2007;50:641–9.
  109. Pensabene L, Nurko S. Management of fecal incontinence in children without functional fecal retention. *Curr Treat Options Gastroenterol* 2004;7:381–90.
  110. Read M, Read NW, Barber DC, Duthie HL. Effects of loperamide on anal sphincter function in patients complaining of chronic diarrhea with fecal incontinence and urgency. *Dig Dis Sci* 1982;27:807–14.
  111. Remes-Troche JM, Ozturk R, Philips C, Stessman M, Rao SS. Cholestyramine—a useful adjunct for the treatment of patients with fecal incontinence. *Int J Colorectal Dis* 2008;23:189–94.
  112. Krois W, Reck CA, Darbari A, Badillo A, Levitt MA. A technique to reconstruct the anal sphincters following iatrogenic stretching related to a pull-through for Hirschsprung disease. *J Pediatr Surg* 2021;56:1242–6.